

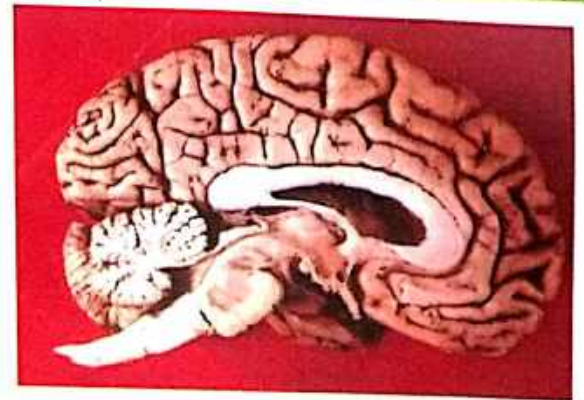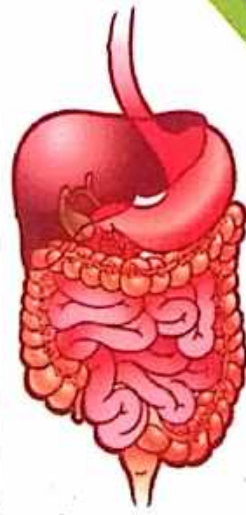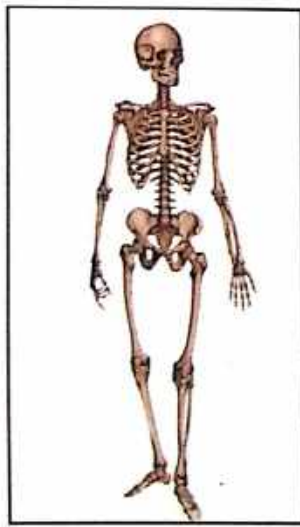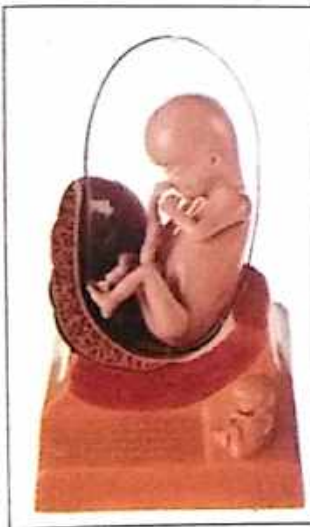# ANATOMY PRACTICAL BOOK

For  
**BAMS** Students

**Dr. Sushil Dwivedi**

**2<sup>nd</sup> Edition**

**रचना शारीर**  
प्रायोगिक पुस्तक



ASHWARY PUBLICATION

BHILAI

# INDEX

## **UNIT - 1 : EMBRYOLOGY**

**1-19**

|   |    |
|---|----|
| DEFINITION OF EMBRYO                        | 02 |
| STRUCTURE OF MATURE SPERMATOZOON            | 02 |
| SPERMATOGENESIS                             | 02 |
| शुक्र के लक्षण -                            | 02 |
| शुक्र दोष :                                 | 02 |
| आर्तव, आर्तव के लक्षण, दुष्ट आर्तव के लक्षण | 04 |
| STRUCTURE OF MATURE OOCYTE                  | 04 |
| OÖGENESIS                                   | 04 |
| FERTILIZATION                               | 06 |
| CLEAVAGE                                    | 06 |
| FORMATION OF GERMINAL LAYERS                | 08 |
| FORMATION OF EMBRYO                         | 10 |
| DEVELOPMENT OF EMBRYO                       | 12 |
| IMPLANTATION                                | 12 |
| FORMATION OF PLACENTA                       | 14 |
| UMBILICAL CORD                              | 16 |
| ORGAN FORMED BY GERMINAL LAYERS             | 16 |
| FOETAL CIRCULATION                          | 18 |

## **UNIT - 2 : OSTEOLOGY**

**20-129**

|                              |    |
|------------------------------|----|
| <b>UPPER LIMB - CLAVICLE</b> | 21 |
| SCAPULA                      | 24 |
| HUMERUS                      | 28 |
| RADIUS                       | 32 |
| ULNA                         | 36 |
| CARPALS                      | 40 |
| METACARPALS                  | 45 |
| PHALANGES                    | 49 |
| <b>LOWER LIMB- HIP BONE</b>  | 52 |
| FEMUR                        | 60 |
| PATELLA                      | 64 |
| TIBIA                        | 66 |
| FIBULA                       | 70 |
| TARSALS                      | 74 |
| METATARSALS                  | 80 |
| PHALANGES                    | 81 |

# EMBRYOLOGY

(ବୀଜ ଶାସ୍ତ୍ର)

# EMBRYOLOGY

## Definition of Embryo

### ● ACCORDING TO AYURVEDA

- शुक्रशोणितं गर्भाशयस्थमात्मप्रकृतिविकार सम्मूर्च्छितं 'गर्भ' इत्युच्यते । (सु.शा. 5/3)  
अत्र गर्भशब्देन मनः संयोगाच्चेतनेनाधिष्ठितानां महाभूतानां विकार विशेष उच्यते । (इन्दु)  
शुक्रशोणित जीवसंयोगे तु खलु कुक्षिगते गर्भ संज्ञा भवति । (च.शा. 4/5)

### ● ACCORDING TO MODERN

During the first two Months we call the developing individual as embryo, After that we call it a "Foetus"

- ★ शुक्रकेलक्षण - स्फटिकाभं द्रवं स्निग्धं मधुरं मधुगंधि च ।  
शुक्रमिच्छन्ति केचित्तु तैल क्षौद्रनिभं तथा । (सु.शा. 2/11)

## Structure of Mature Spermatozoon

Length - 60 $\mu$ m

- ★ Spermatozoon has 4 parts
- (i) Head
  - (ii) Neck
  - (iii) Middle Piece
  - (iv) Principle Piece (tail)

- ★ Head Shape = Piriform  
Length = 3 - 5  $\mu$ m

Derived from the nucleus & consist 23 highly condensed chromosomes. Covered by cup like structure called "Acrosome", acrosome consist of enzyme.

- ★ Neck Narrow & Contains
- Funnel shaped basal body or "connecting" piece
  - Spherical centriole

- ★ Axial Filament Middle piece joint the tail.
- Passes through ring like structure called 'Annulus'.
  - Surrounded by spiral sheath made of Mitochondria.
  - Actually composed by several fibrils.
  - A central pair surrounded by 9 other fibril pairs.

- ★ Stages :-

### ● Spermatogenesis

Proliferation

↓  
Growth

↓  
Maturation

↓  
Transformation (Metamorphosis)

शुक्र दोष : फेनिलं तनु रूक्षं च विवर्णं पूति पिच्छिलम् ।  
अन्यधातूपसंसृष्टमवसादि तथाष्टमम् ॥

(च.चि. 30/139)

★ आर्तव के लक्षण :

1. शशासृक प्रतिमं यत्तु यद्वा लाक्षारसोपमम् ।  
तदार्त्तवं प्रशंसन्ति यद्वासो न विरञ्जयेत् ।

(सु. शा. 2/17)

2. गुंजाफलसवर्णं च पद्माऽलक्तक सन्निभम् ।  
इन्द्रगोपकसंकाशमार्त्तवं शुद्धमादिशेत् ।

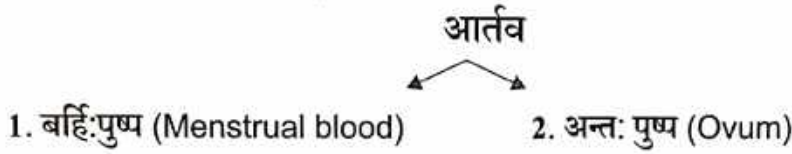
(च. चि. 30/230)

★ दुष्ट आर्तव के लक्षण -

आर्तवमपि त्रिभिर्दोषैः शोणितचतुर्थैः पृथग्द्वन्द्वैः समस्तैश्चोपसृष्टमबीजं भवति, तदपि दोषवर्णविदनाऽऽदिभिर्विज्ञेयम् ।

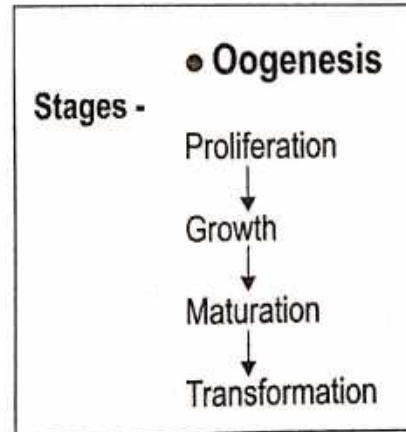
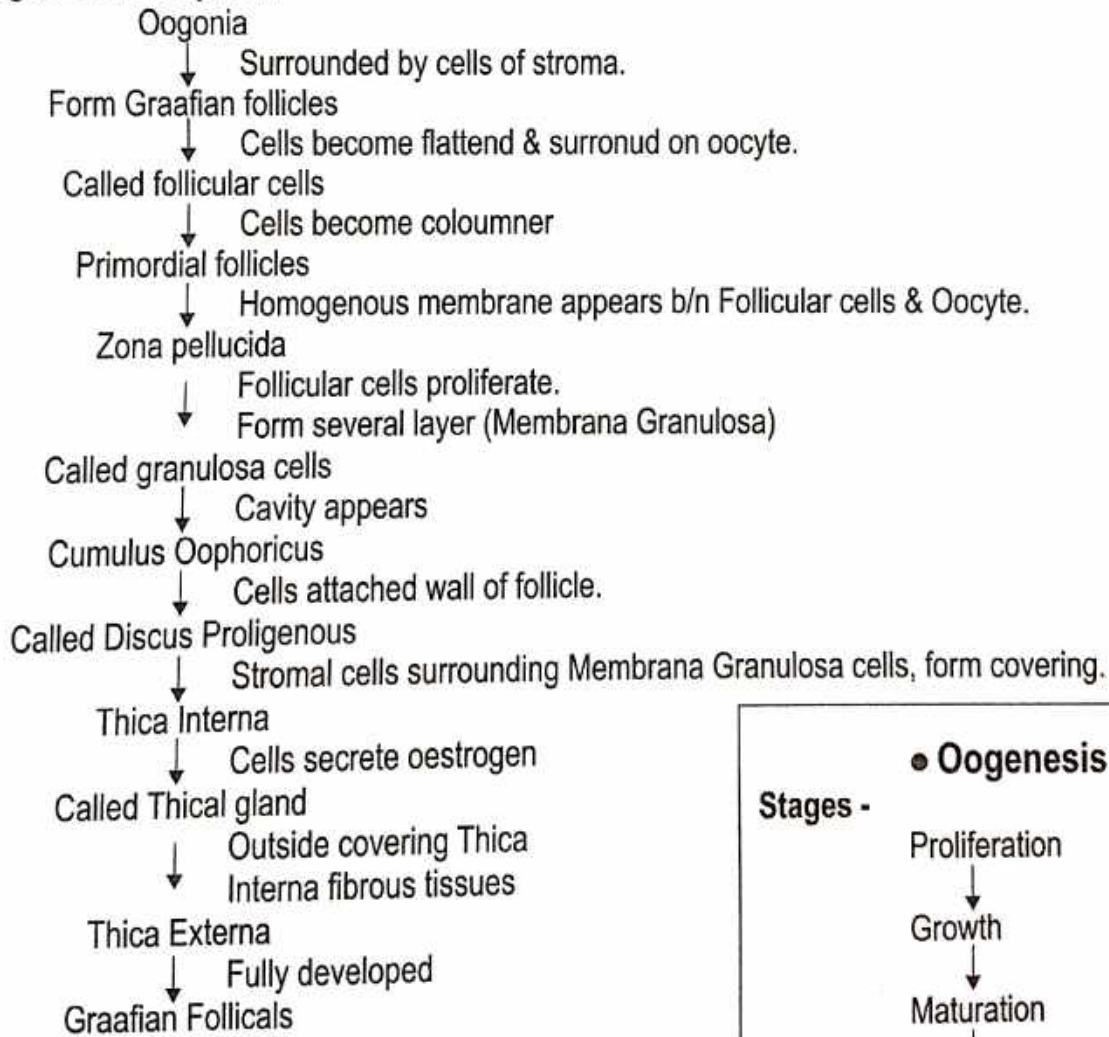
तेषु कुणपग्रन्थिपूतिपूयक्षीणमूत्रपुरीषप्रकाशमसाध्यं साध्यमन्यच्चेति ।  
प्रकाशमसाध्यं साध्यमन्यच्चेति ।

(सु. शा. 2/4)



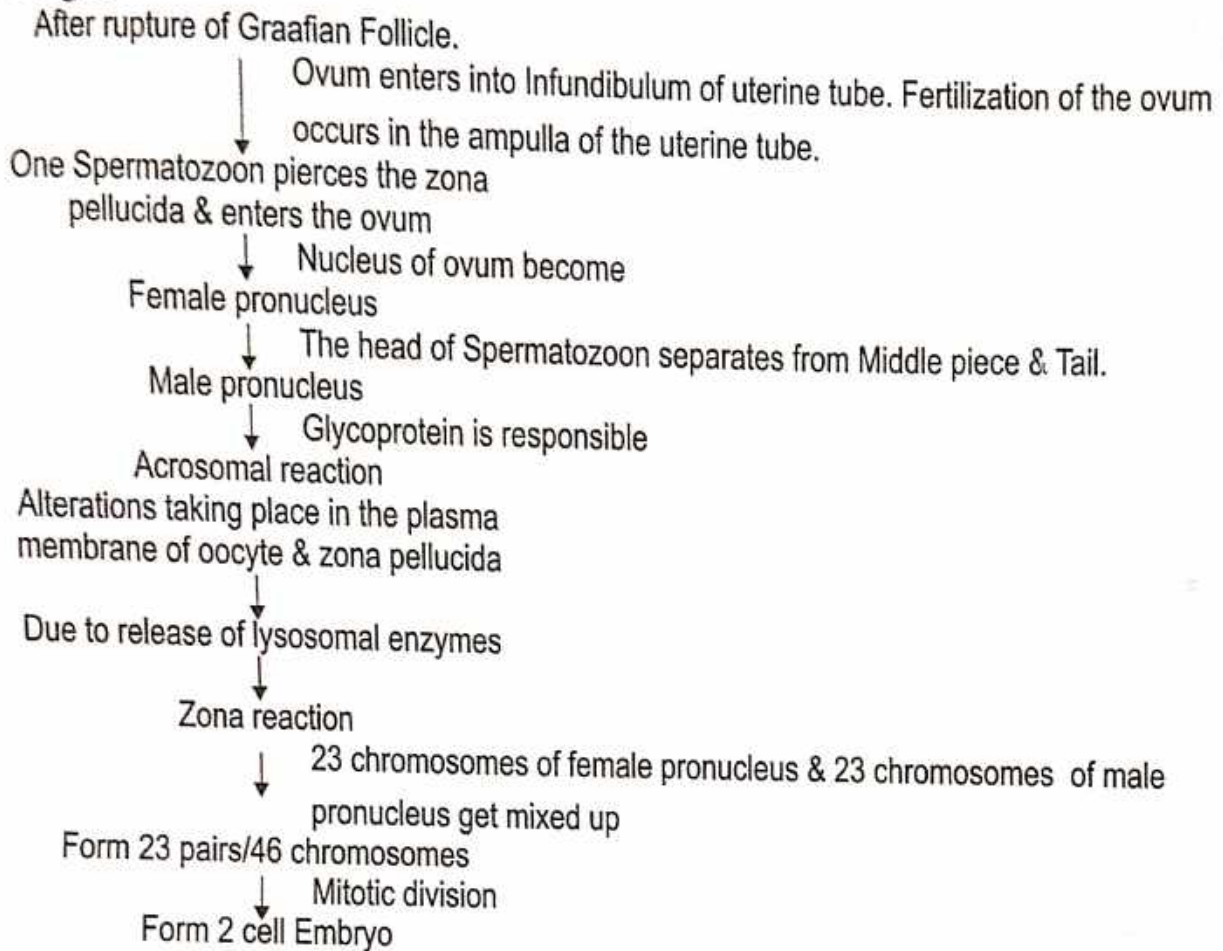
**Structure of Mature Oocyte**

★ Stages of development -

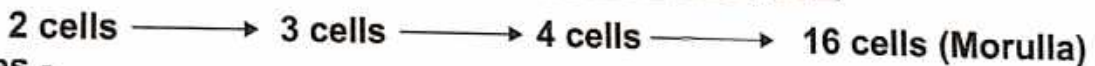


## Fertilization

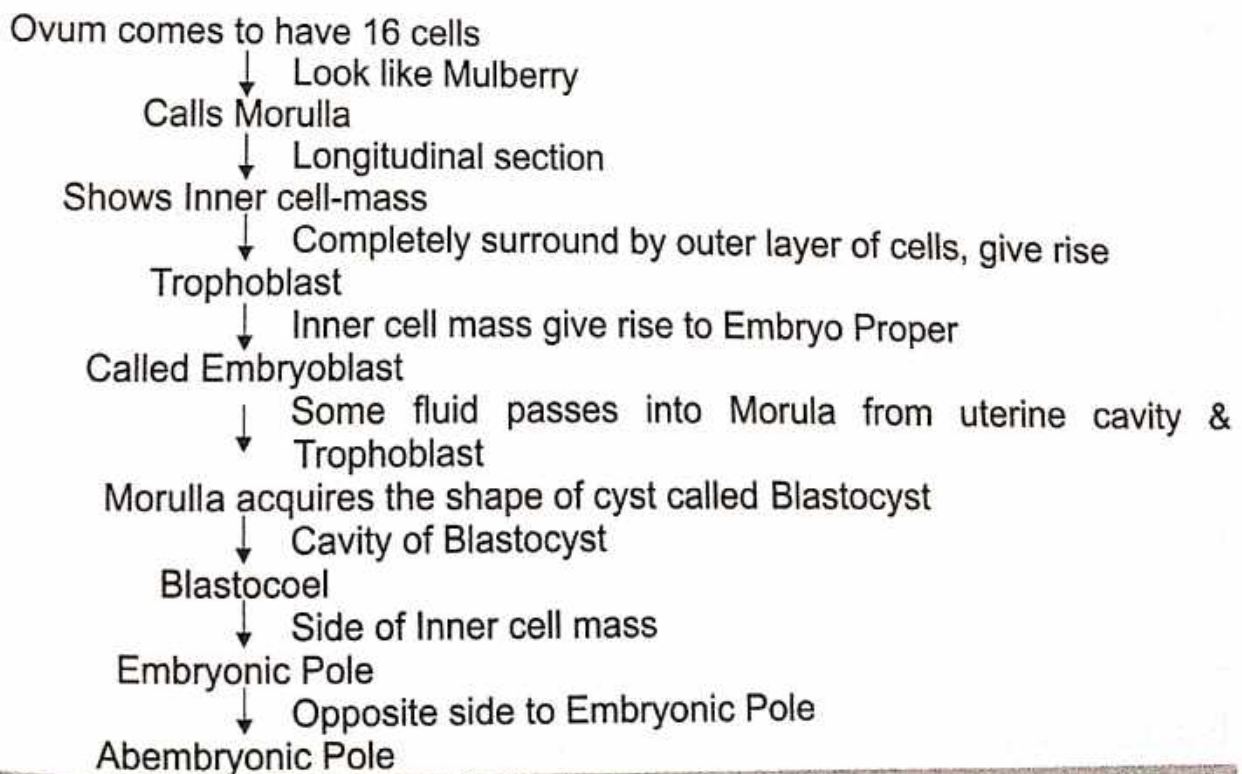
★ Stages -



## Cleavage (Subdivision of Embryo)

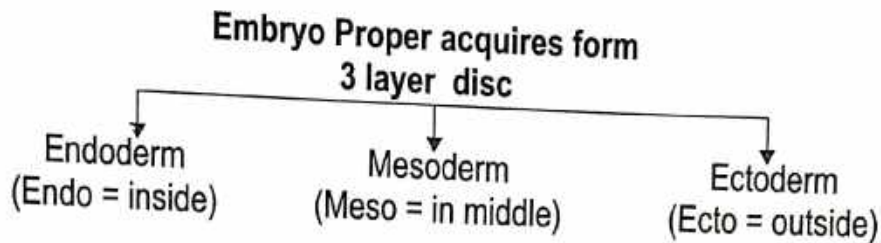


★ Stages -

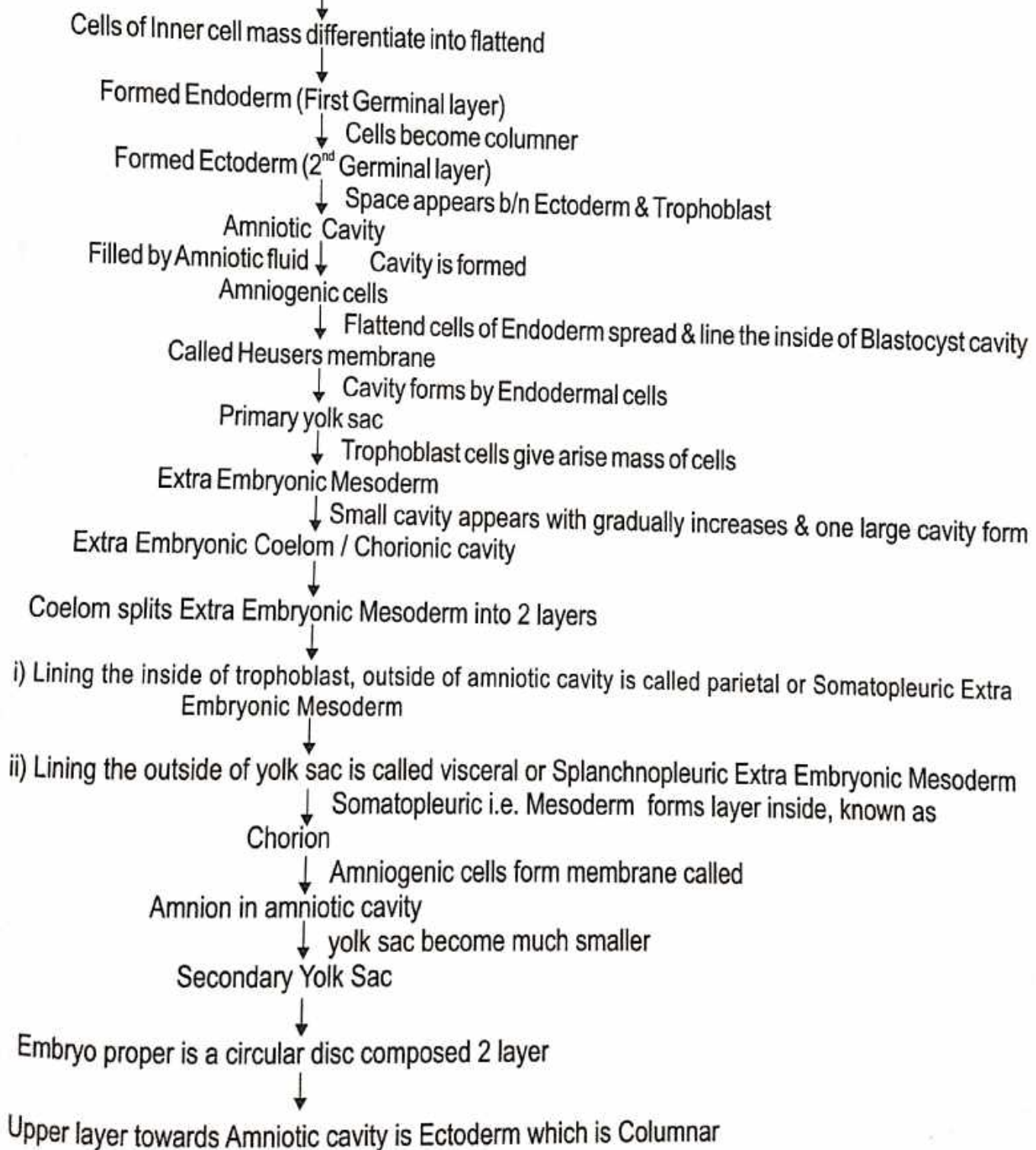


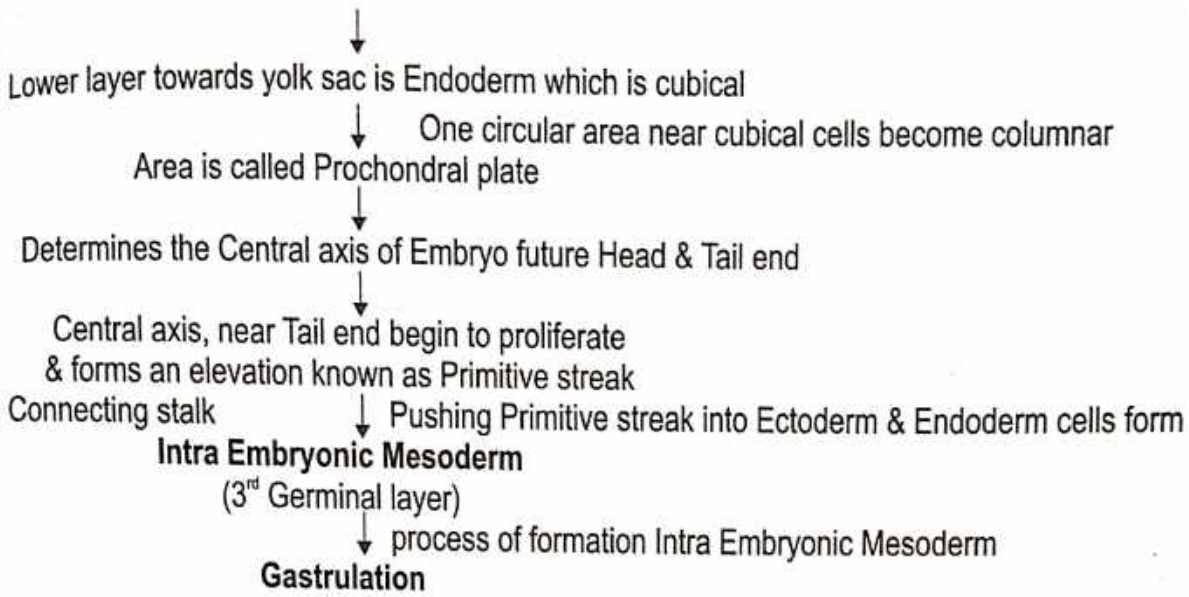
## Formation of Germinal Layers

Development stages -



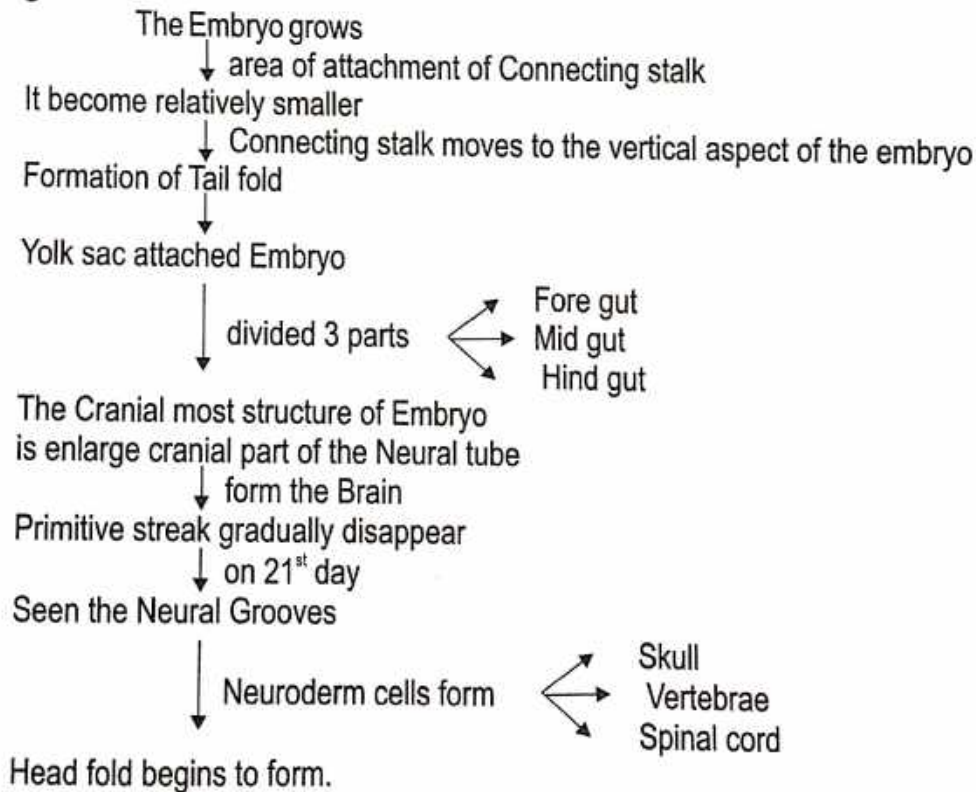
### • Further changes in Blastocyst





### Formation of Embryo

★ **Stages -**



★ **According to Ayurveda -**

1. शुक्रशोणितं गर्भाशयस्थमात्मप्रकृतिविकारसम्मूर्च्छितं 'गर्भ' इत्युच्यते ।  
तं चेतनावस्थितं वायुर्विभजति, तेज एनं पचति, आपः क्लेदयन्ति, पृथिवी संहन्ति, आकाशं विवर्धयति ॥  
(सु.शा. 5/2)
2. गर्भस्तु खल्वन्तरिक्षवाय्वग्नितोयभूमिविकारश्चेतनाधिष्ठानभूतः ।  
(च.शा. 4/6)



## Development of Embryo (According to Ayurveda)

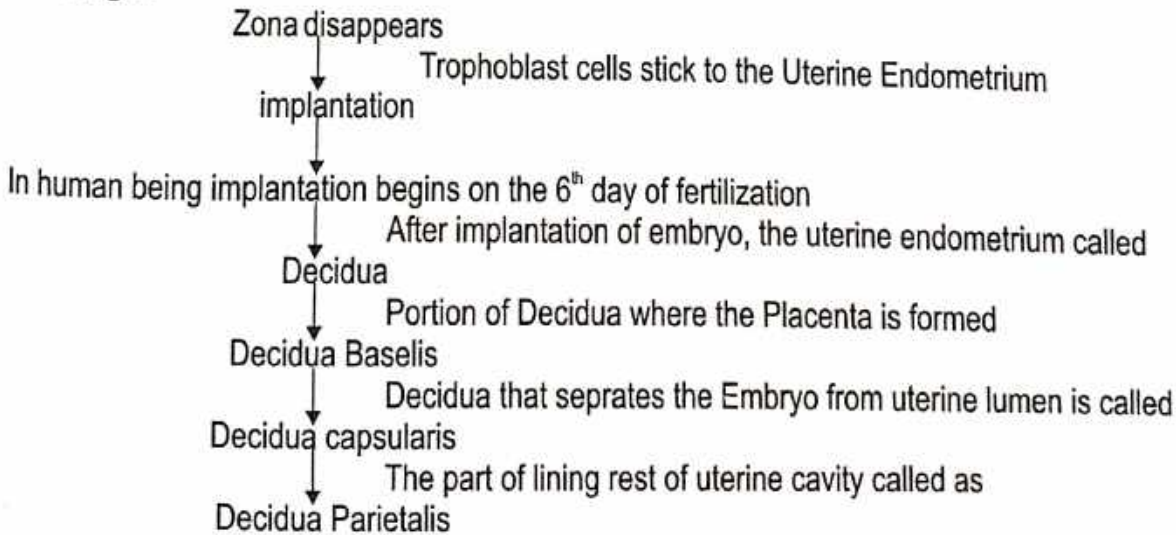
- प्रथम मास - "तत्र प्रथमे मासि कललं जायते ।" (सु.शा. 3/18)
- द्वितीय मास- "द्वितीये शीतोष्मानिलैरभिप्रपच्यमानानां महाभूतानां संघातो घनः संजायते ।" (सु.शा. 3/19)
- तृतीय मास- "तृतीये हस्तपादशिरसां पञ्च पिण्डका निर्वर्तन्ते ।" (सु.शा. 3/20)
- चतुर्थ मास - "चतुर्थे सर्वांगप्रत्यंगविभागः प्रव्यक्ततरो भवति ।" (सु.शा. 3/21)
- पंचम् मास - "पञ्चमे मनः प्रतिबुद्धतरं भवति ।" (सु.शा. 3/35)
- षष्ठम् मास - "षष्ठे बद्धिः ।" (सु.शा. 3/36)
- सप्तम् मास- "सप्तमे सर्वांग प्रत्यंगविभागः प्रव्यक्ततरः ।" (सु.शा. 3/37)
- अष्टम् मास - "अष्टमेऽस्थिरीभवत्योजः ।" (सु.शा. 3/38)
- नवम् एवं दशम मास - "नवमदशमैकादशद्वादशानामन्यतमस्मिन् जायते ।" (सु.शा. 3/39)

गर्भोत्पत्ति क्रम -

| चरक संहिता (च.शा. 6/21)    |                        | सुश्रुत संहिता (सु.शा. 3/41) |                        |
|----------------------------|------------------------|------------------------------|------------------------|
| आचार्य                     | गर्भावयव               | आचार्य                       | गर्भावयव               |
| 1. कुमार शिरा भरद्वाज -    | शिर                    | 1. शौनक -                    | शिर                    |
| 2. बार्हीक भिषक् कांकायन - | हृदय                   | 2. कृतवीर्य -                | हृदय                   |
| 3. भद्रकाप्य -             | नाभि                   | 3. पाराशर्य -                | नाभि                   |
| 4. भद्रशौनक -              | पक्वाशय, गुद           | 4. मार्कण्डेय -              | पाणिपाद                |
| 5. बडिश -                  | हस्तपाद                | 5. सुभुति गौतम -             | मध्यशरीर               |
| 6. वैदेह जनक -             | इन्द्रियाँ             | 6. धन्वन्तरि -               | युगपत्सर्वांग उत्पत्ति |
| 7. मारीचि कश्यप -          | अचिन्त्य               |                              |                        |
| 8. धन्वन्तरि -             | युगपत्सर्वांग उत्पत्ति |                              |                        |

## Implantation

★ Stages -



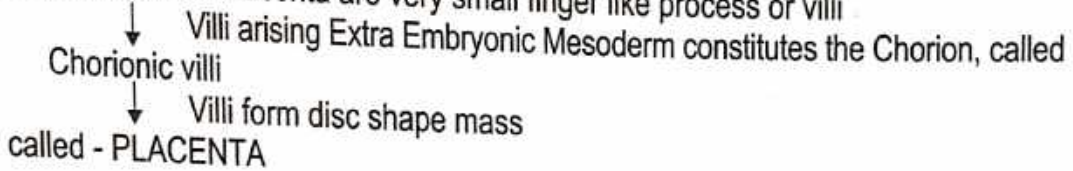
## FORMATION OF PLACENTA

● तस्यास्तु खल्वपरायाः प्रपत्तनार्थे कर्मणि क्रियमाणे ।

(च.शा.8/45)

### ★ Stages of Development -

Functional elements of Placenta are very small finger like process or villi



### ★ Stages of Villi formation -

Trophoblast cells made up single layer & these multiply two distinct layer

- i. Syncytium or Syncytiotrophoblast
- ii. Cytotrophoblast

Syncytium grows rapidly & appear lacunae

↓ Lacunae are separated from partitions of syncytium called  
Trabeculae

↓ Lacunar space formed

Endometrium erodes by syncytium blood vessels are opened up & blood from them fills the lacunar space

Trabeculae comes to have a central core cytotrophoblast surround by maternal blood filling the lacunar space

↓ Trabeculus is called  
Primary villus

↓ Lacunar space is called  
Inter villous space

↓  
Secondary villous

↓  
Tertiary villous

↓ Cytotrophoblast emerges through the syncytium, form a layer  
Called Cytotrophoblastic shell

- villi attached on foetal side to the Embryonic Mesoderm

- on maternal side to the Cytotrophoblastic shell Villi called  
Anchoring villi

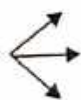↓

Each Anchoring villous consist of a stem

Truncus chorii → Branches - Rami chorii → Turn finger branches - Ramuli chorii

Anchoring villous form a disc shape structure

called - PLACENTA - Which have



15-20 lobes

Diameter - 6 to 8 inch

weight about - 500 g.m.

## Umbilical Cord (नाभिनाडी)

Length - 18-20 inch or 50 cm

Contains - one Umbilical vein & two Umbilical artery

● “प्रततोत्तानशायिन्याः पुनर्गर्भस्य नाभ्याश्रया नाडी कण्ठमनुवेष्टयति ।”

(च.शा. 8/21)

### ● Organ or System formed to Germinal Layers :

#### 1. Ectoderm

- |                      |   |                                  |
|----------------------|---|----------------------------------|
| 1. Epidermis (Skin)  | 6. Pituitary Mid & hind<br>(Post. lobe - Neurohypophysis) | 10. Internal ear & External ear. |
| 2. Nervous System    | 7. Pineal body  | 11. Buccal cavity                |
| 3. Pigment cells     | 8. Retina, cornea, lens.                                  | 12. Sensory organ                |
| 4. Cranial Cartilage | 9. Nasal epithelium                                       | 13. Rectum                       |
| 5. Adrenal Medulla   |   | 14. Brain                        |

#### 2. Mesoderm

- |                                   |   |                          |
|-----------------------------------|---|--------------------------|
| 1. Dermis (Skin)                  | 6. Heart muscles &<br>Circulatory system. | 10. Gonads               |
| 2. Vertebral Column               | 7. Kidney                                 | 11. Excretory System     |
| 3. Apendicular skeleton           | 8. Adrenal cortex                         | 12. Lymphatic System     |
| 4. Blood                          | 9. Coelomic epithelium                    | 13. Spleen               |
| 5. Streated, Nonstreated muscles. |   | 14. Reproductive System. |

#### 3. Endoderm

- |   |  |            |
|---|--|------------|
| 1. Internal Epithelium                        | 5. Internal layer of vagina                      |            |
| 2. Thyroid, Parathyroid gland                 | 6. Alimentary system<br>(Gastrointestinal Tract) | 1. Foregut |
| 3. Pituitary gland (Ant lobe adenohipophysis) |  | 2. Midgut  |
| 4. Thymus gland                               |  | 3. Hindgut |

#### 1. Derivatives of Foregut

- (i) Tongue
- (ii) Pharynx
- (iii) Pharyngeal pouches, Thyroid & Middle Ear.
- (iv) Oesophagus
- (v) Stomach
- (vi) Liver & Extra hepatic biliary system
- (vii) Pancreas
- (viii) Lungs (Respiratory system)
- (ix) Duodenum :- Sup. first part & Upper half part of Descending Second part.

#### 2. Derivatives of Midgut

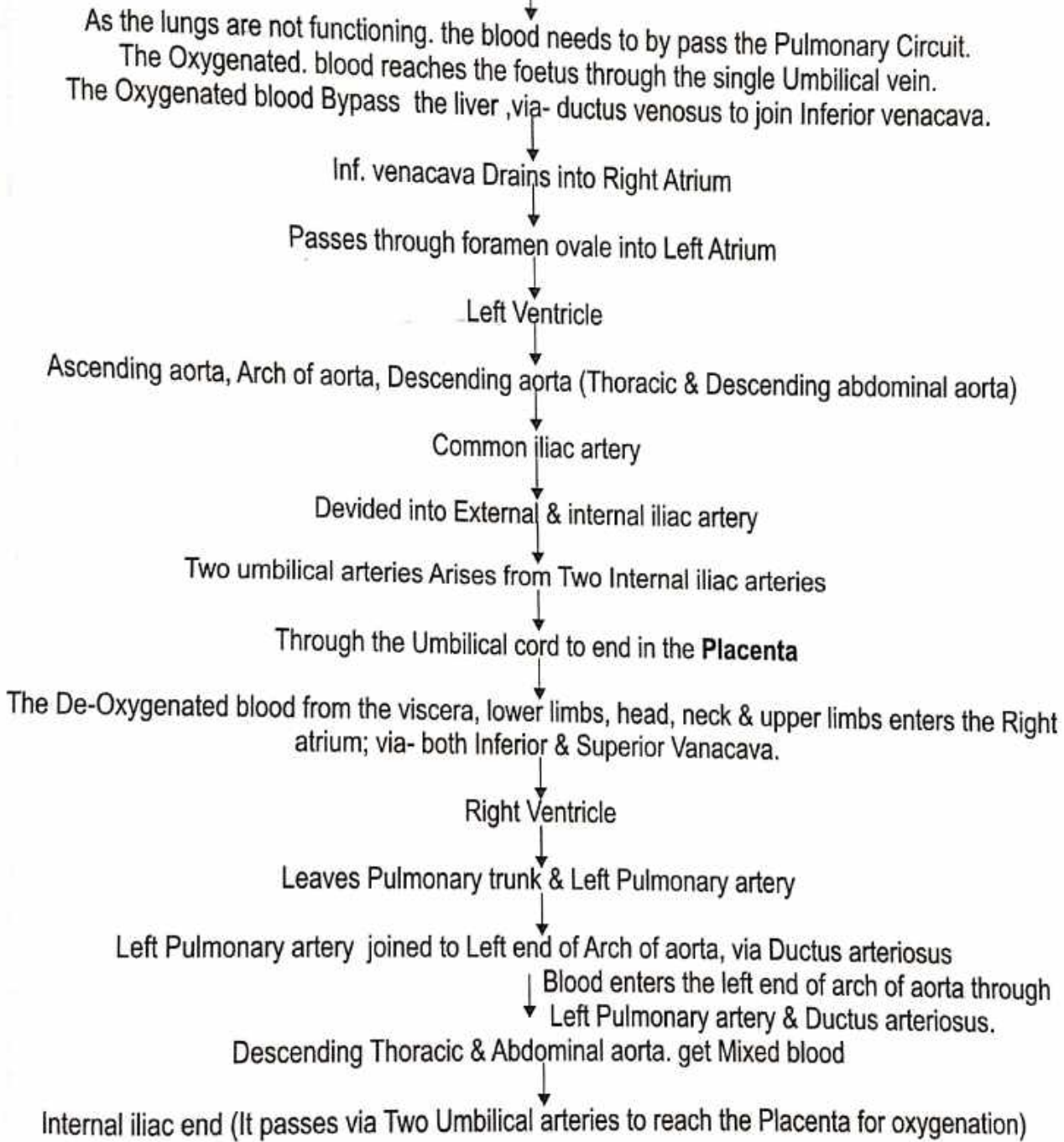
- (i) Duodenum : Descending Second part distal to horizontal. Third & Ascending Fourth part.
- (ii) Jejunum
- (iii) Ileum
- (iv) Caecum & Appendix
- (v) Ascending colon
- (vi) Right 2/3 of Transverse Colon.

#### 3. Derivatives of Hindgut:

- (i) Left 1/3 of Transverse Colon
- (ii) Descending & Pelvic Colon
- (iii) Rectum
- (iv) Upper part of Anal canal
- (v) Parts of Urogenital system derived from the Primitive Urogenital Sinus.

## FOETAL CIRCULATION

“मातुस्तु खलुरसवहायां नाड्यां गर्भनाभिनाडी प्रतिबद्धा, साऽस्य मातुराहारसवीर्यमभिवहति।” (सु.शा. 3/40)



Bypassing the Lungs for providing Oxygen & Nutrition to the developing Embryo & foetus-

**Following structure -**

- |                       |                      |                            |
|-----------------------|----------------------|----------------------------|
| 1. One Umbilical vein | 3. Foramen ovale     | 5. Two Umbilical arteries. |
| 2. Ductus venosus     | 4. Ductus arteriosus |                            |

Time of birth, with start of breathing process, changes at birth-

- |   |  |
|---|--|
| 1. Lungs Start functioning.                 | 4. Foramen Ovale closes.                               |
| 2. Umbilical vein forms Ligamentum teres.   | 5. Ductus arteriosus forms Ligamentum arteriosum.      |
| 3. Ductus venosus forms Ligamentum venosun. | 6. Umbilical arteries form Medial umbilical Ligaments. |

**OSTEOLOGY**  
**(आरिथशास्त्र)**

# UPPER LIMB

## CLAVICLE

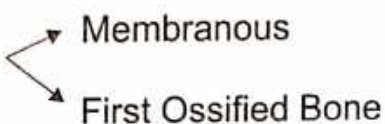
### Name of Bone-

- According to Ayurveda - अक्षकास्थि
- According to Modern- Clavicle

**Position** - Horizontally in root of neck.

### Type of Bone -

- According to Ayurveda - नलकास्थि
- According to Modern- Long bone

**Ossification** - 

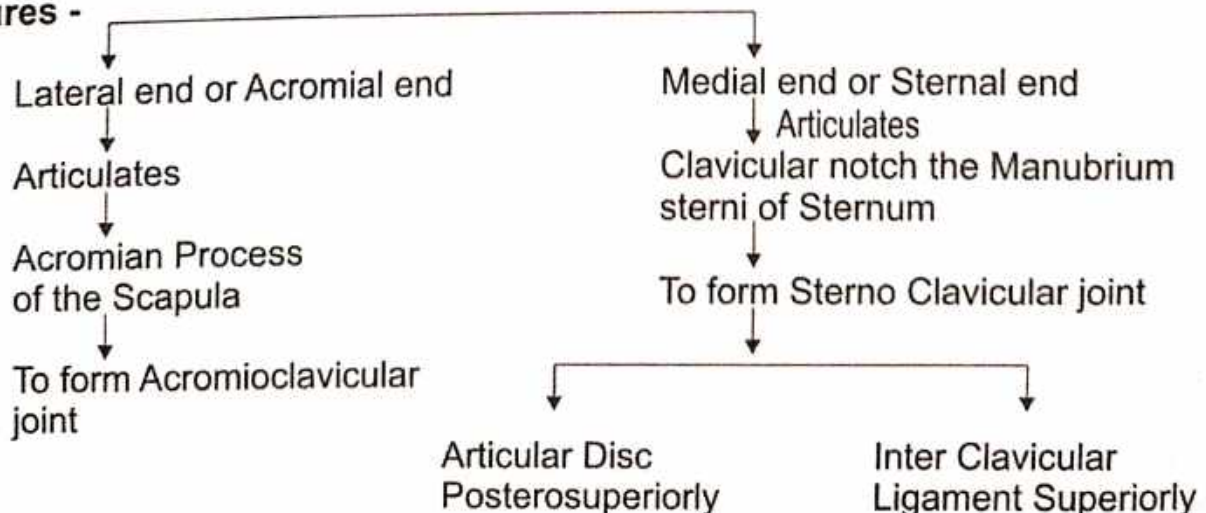
### Peculiarities of the Clavicle -

- Only Long Bone that lies Horizontally.
- It is only Long bone which have two Primary Centre of Ossification.
- Only Long Bone have no Medullary Cavity.
- It is first Bone to start Ossification.
- Only Long Bone that lies Subcutaneously.

### Side Determination -

- Lateral end - flat
- Medial end - Quadrangular
- Inferior Surface - Grooved Longitudinally

### Features -



● PARTS OF SHAFT

Medial 2/3

Lateral 1/3

● Surfaces of Medial 2/3

Anterior

● Pectoralis major (o)

Posterior

● Sternohyoid (o)

Superior

● Sternocleido Mastoid (o)

Inferior

Medial end

● Oval impression  
● Costoclavicular Ligament

Lateral half

Subclavian groove

Nutrient Foramen

Subclavius Muscle (l)

Behind

Subclavian artery

● Lateral 1/3

2 Borders

Anterior

Deltoid (O)

Posterior

Trapezius (l)

2 Surface

Superior

Subcutaneous

Inferior

Conoid Tubercle

Conoid part of Coraco Clavicular Ligament

Trapezoid Ridge

Trapezoid part of Coraco Clavicular Ligament

## SCAPULA

### Name of Bone-

- According to Ayurveda - अंसफलक
- According to Modern- Scapula

**Position** - Posterolateral to Thorax.

### Type of Bone

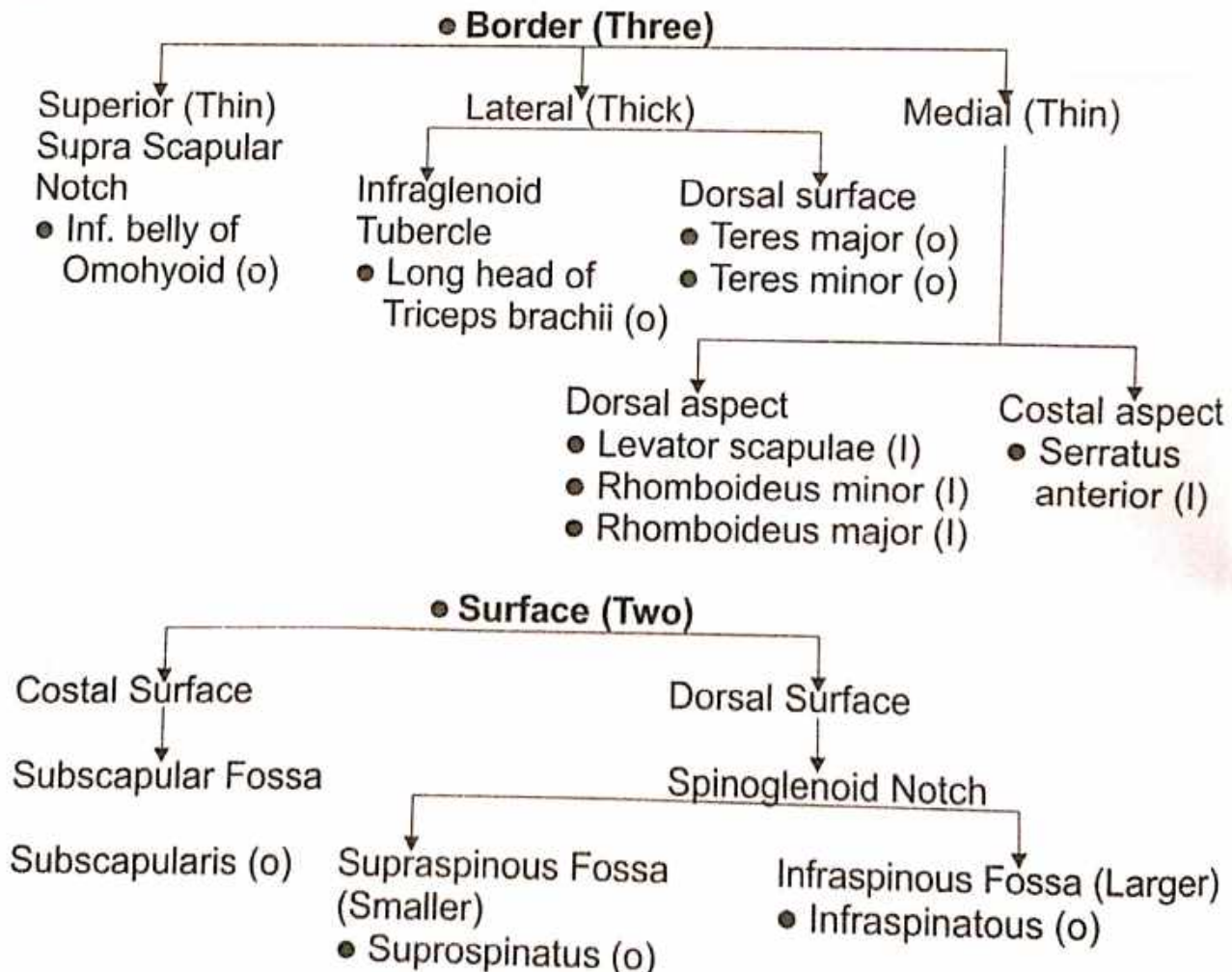
- According to Ayurveda - कपालास्थि
- According to Modern - Flat bone

**Ossification** - Cartilagenous

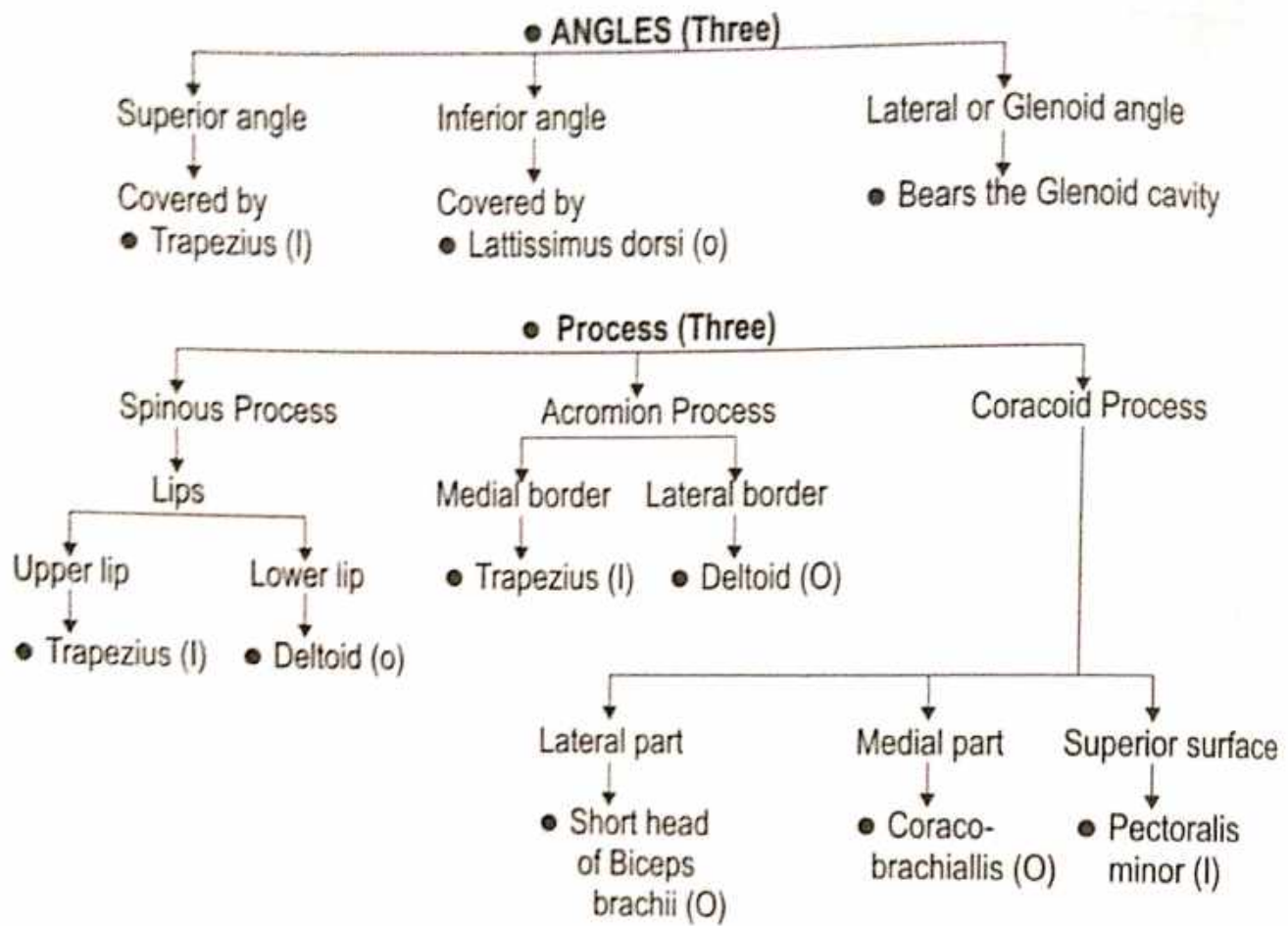
### Side Determination -

1. Lateral Angle - Glenoid cavity lies laterally
2. Dorsal Surface - Spinous process
3. Costal Surface - Subscapular Fossa
4. Inferior Angle - Lies inferiorly

### Feature -







## HUMERUS

### Name of Bone-

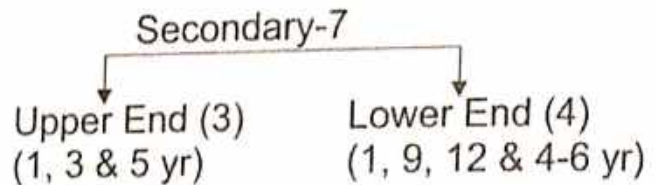
- According to Ayurveda - प्रगण्डास्थि
- According to Modern - Humerus

### Type of Bone

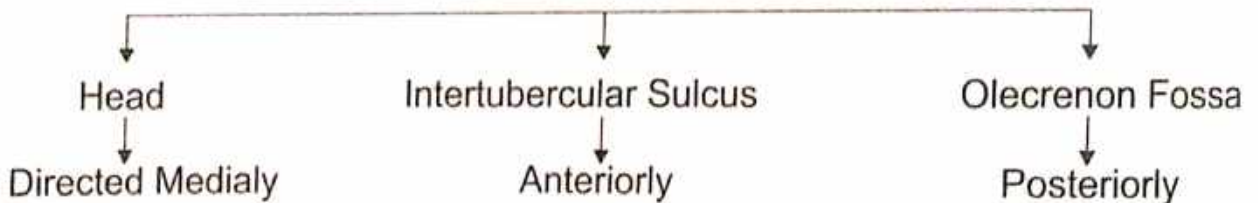
- According to Ayurveda - नलकास्थि
- According to Modern - Long bone

**Position** - In arm, it extends from Shoulder to Elbow joint.

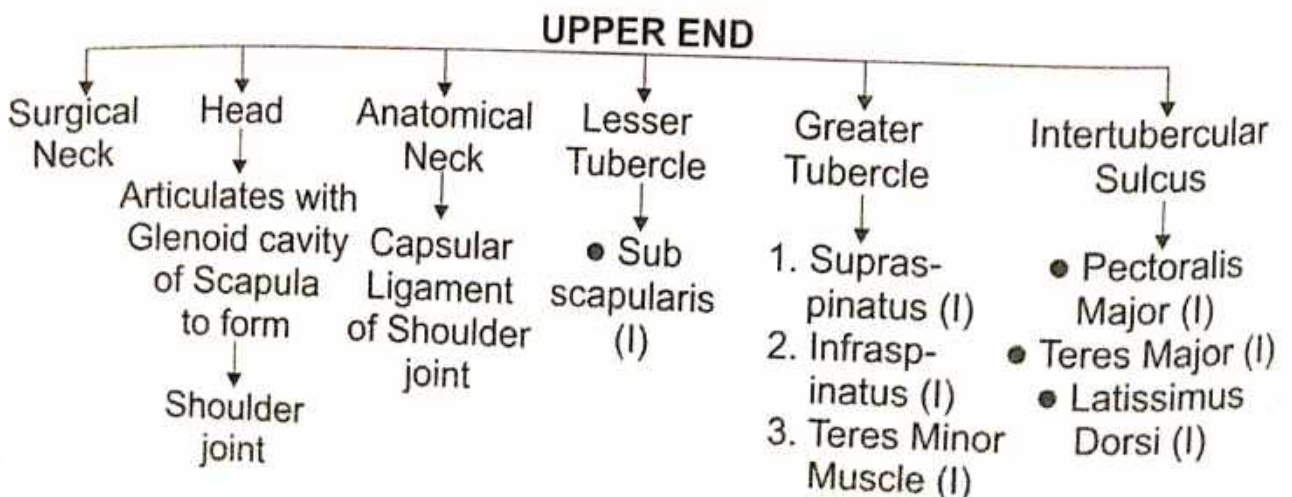
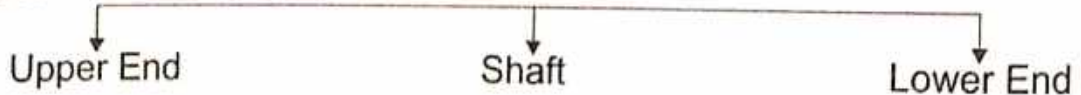
**Ossification** - Primary-1  
8<sup>th</sup> Week

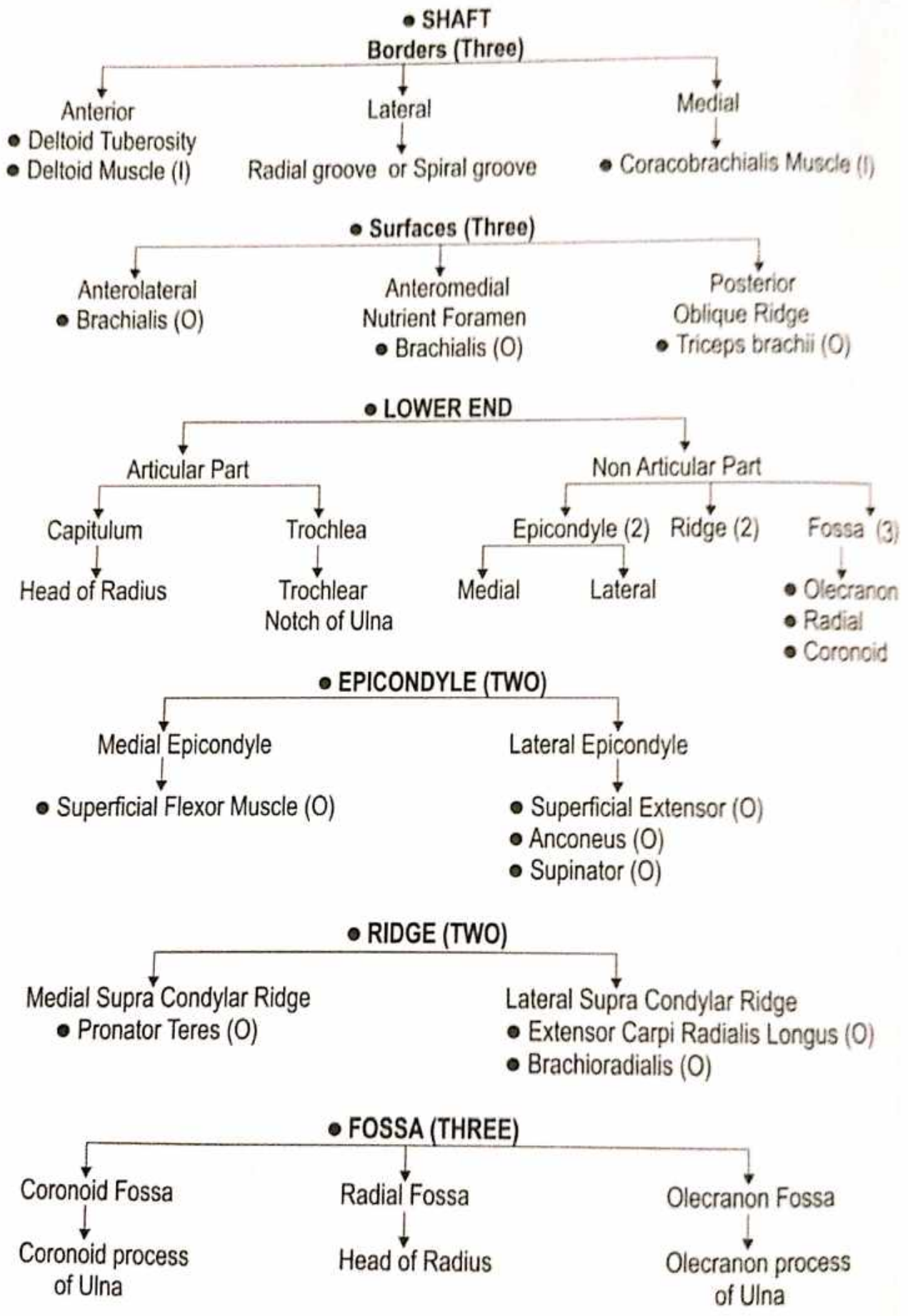


### Side Determination -



### Features -





## RADIUS

### Name of Bone-


- According to Ayurveda - बर्हिः प्रकोष्ठास्थि
- According to Modern - Radius

### Type of Bone

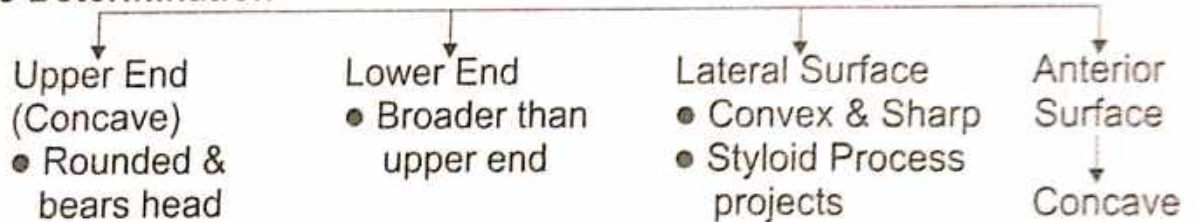
- According to Ayurveda - नलकास्थि
- According to Modern - Long bone

Situation - Lateral bone of the Fore-Arm.

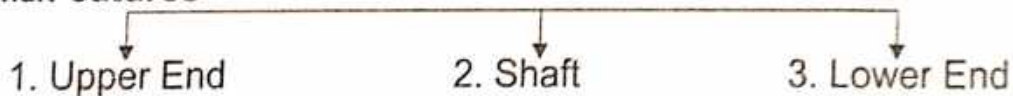
### Ossification -



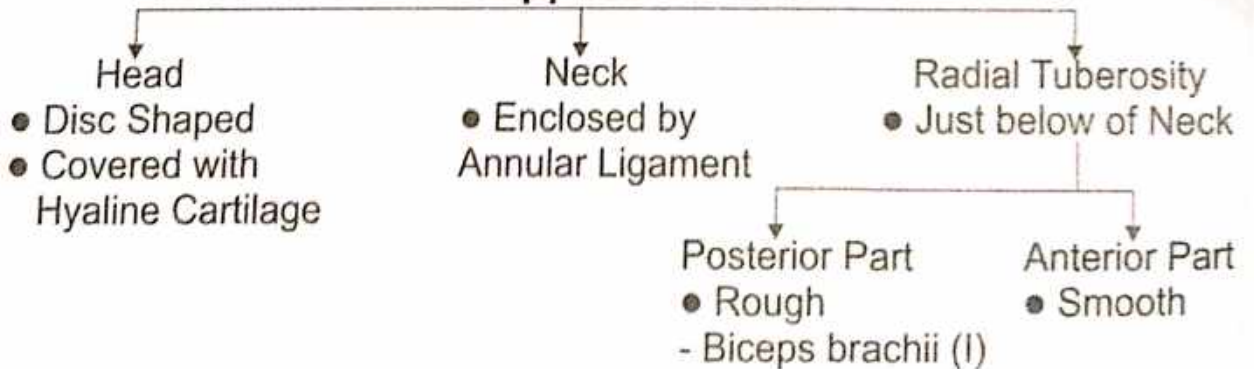
### ● Side Determination



### ● External Features




### 1. Upper End

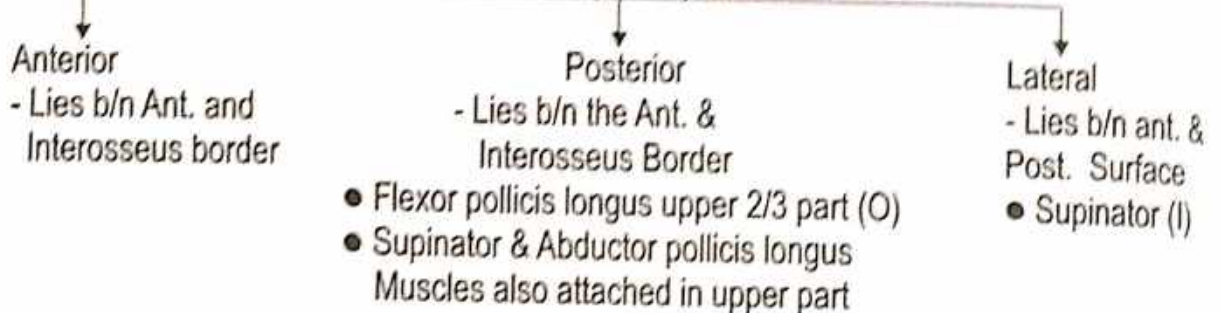


## 2. SHAFT

### Borders (Three)

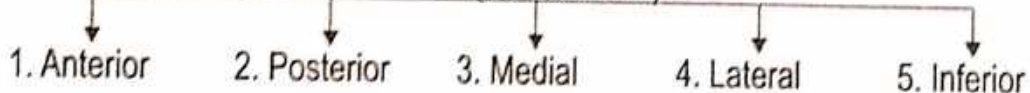

### • Surface (Three)



## 3. LOWER END

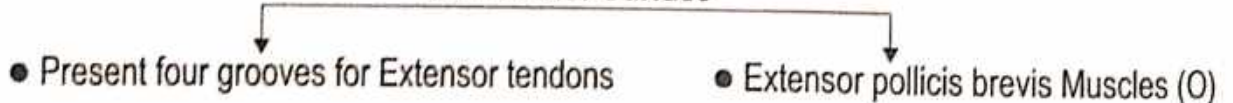### (Surface Five)



#### 1. Anterior Surface




#### 2. Posterior Surface




#### 3. Medial Surface

Occupied by ulnar notch

#### 4. Lateral Surface



#### 5. Inferior Surface



Forms wrist joint

## ULNA

### Name of Bone-

- According to Ayurveda - अंतः प्रकोष्ठास्थि
- According to Modern - Ulna

### Type of Bone

- According to Ayurveda - नलकास्थि
- According to Modern - Long bone

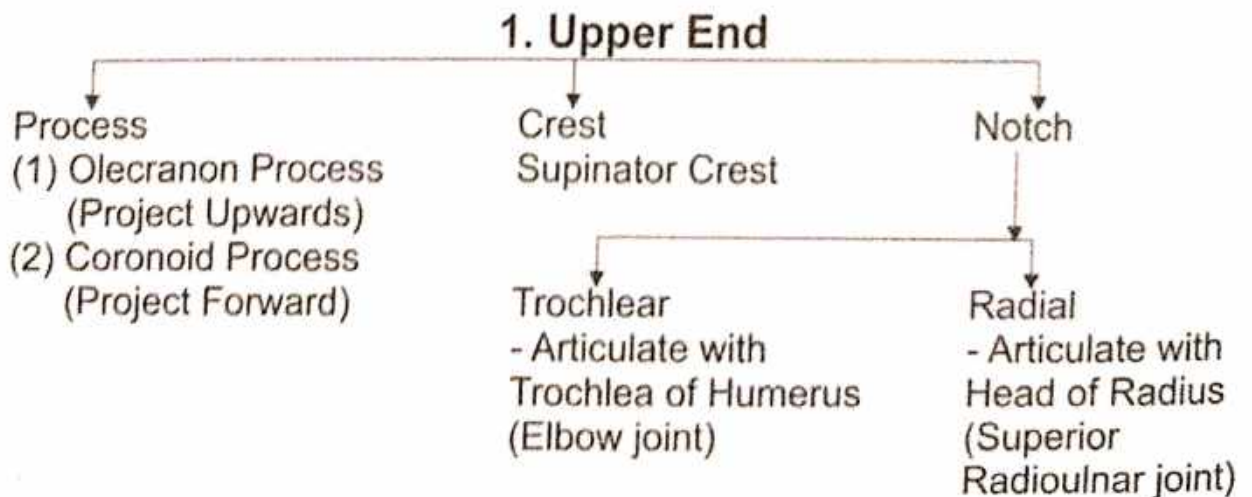
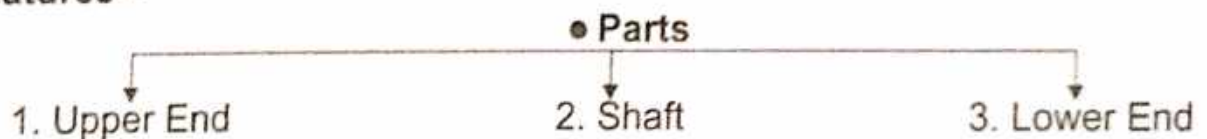
**Situation** - Medial bone of the Fore Arm.

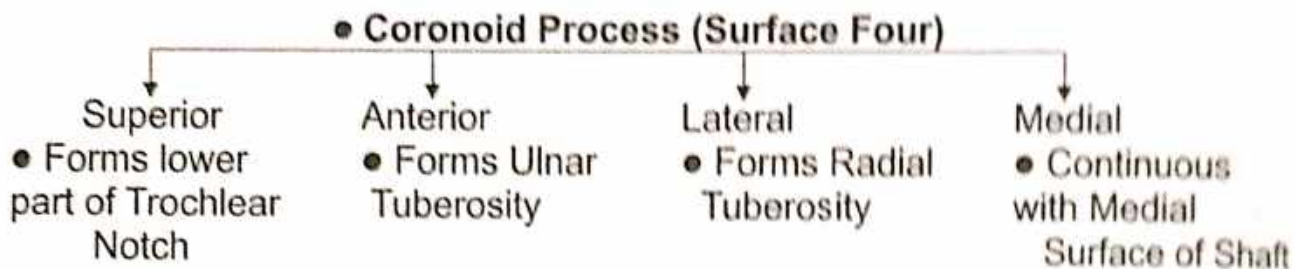
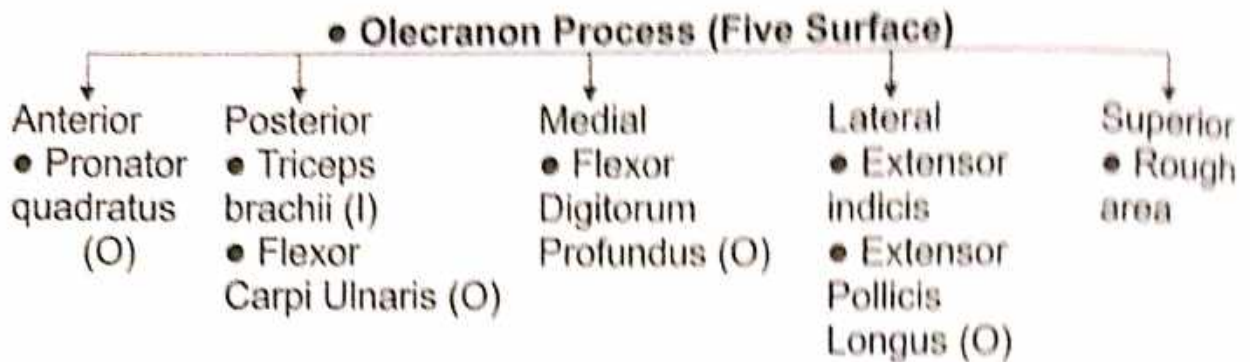


### Side Determination -

- Upper End - Hook like with its concavity directed forwards.
- Lower End - Smaller & has a small rounded head.
- Shaft - The lateral border of the shaft is sharp and crest like.
- Styloid process projects downward from the posteromedial aspect of the head.

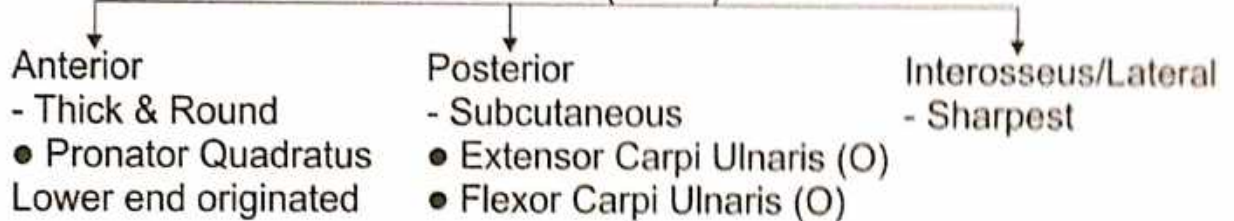
### Features -



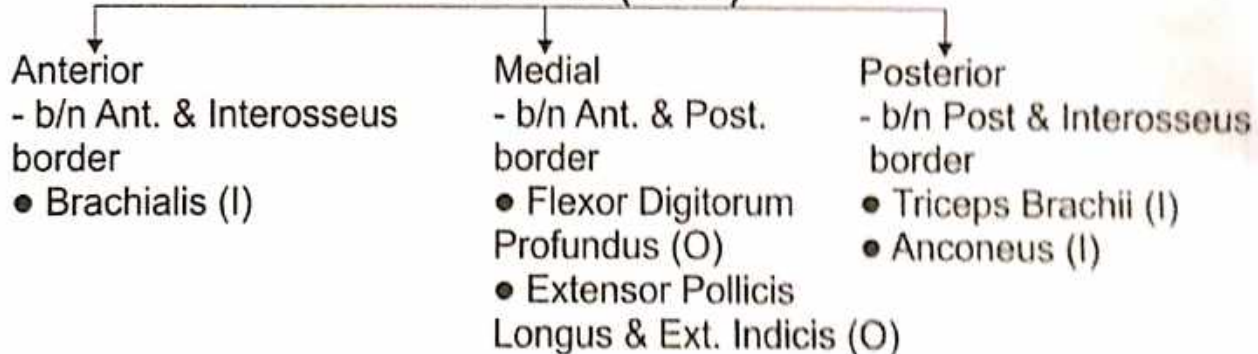


## 2. SHAFT

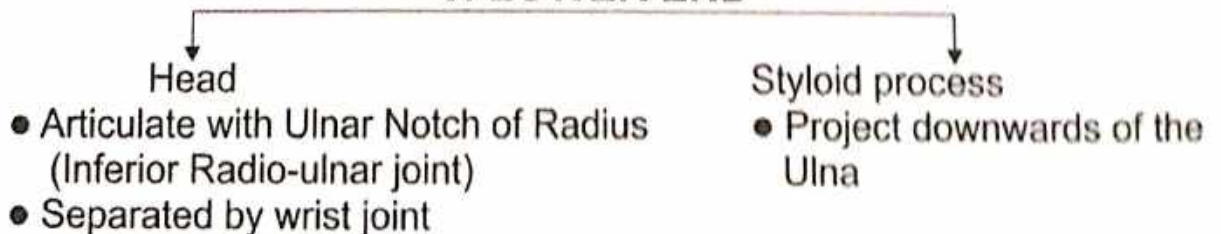
### Borders (Three)



### • Surface (Three)



## 3. LOWER END



## CARPALS

### Name of Bone-

- According to Ayurveda - करकूर्चास्थि
- According to Modern - Carpal bone

### Type of Bone


- According to Ayurveda - नलकास्थि
- According to Modern - Irregular bone, Short bone

### Position - Wrist (मणिबंध)

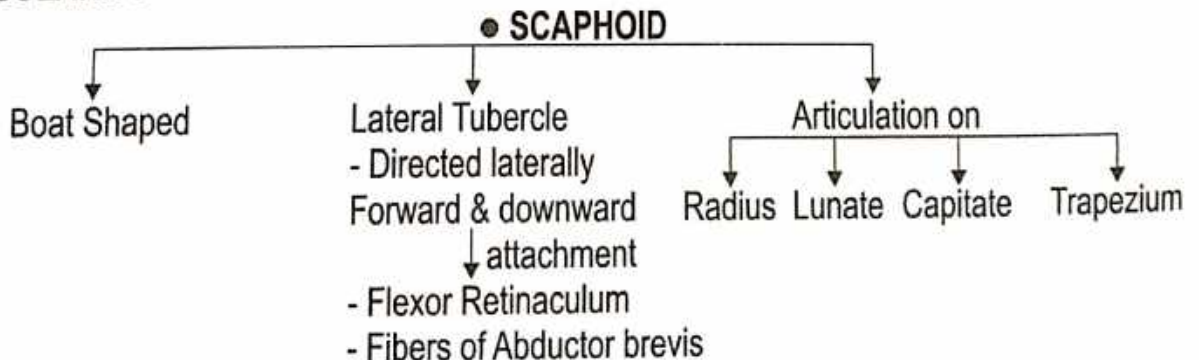
### Ossification -

- Cartilagenous.
- Ossification Centre-8.
- Each Carpal bone ossifies from one Centre of Ossification which appears after birth and the Process is usually completed between 20<sup>th</sup>, 25<sup>th</sup> year of life.

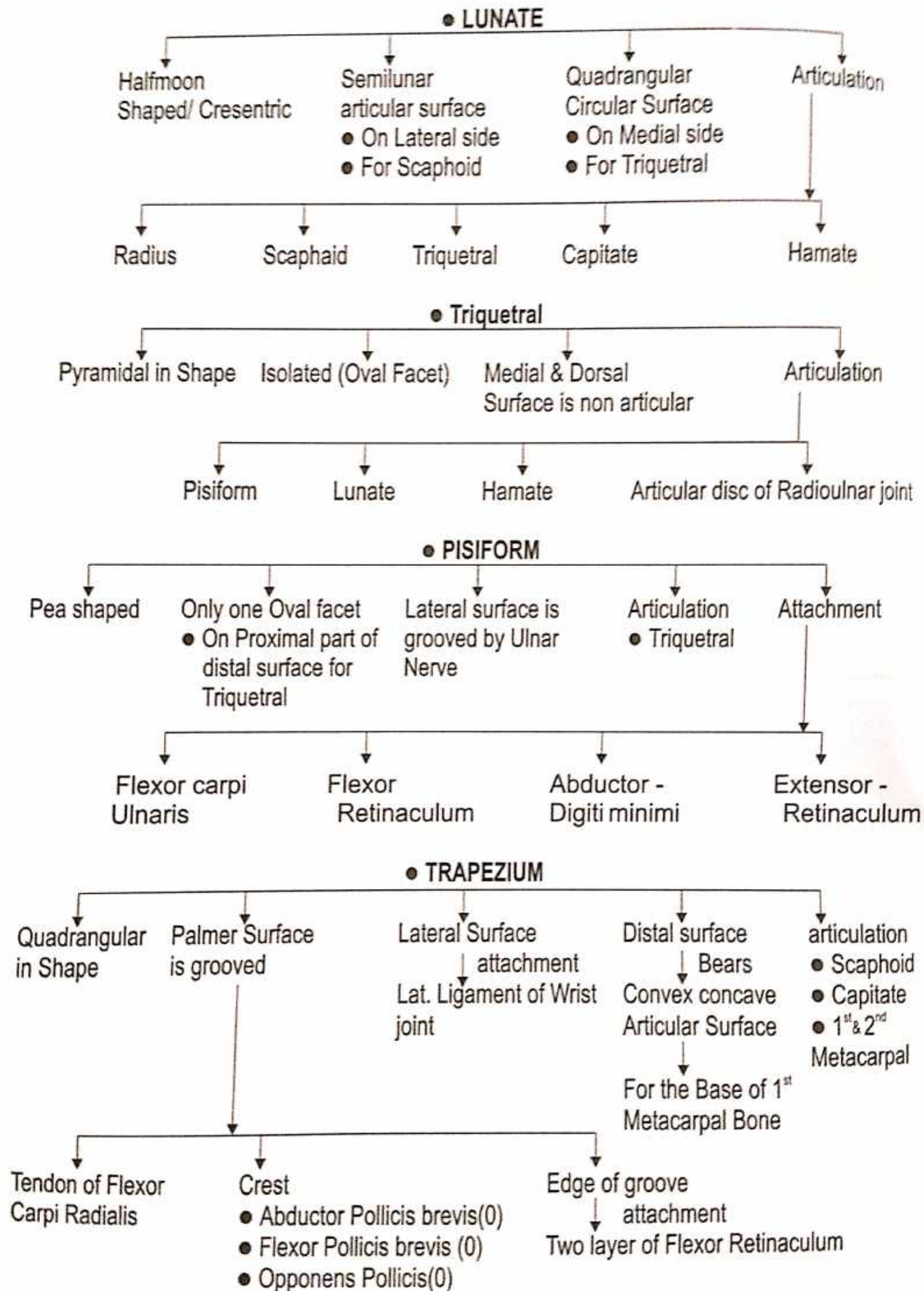
### Carpal Bones -

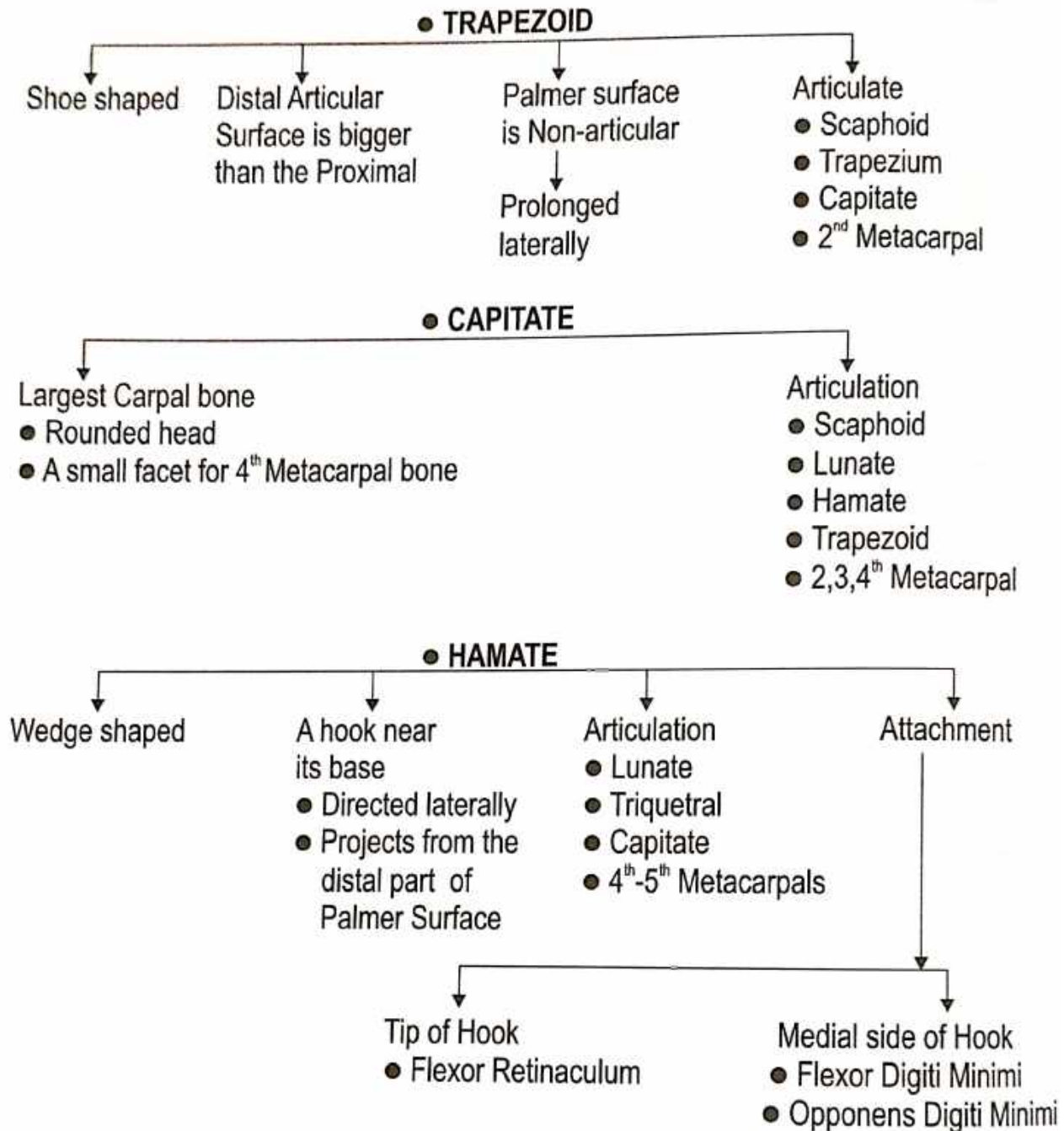


### PARTICULARITY -



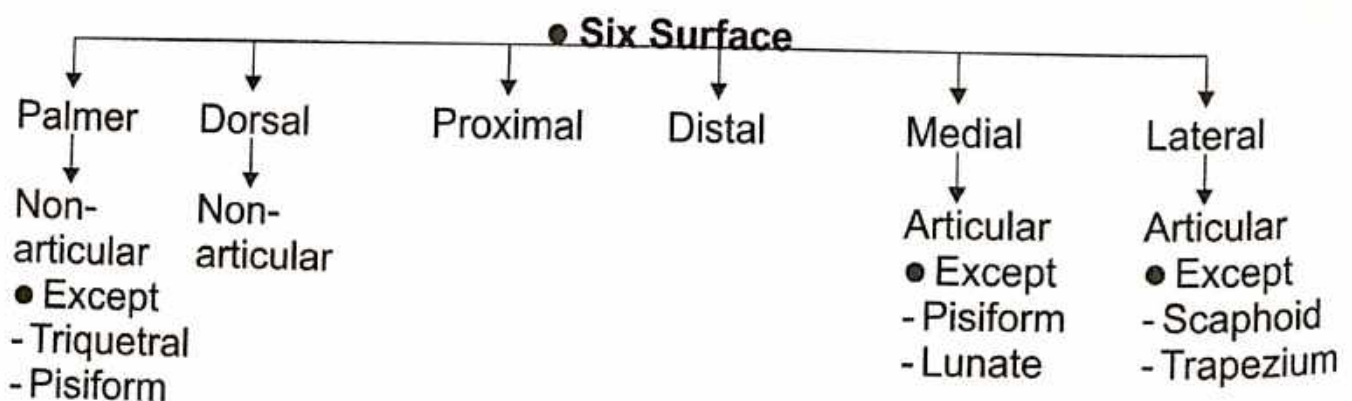






**General Points of the Carpal Bones -**

- The Proximal row is Convex proximally, and Concave distally.
- The distal row is Convex Proximally and Flat distally.
- Dorsal nonarticular surface always larger than Palmer nonarticular Surface (**Except-Lunate**).



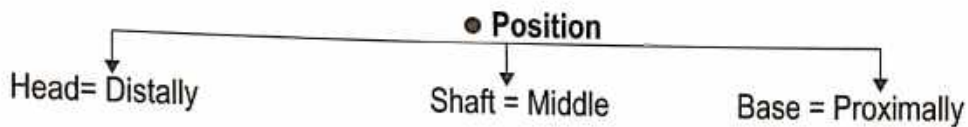
## METACARPALS

### Name of Bone-

- According to Ayurveda- हस्तशलाकायें
- According to Modern- Metacarpals

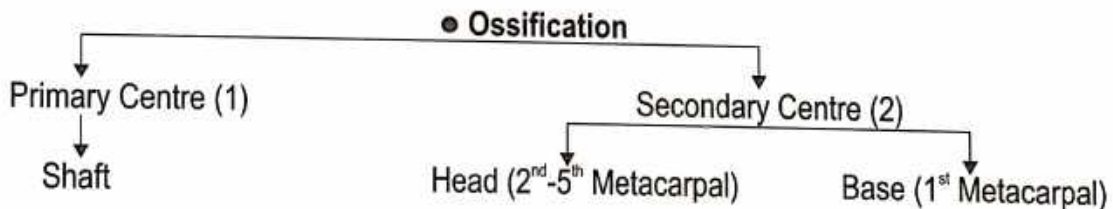
### Type of Bone-

- According to Ayurveda- करतलास्थियाँ, करभास्थियाँ
- According to Modern - Long - Short bone



### Number & Name of Metacarpal bone -

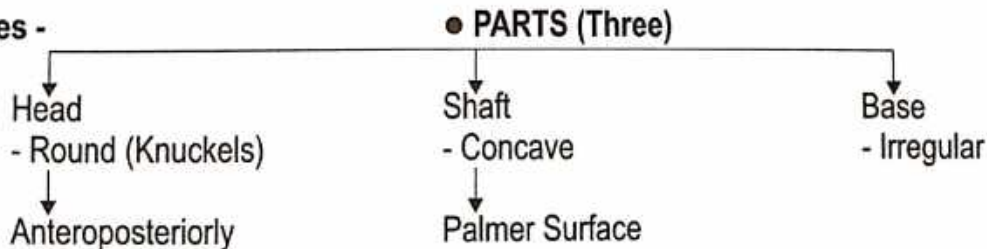
1. First Metacarpal
2. Second Metacarpal
3. Third Metacarpal
4. Fourth Metacarpal
5. Fifth Metacarpal

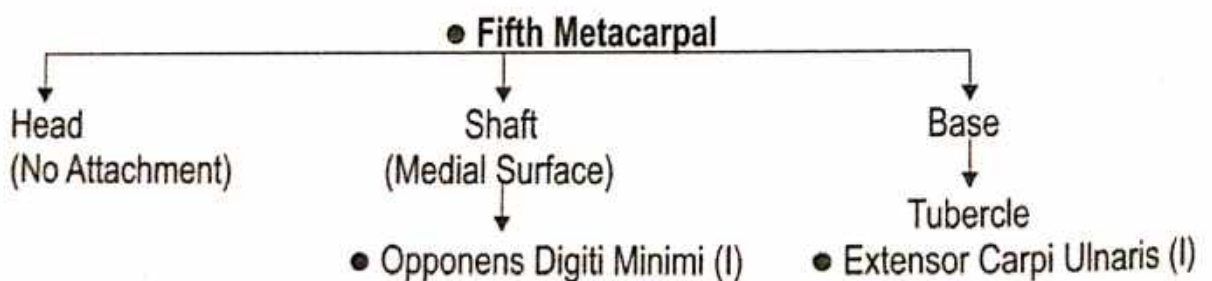
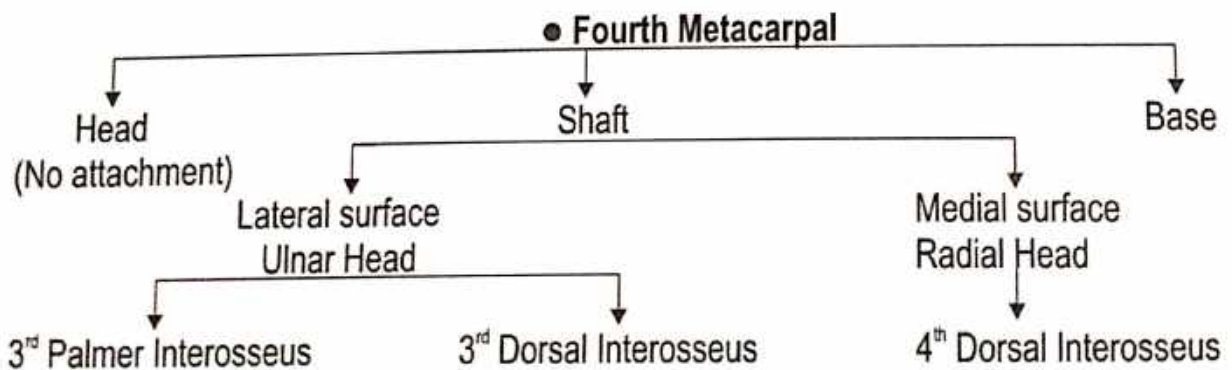
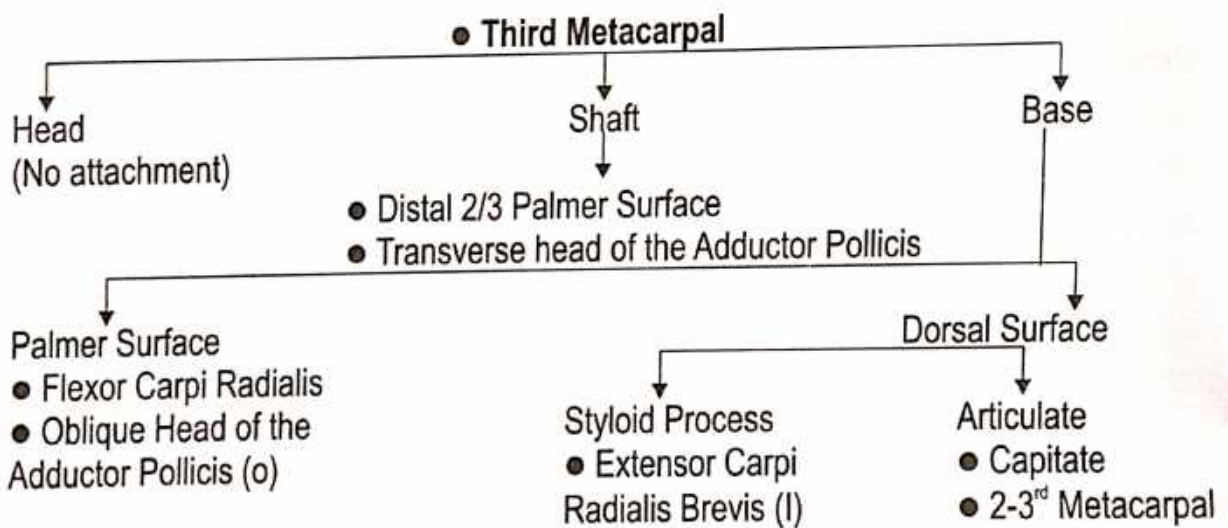
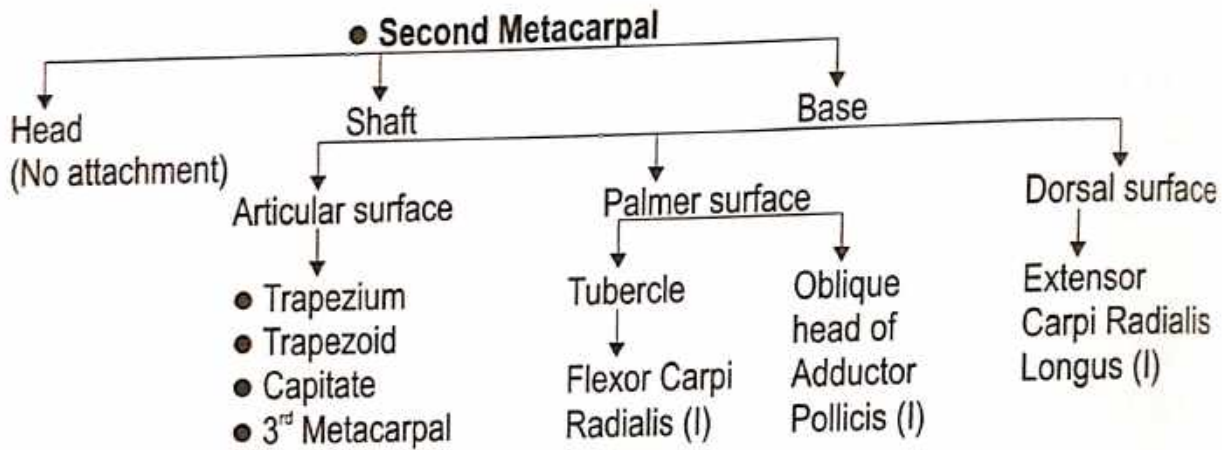
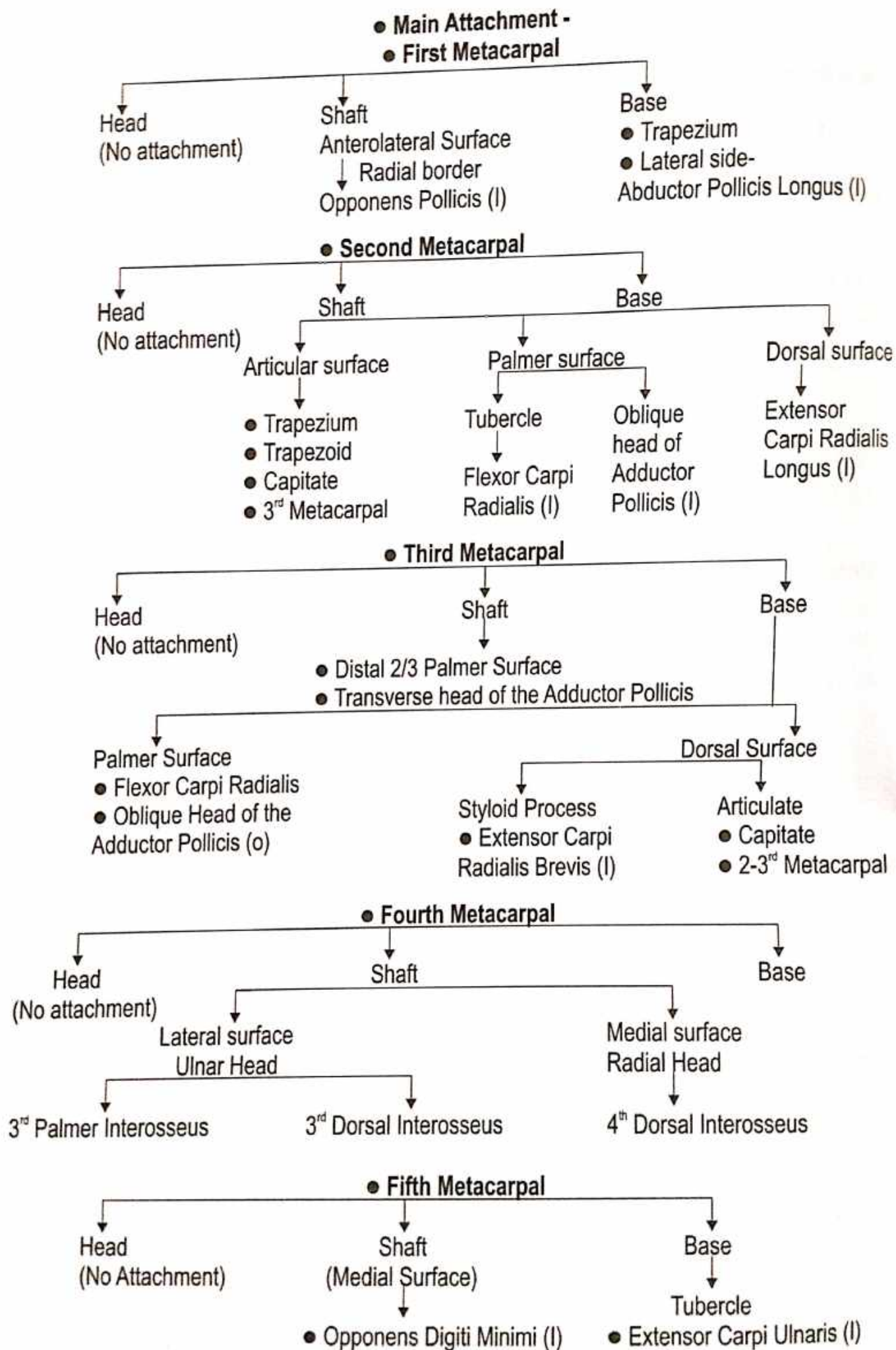


### Side Determination-

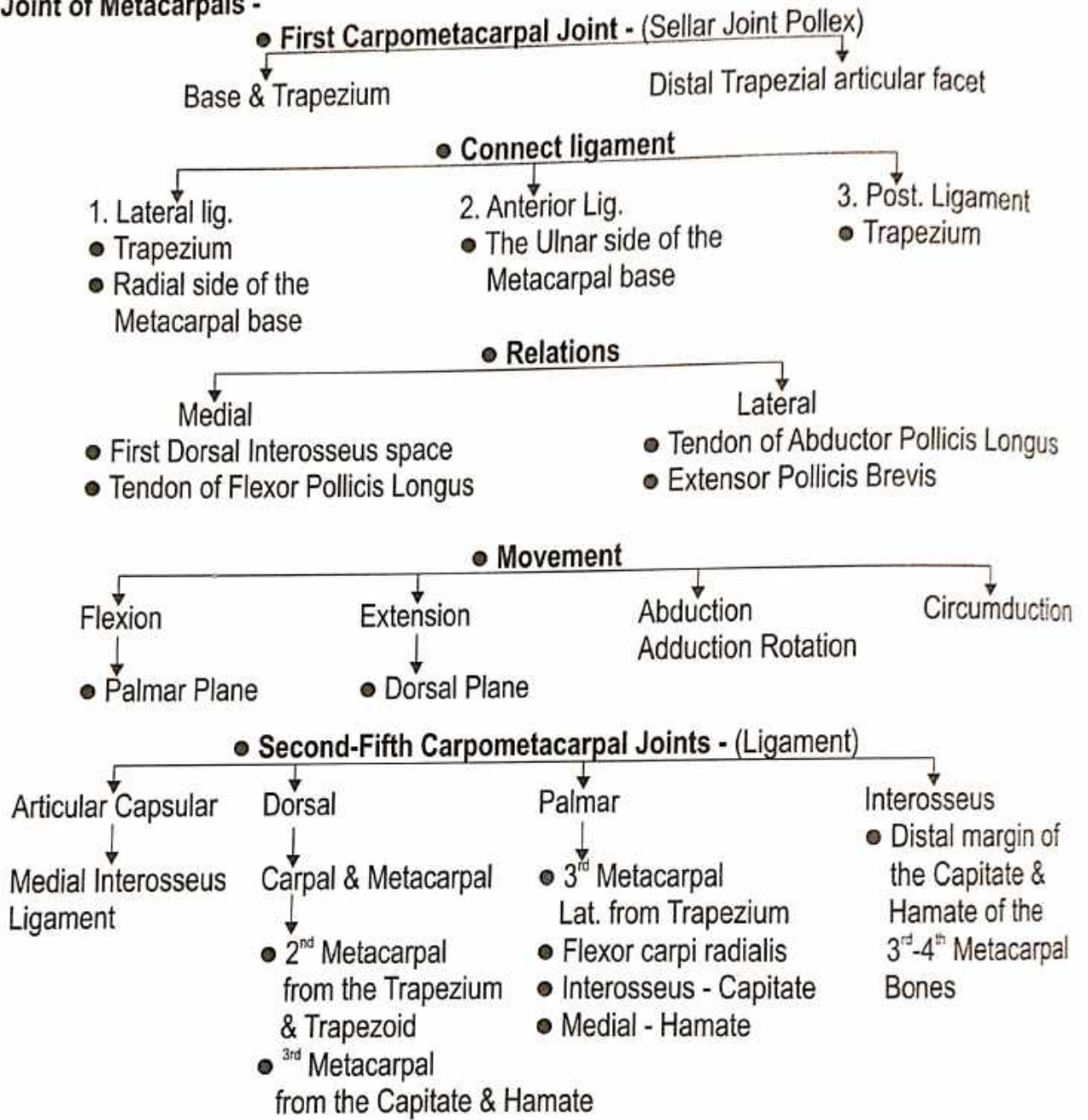
- 1<sup>st</sup> - The Anterolateral Surface is larger than the Anteromedial.
- 2<sup>nd</sup> - The Medial edge of the groove or the base is deeper than the Lateral edge.
- 3<sup>rd</sup> - The Styloid Process is dorsolateral .
- 4<sup>th</sup> - The Lateral side of the base has two small oval facets for the 3<sup>rd</sup> Metacarpal.
- 5<sup>th</sup> - (a) The Lateral side of the base has an elongated articular strip for the 4<sup>th</sup> Metacarpal.  
(b) The Medial side of the base is Nonarticular & has a Tubercle.

### Features -

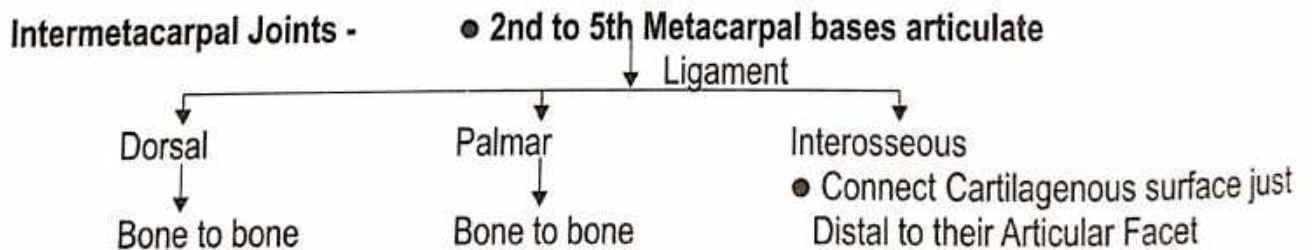




**Joint of Metacarpals -**

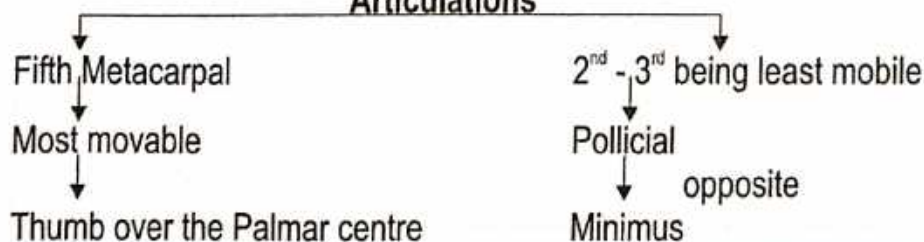


**Intermetacarpal Joints -**



● Synovial Membrane - Carpometacarpal articulation.

● **The Carpometacarpal & Intermetacarpal Articulations**



| Movement            |
|---------------------|
| ● Flexion           |
| ● Abduction         |
| ● Lateral rotation  |
| ● Extension digital |

## PHALANGES

### Name of Bone-

- According to Ayurveda - हस्तांगुली
- According to Modern - Phalanges

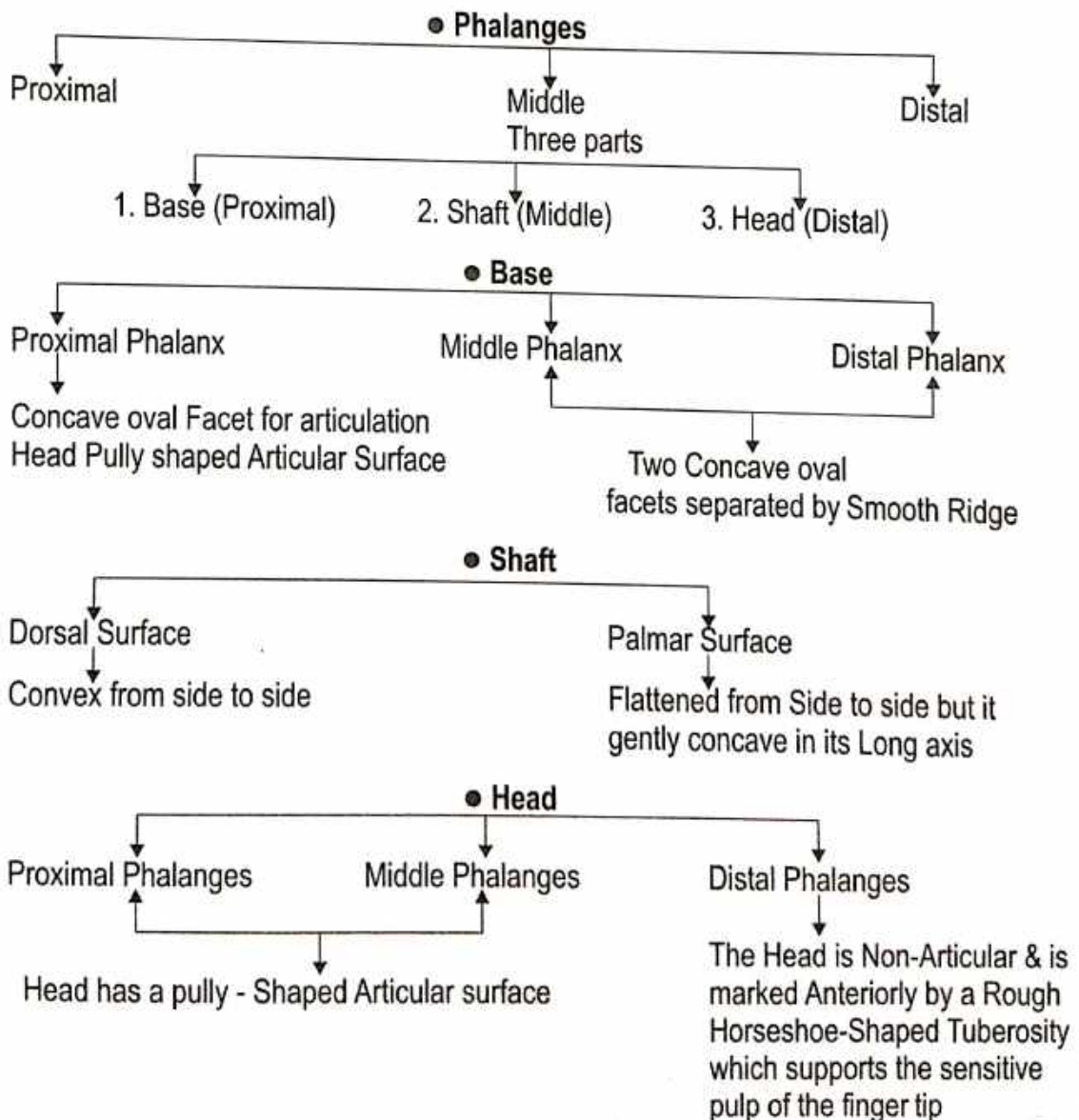
“एकैकस्यां पादाङ्गुल्यां त्रीणि - त्रीणि तानि पञ्चदश”


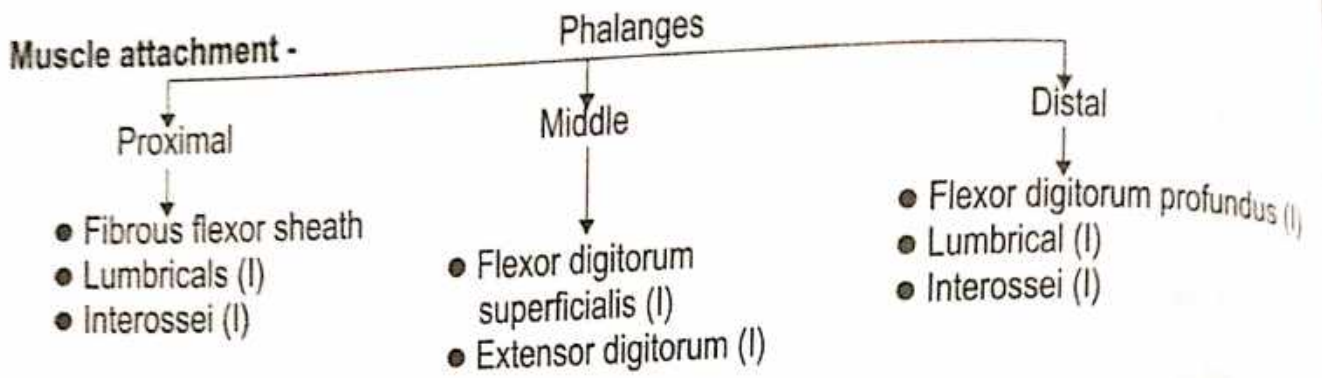
(सु.शा. 5/19)

- महर्षि सुश्रुत ने प्रत्येक अंगुली में 3 अस्थियाँ बताकर पांचों अंगुलियों में 15 अस्थियों की परिगणना किया है ।
- शलाकास्थि को भी अंगुलास्थि में परिगणित किया है जबकि अंगुष्ठ में दो ही अस्थि होती है ।

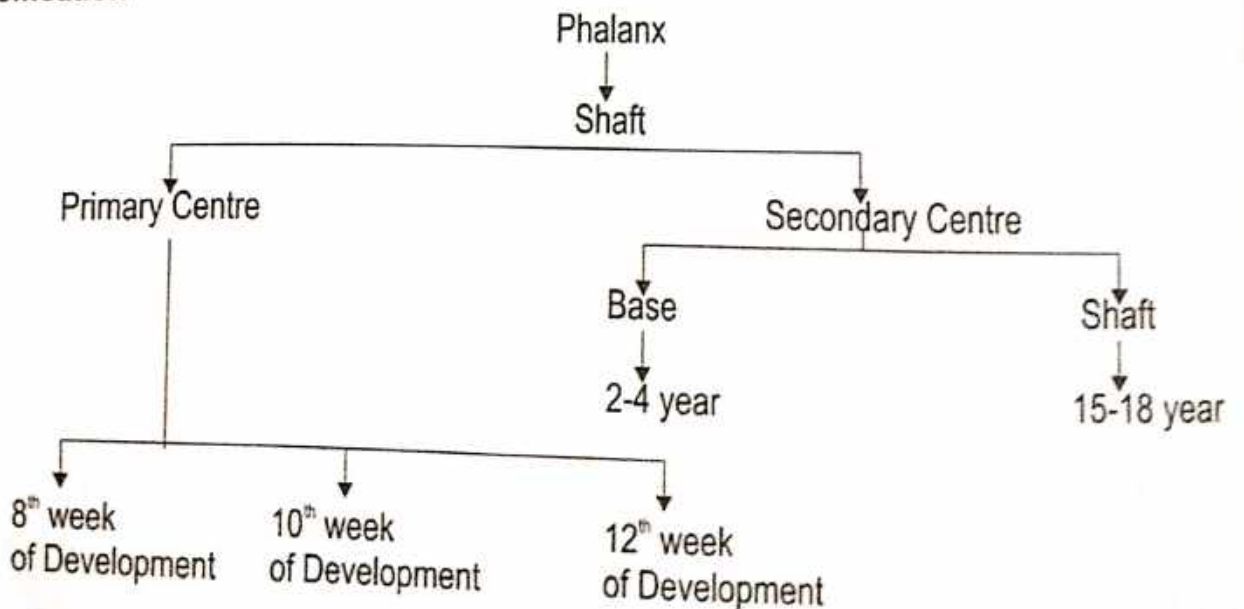
### Number - 14 Phalanges

- 3 for each Finger (Proximal, Middle, Distal)
- 2 for the Thumb (Proximal, Distal)





**Ossification -**



# LOWER LIMB

## HIP BONE

### Name of Bone :

- According to Ayurveda - श्रोणि फलक
- According to Modern - Hip Bone

### Type of Bone :

- According to Ayurveda - कपालास्थि
- According to Modern - Irregular Bone

**Position :** Obliquely between thigh to Waist.

**Ossification :** Cartilagenous

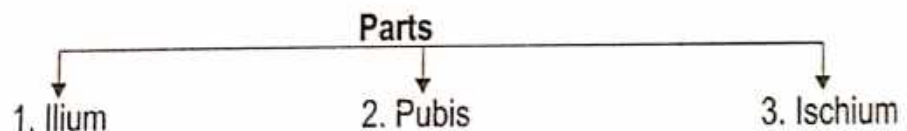
Primary Centre - 3

Secondary Centre - 5

### Side Determination :

- Superiorly - Iliac Crest
- Anteroinferiorly - Pubic Symphysis
- Posteroinferiorly - Ischial Tuberosity
- Laterally - Acetabulum

### Features



## 1. THE ILIUM

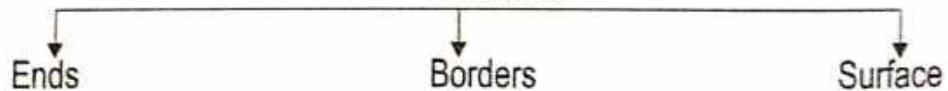
### Name of Bone :

- According to Ayurveda - जघन कपालास्थि
- According to Modern - Ilium

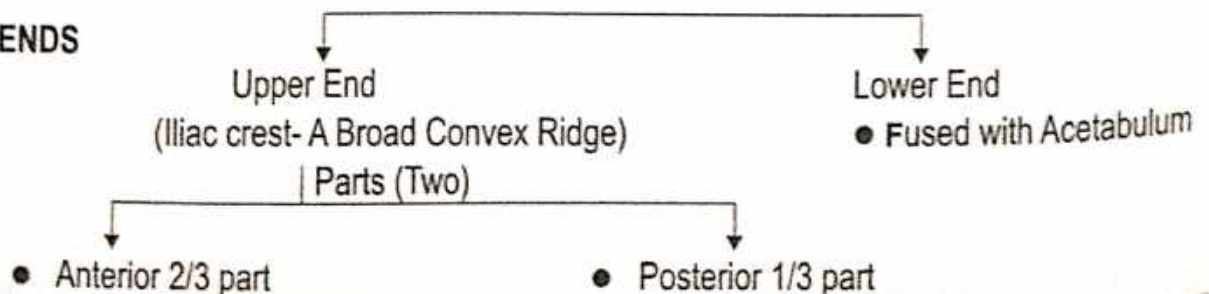
**Position :** Above the Acetabulum.

**Shape :** Plate like.

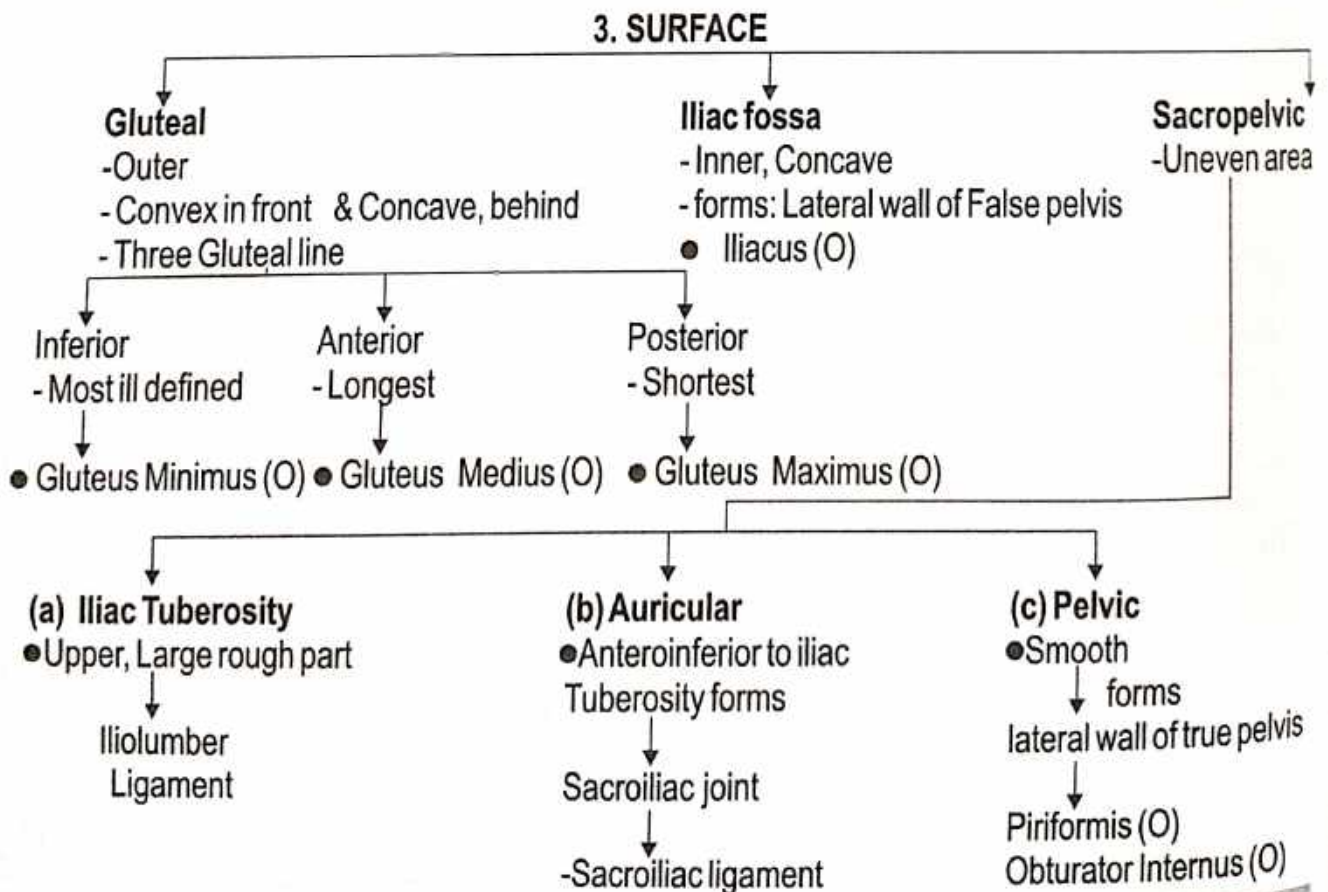
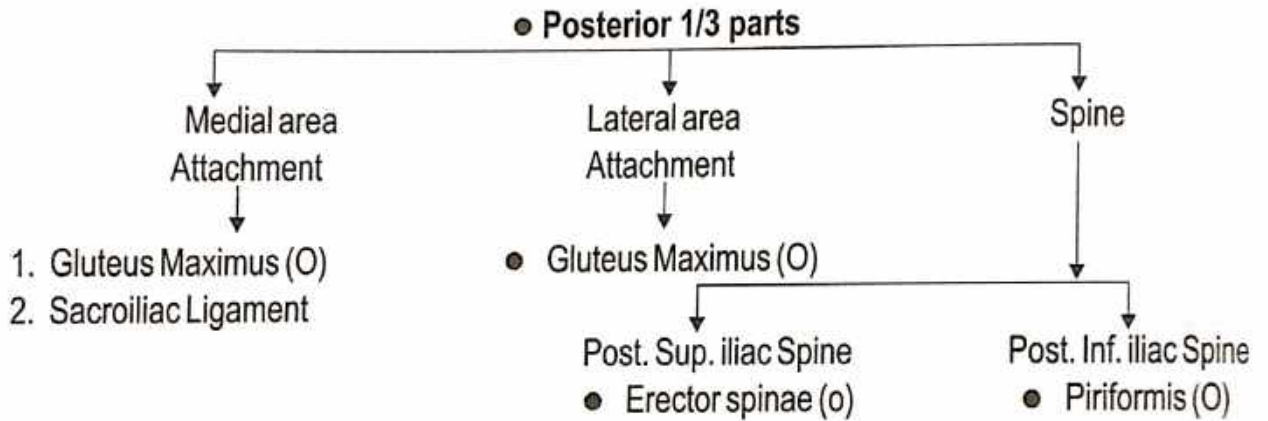
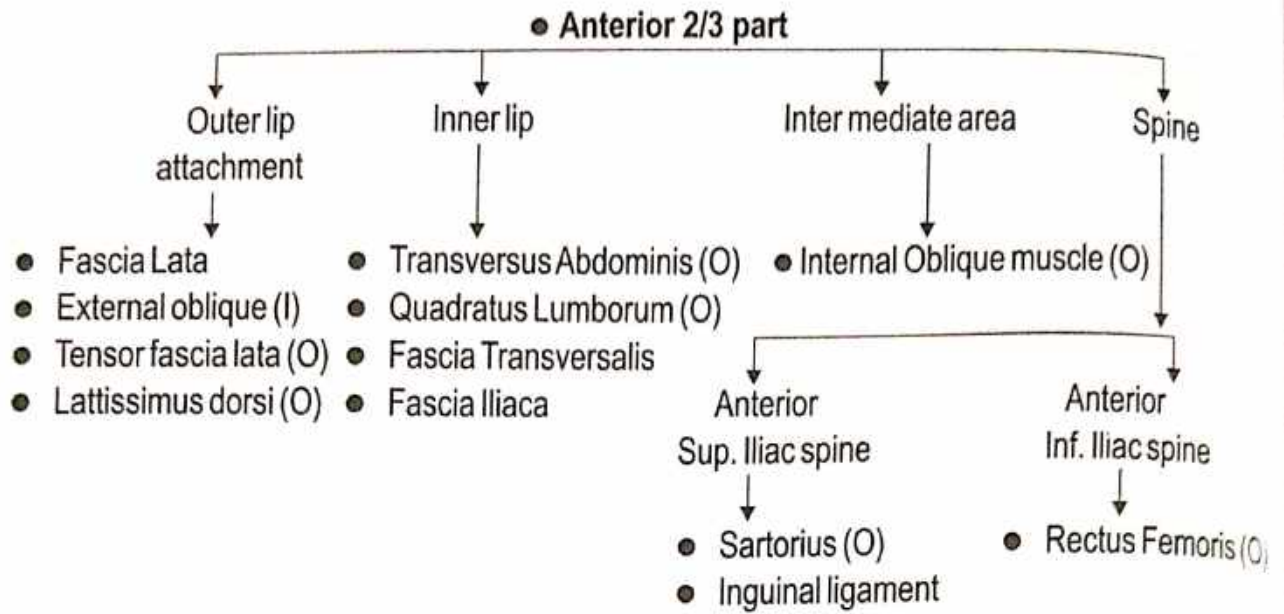
### Features

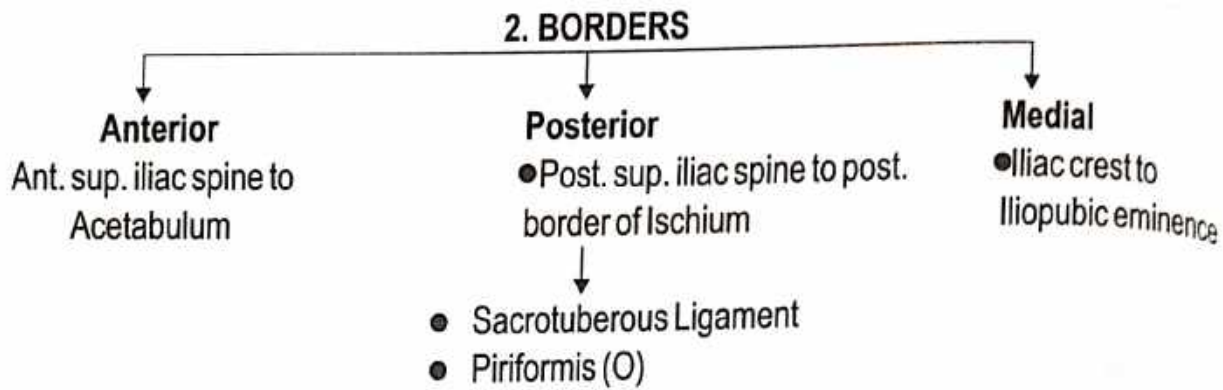


### 1. ENDS







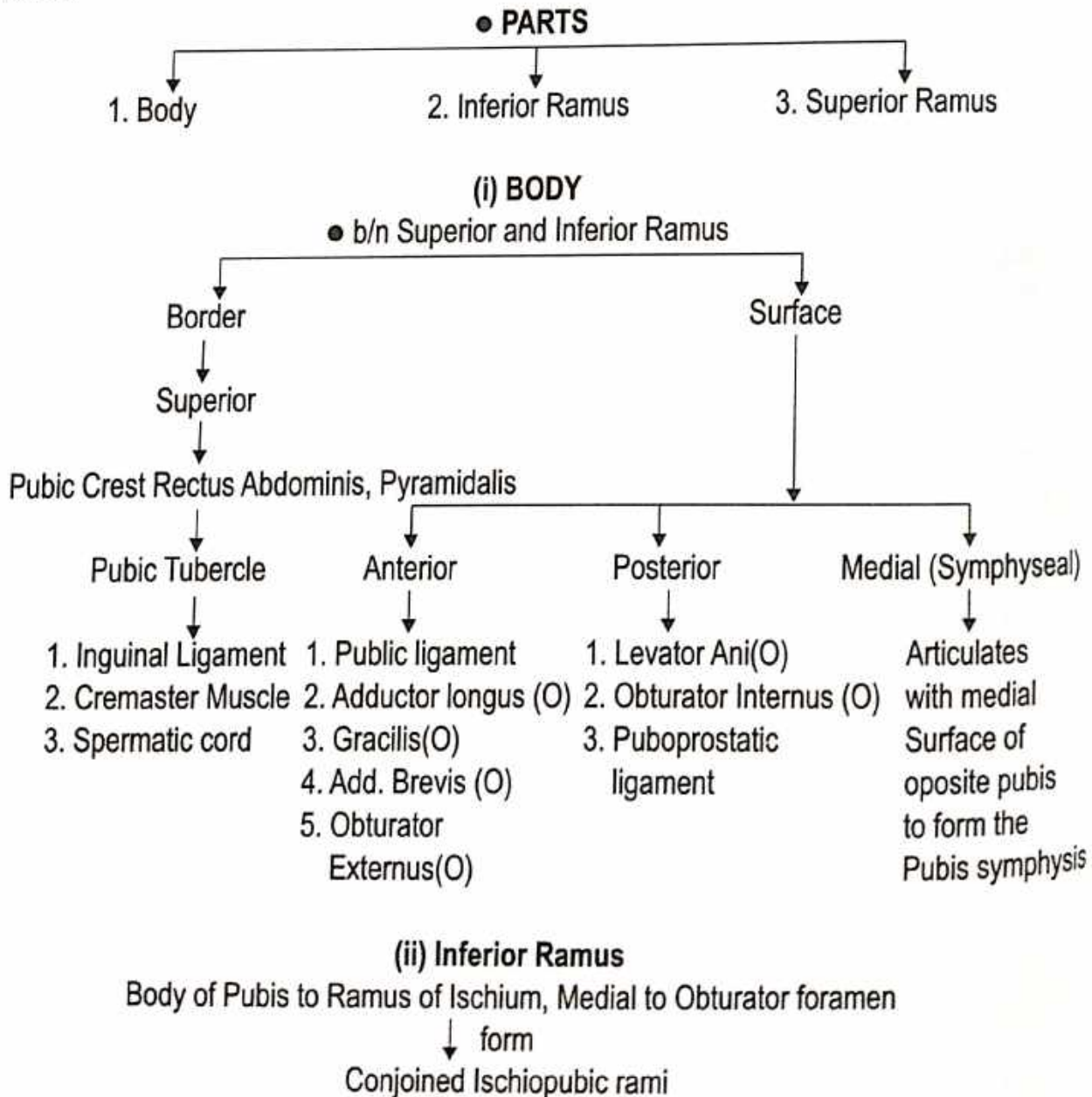


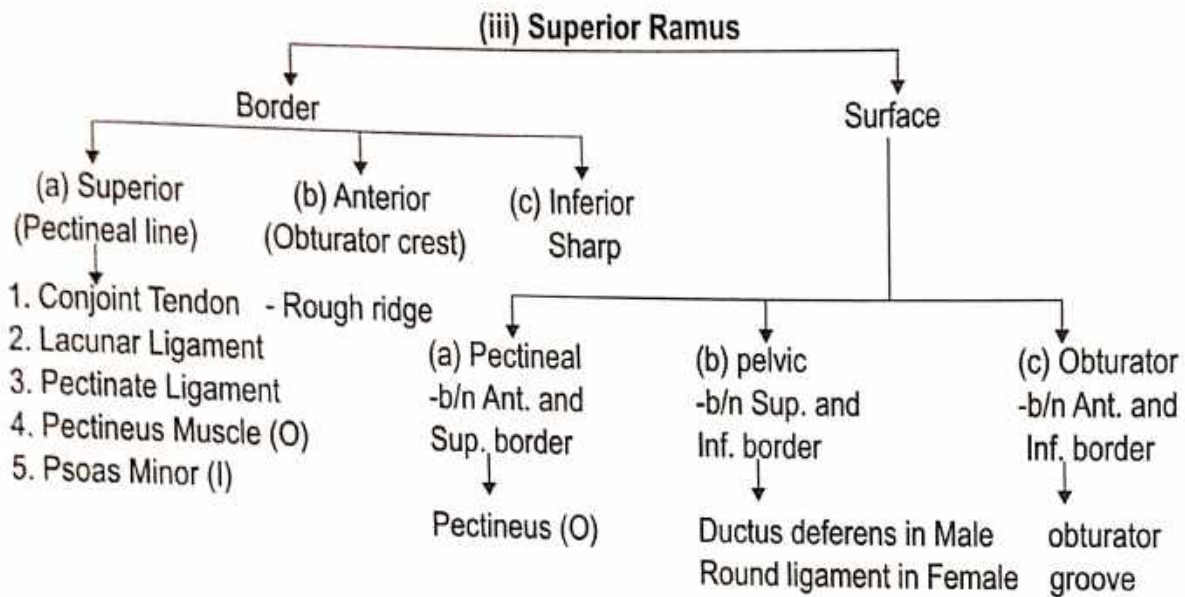
## 2. THE PUBIS

### Name of Bone :

- According to Ayurveda - भग्गस्थि
- According to Modern - Pubis

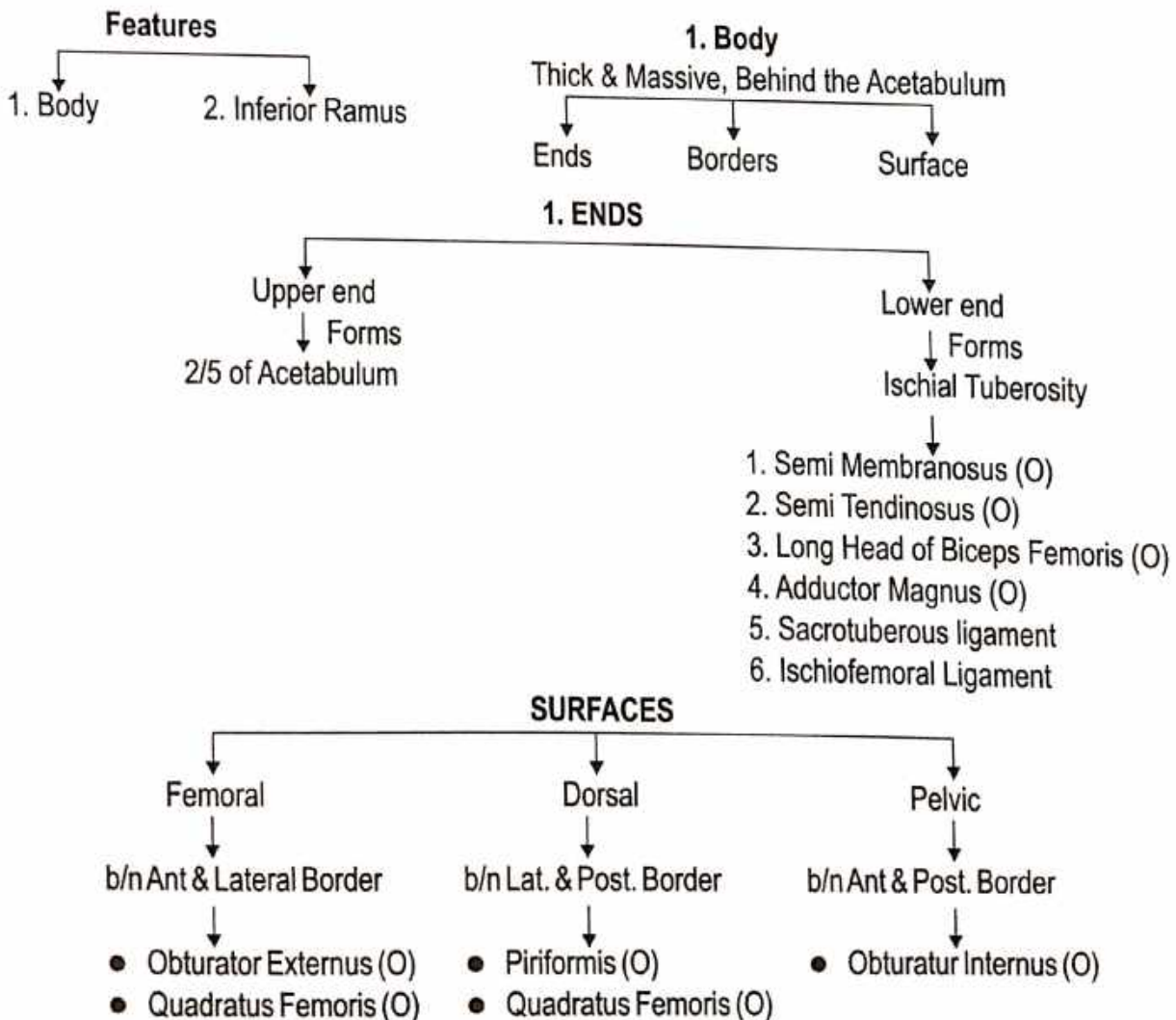
### Features :



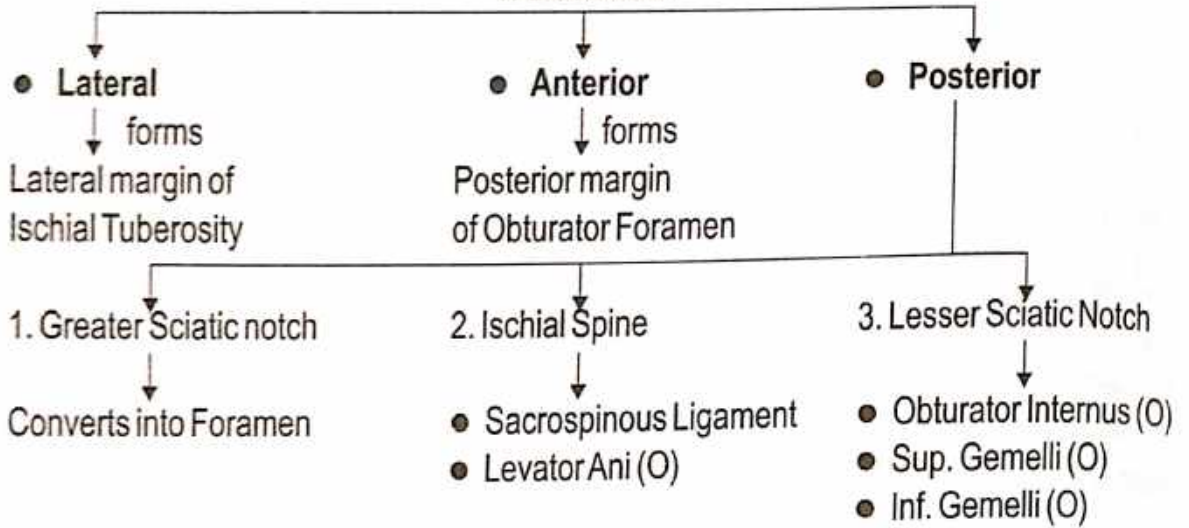


### 3. THE ISCHIUM

- Name of bone :**
- According to Ayurveda - कुकुन्दरास्थि
  - According to Modern - Ischium

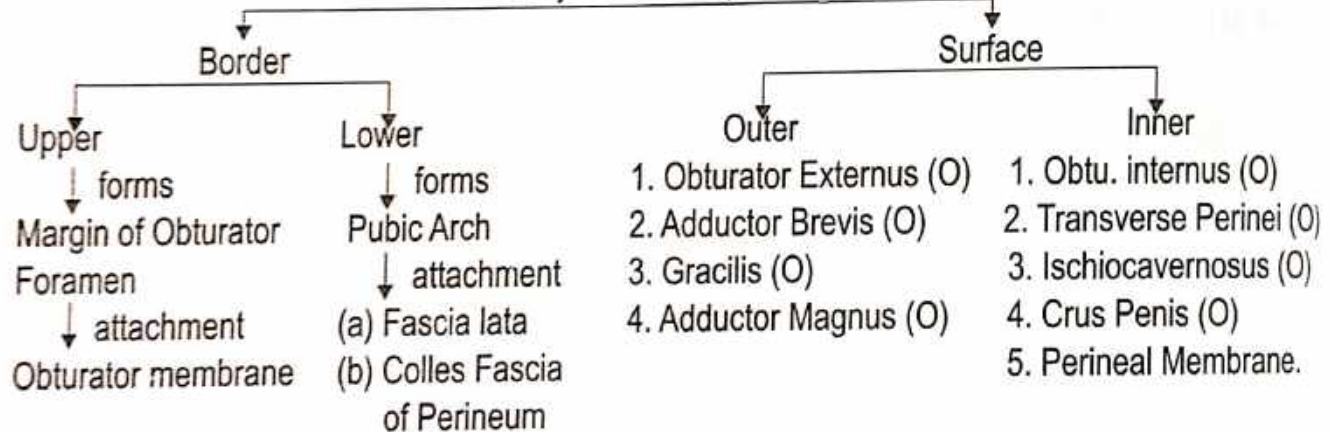


### 1. BORDERS



### (ii) Inferior Ramus

Conjoined Ischiopubic rami

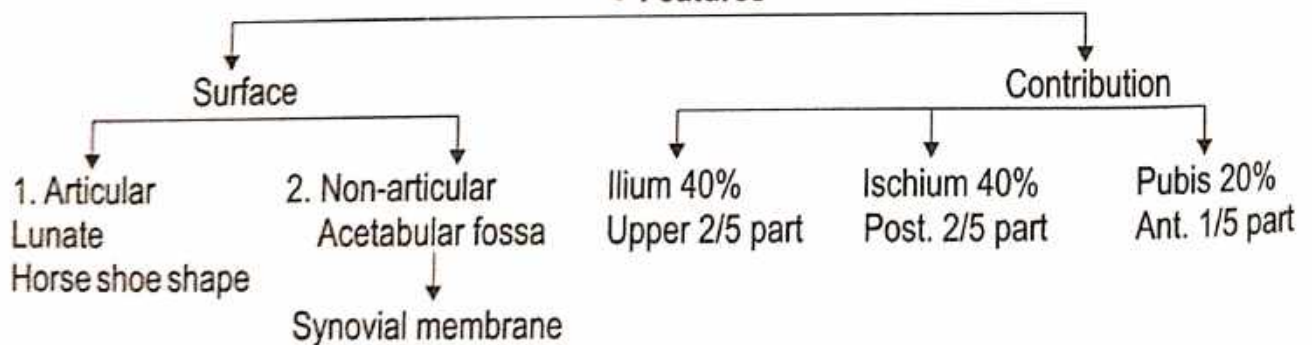


### ● THE ACETABULUM

- A large deep cup shaped hemispherical Cavity

↓ forms  
Hip-joint with the Head of Femur

### ● Features



### ● OBTURATOR FORAMEN

- A Large opening
- Anteroinferior to Acetabulum b/n Pubis and Ischium.
- Large and oval in Males
- Small and triangular in Females.

● **Contents** - Obturator vessels & nerves

# FEMUR

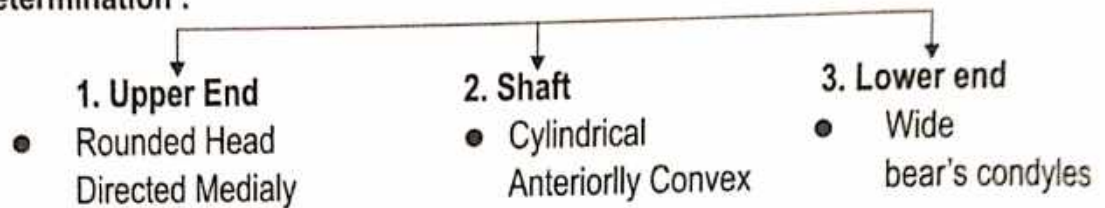
**Name of Bone :** ● According to Ayurveda - ऊर्वस्थि

**Position :** ● According to Ayurveda - ऊरु प्रदेश  
● According to Modern - Thigh Region

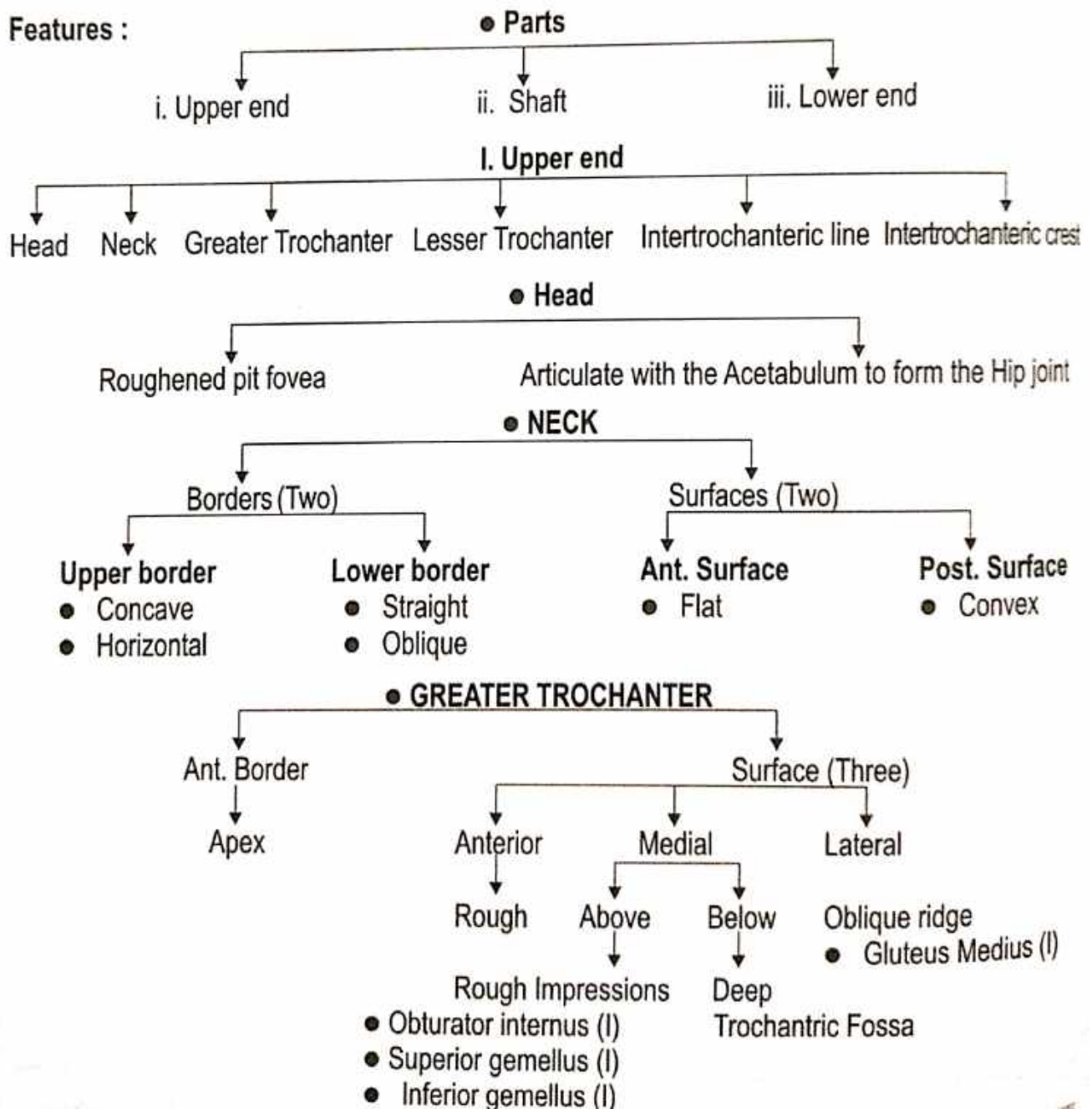
**Type of Bone :** ● According to Ayurveda - नलकास्थि  
● According to Modern - Long Bone

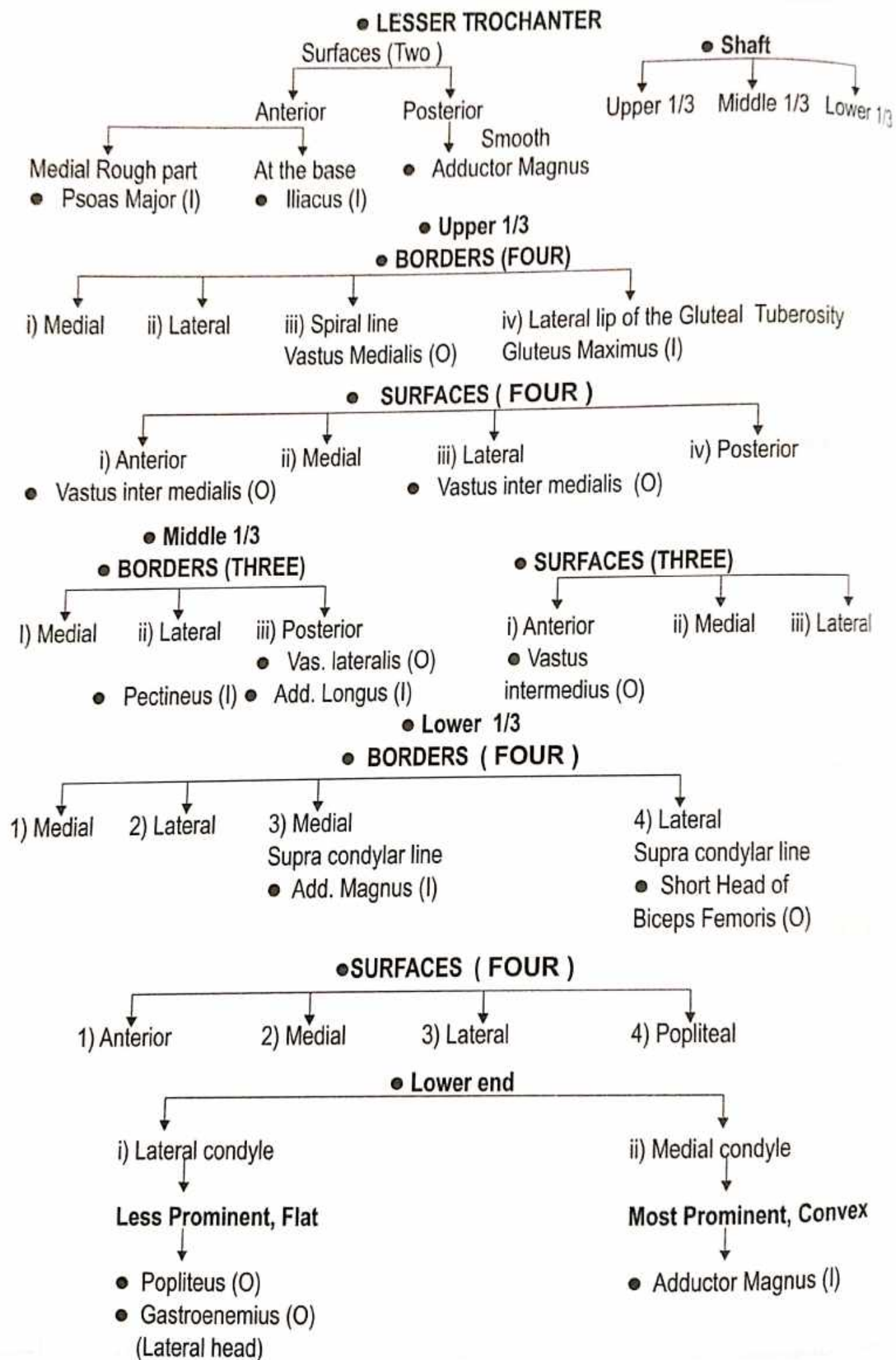
**Ossification :** ● Primary Centre - 1 ● Secondary Centre - 4

**Side Determination :**



**Features :**





## Patella

- Name of Bone :**
- According to Ayurveda - ज्ञान्वस्थि
  - According to Modern - Patella

- Introduction :**
- The Largest Sesamoid Bone in the Body.
  - It is Sesamoid Bone that develops in the tendon of the Quadriceps Femoris muscles.

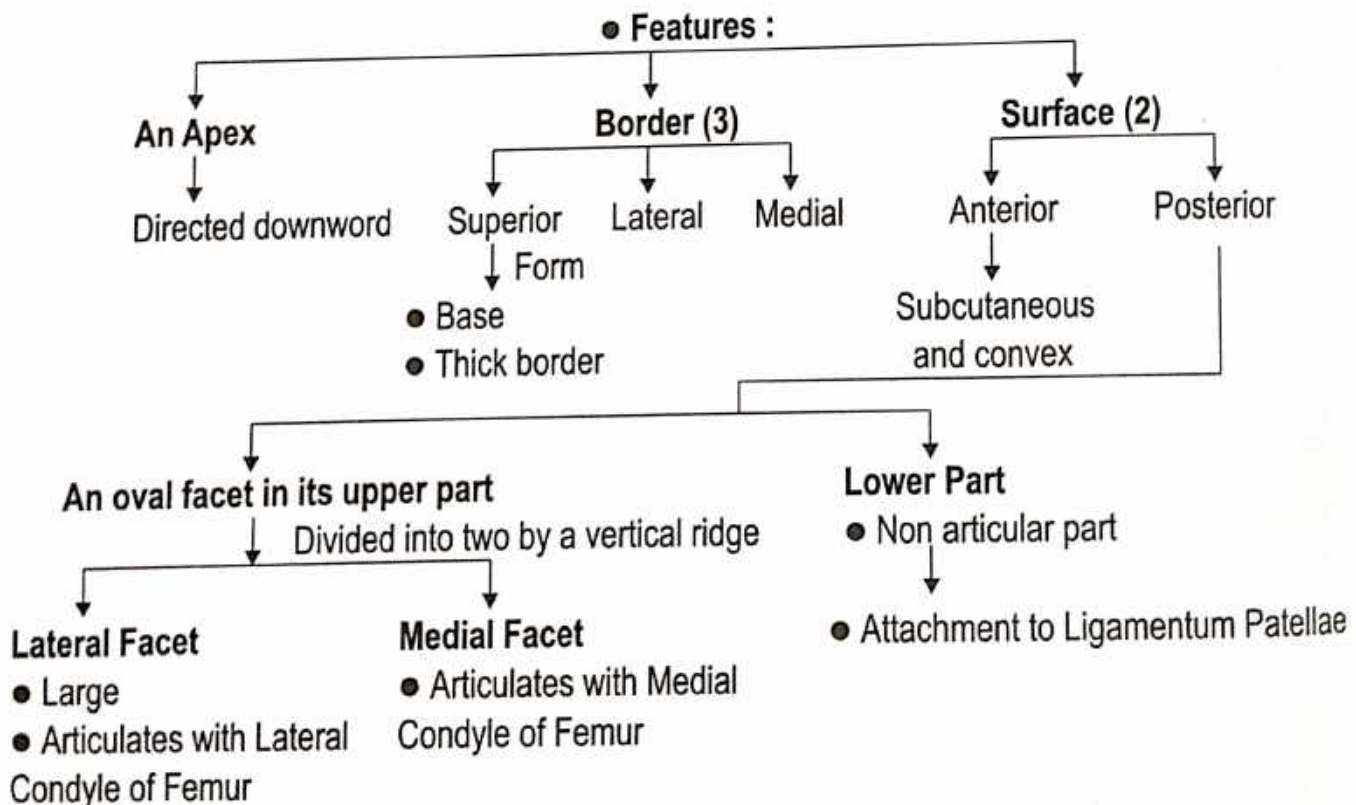
**Shape :** Small triangular bone and is flattened from before backwards.

**Situation :** It is located anteriorly to the Knee Joint.

- Type of Bone :**
- According to Ayurveda - कपालास्थि
  - According to Modern - Flat Bone

**Ossification centre :** From multiple centres

- Side Determination :**
- Pointed apex lies inferiorly.
  - Anterior surface is rough.
  - Lateral facet on the posterior surface is larger and deeper than medial facet.



### ● Attachment on the Patella

- |  |   |   |
|--|---|---|
| <p><b>Superior Border</b></p> <ul style="list-style-type: none"> <li>● In front Rectus Femoris (I)</li> <li>● Behind Vastus Intermedius (I)</li> </ul> | <p><b>Lateral Border</b></p> <ul style="list-style-type: none"> <li>● Vastus Lateralis (I)</li> </ul> | <p><b>Medial Border</b></p> <ul style="list-style-type: none"> <li>● Vastus Medialis (I)</li> </ul> |
|--|---|---|

- Clinical Anatomy -**
- Lateral dislocation of the patella.
  - Bursitis Occurs in prepatellar and subcutaneous infrapatellar bursa.

## TIBIA

### Name of Bone :


- According to Ayurveda - अर्तजंघास्थि
- According to Modern - Tibia

**Position :** Medial bone of the leg

### Type of Bone :

- According to Ayurveda - नलकास्थि
- According to Modern - Long Bone

### Ossification centre :



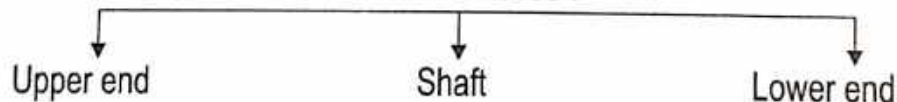
### Peculiarities :

- Second largest Bone of the body.
- It is also called shin Bone.
- The Tibia is the Medial and larger Bone of leg.

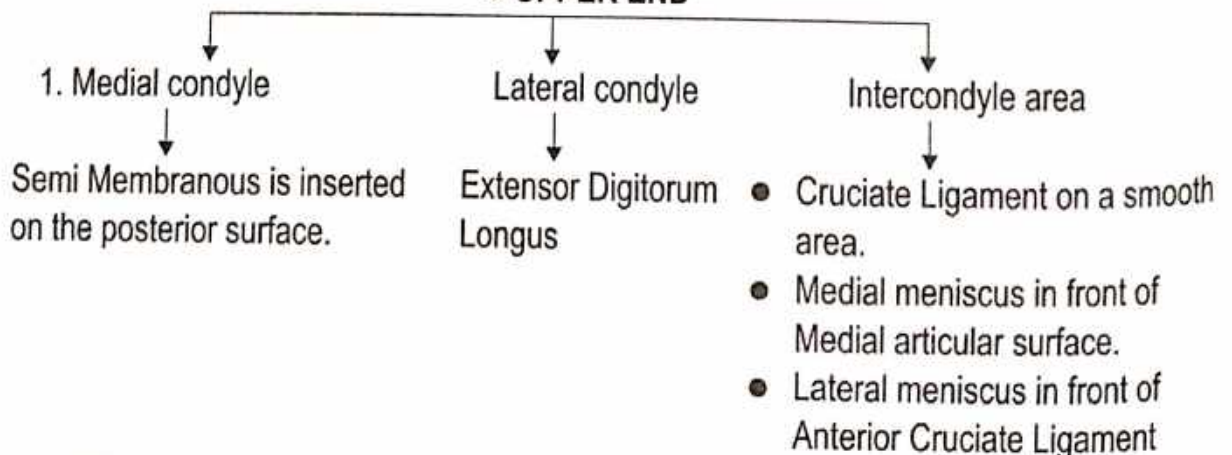
### Side Determination :

1. The upper end is much larger than the lower end.
2. The medial side of the lower end project downwards beyond the rest of the bone. Projection is called as "Medial Malleolus".
3. Ant. Border of shaft is most prominent & Crest like .

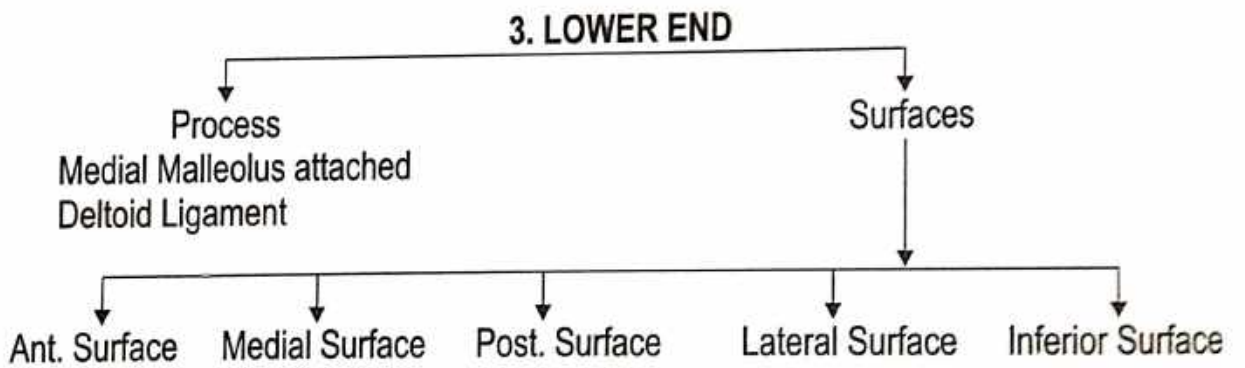
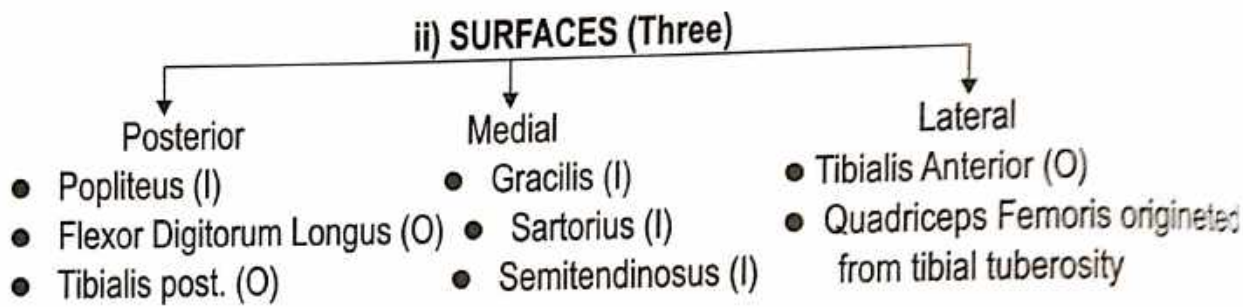
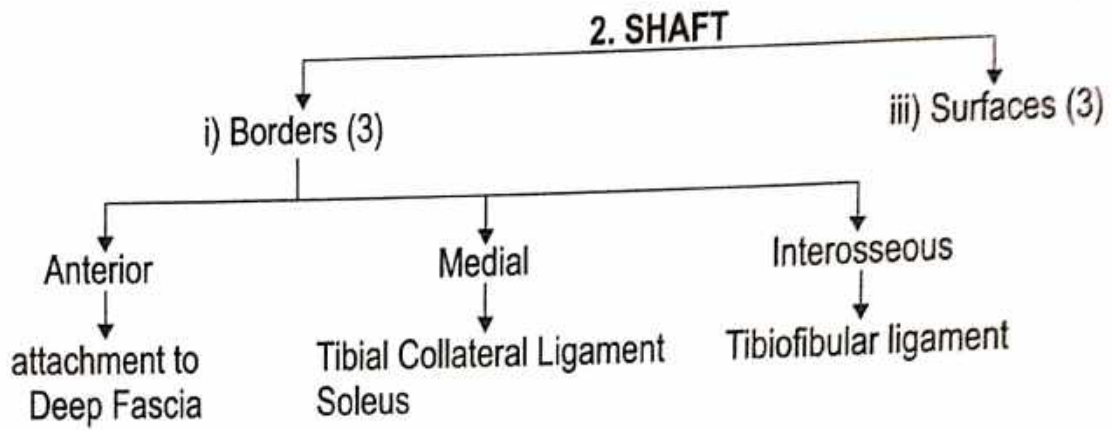
### ● Features :



### ● UPPER END







## FIBULA

**Name of the Bone :**

- According to Ayurveda - बर्हिजंघ्रास्थि
- According to Modern - Fibula

**Situation :** Lateral bone of the leg.

**Shape :** Thin bone

**Type of Bone :**

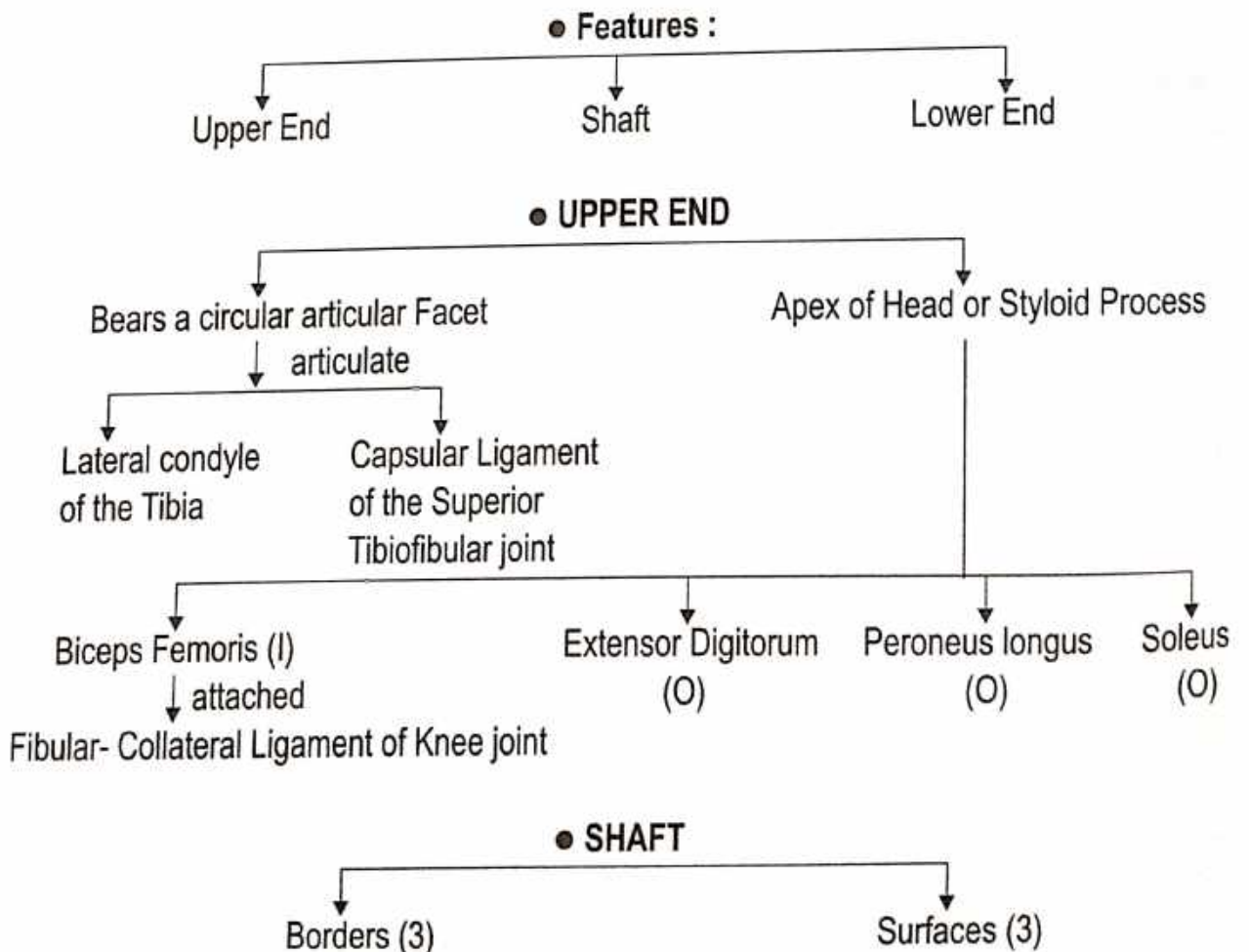
- According to Ayurveda - नलकास्थि
- According to Modern - Long Bone


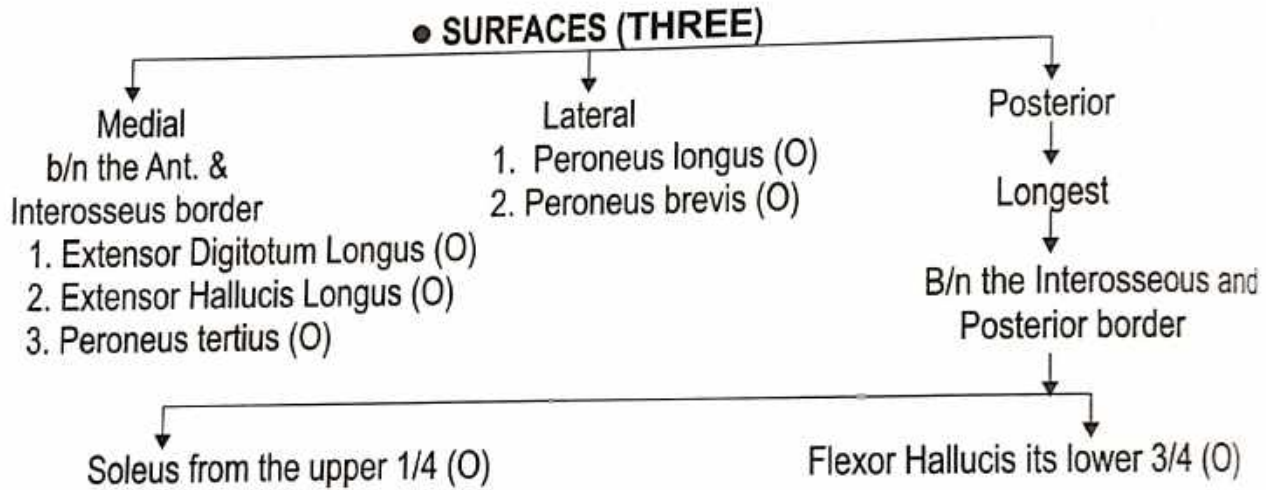
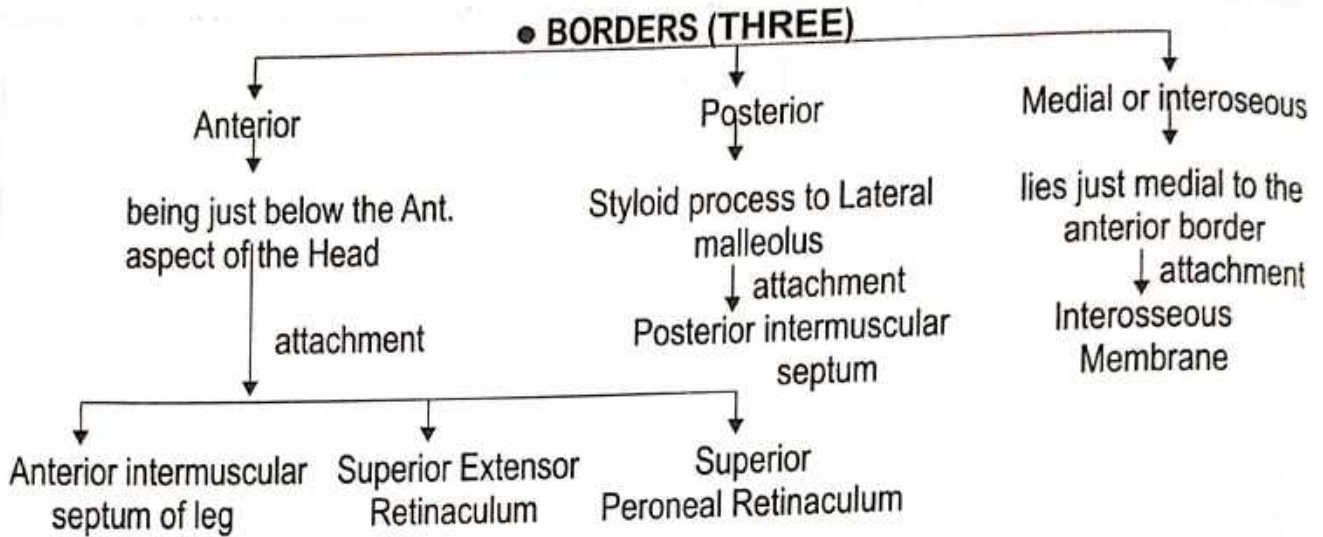
**Ossification centre :**

- Primary Centre - 1
- Secondary Centre-2

**Side Determination :**

1. All directions - upper end or Head
2. Anteroposteriorly - lower end or Lateral Malleolus.
3. Anteriorly - The Medial Side of the Lower end
4. Posteriorly - Malleolar Fossa.





**• BLOOD SUPPLY -**

Peroneal artery  
↓ enters  
Posterior surface

## TARSAL

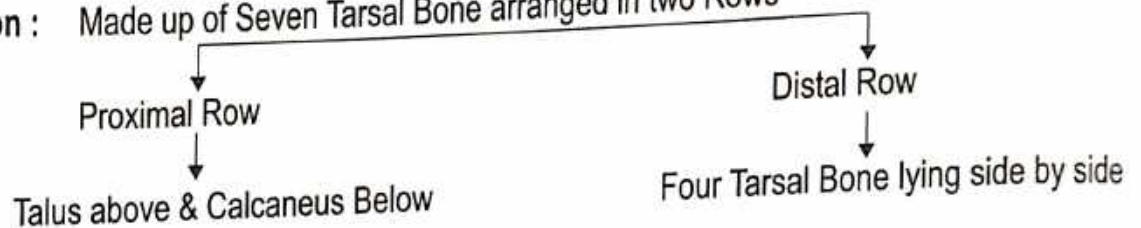
### Name of the Bone :

- According to Ayurveda - पाद गुल्फ
- According to Modern - Tarsal

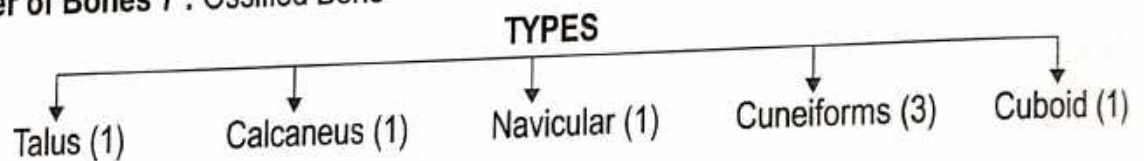
### Type of Bone :

- According to Ayurveda - लघु अस्थि
- According to Modern - Short Bone

**Position :** Made up of Seven Tarsal Bone arranged in two Rows



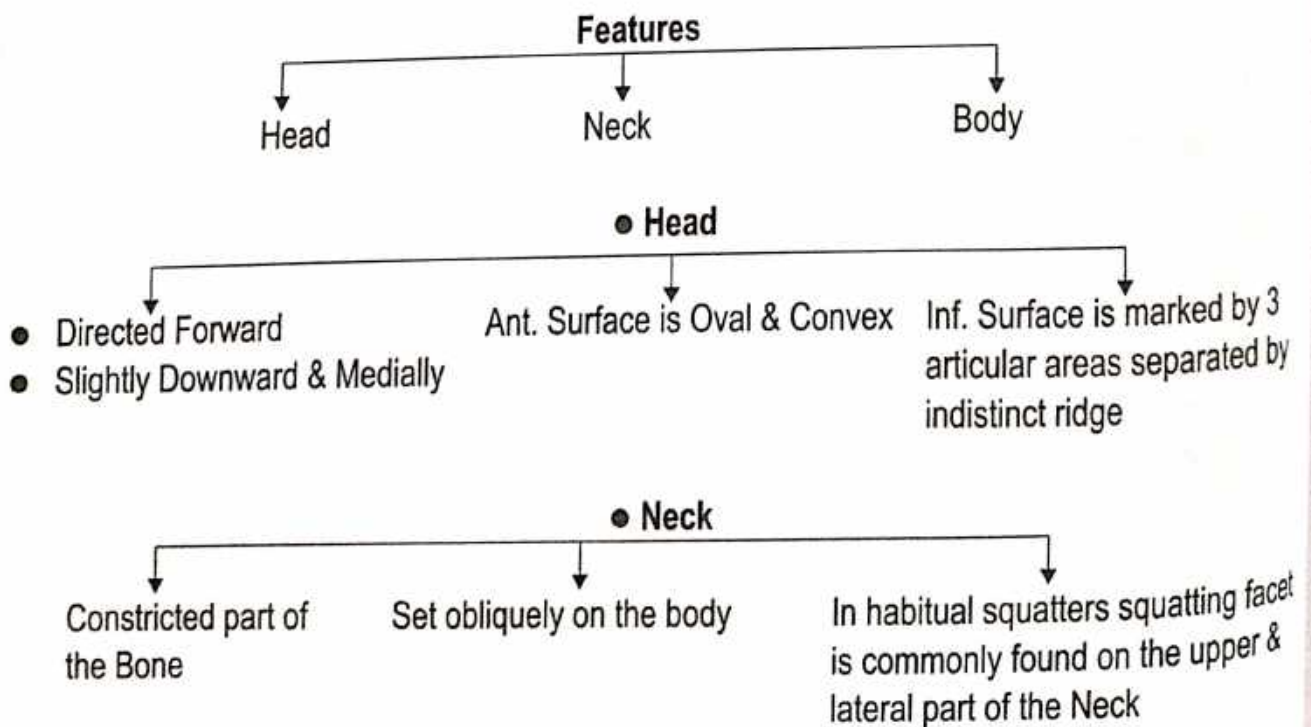
**Number of Bones 7 : Ossified Bone**

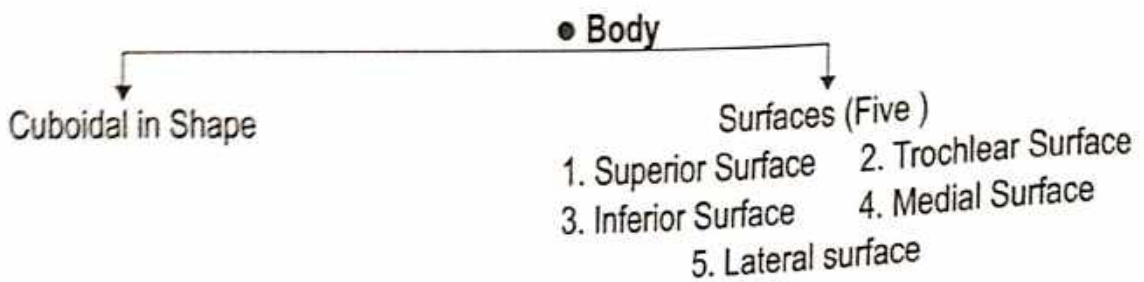


### 1. TALUS (Second largest tarsal bone)

#### Side Determination :

- Rounded head : Directed Forward
- Trochlear articular surface of the body : Upward
- Facet : laterally, A comma shaped facet lies medially.



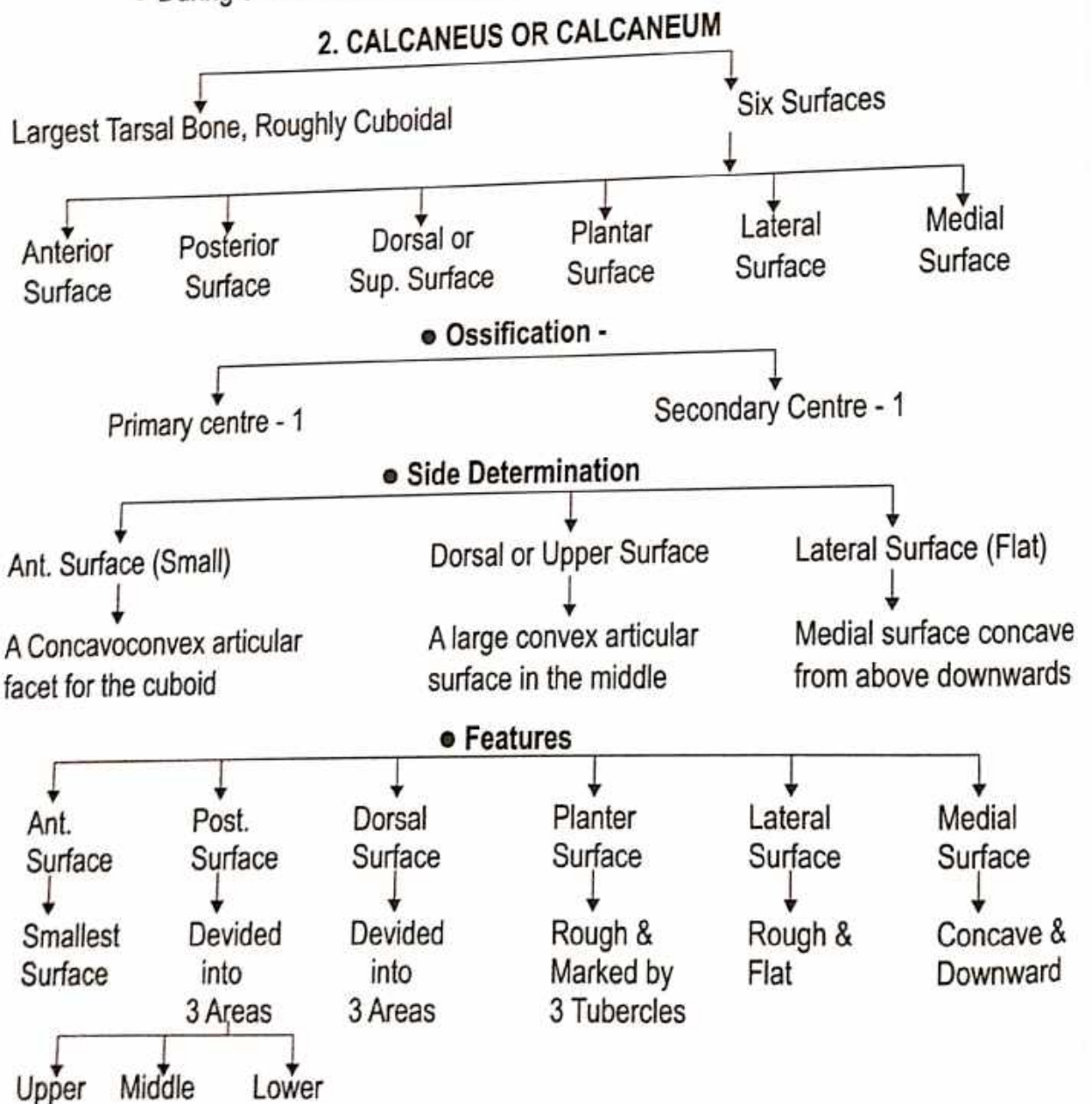


**Attachment on the Talus -**

1. Neck - (a) Distal part of the dorsal surface - Capsular Ligament.  
 (b) Inferior surface - Interosseous Talocalcaneal and Cervical Ligament.  
 (c) Lateral part - Anterior Talofibular Ligament.
2. Medial Surface of the Body - Deep fibres of the Deltoid Ligament.
3. Groove on the Posterior Surface - Tendon of the Flexor Hallucis Longus.


**Ossification - From one Centre**

- During 6<sup>th</sup> month of intrauterine life.



### 3. NAVICULAR BONES

The Navicular bone is Boat shaped.

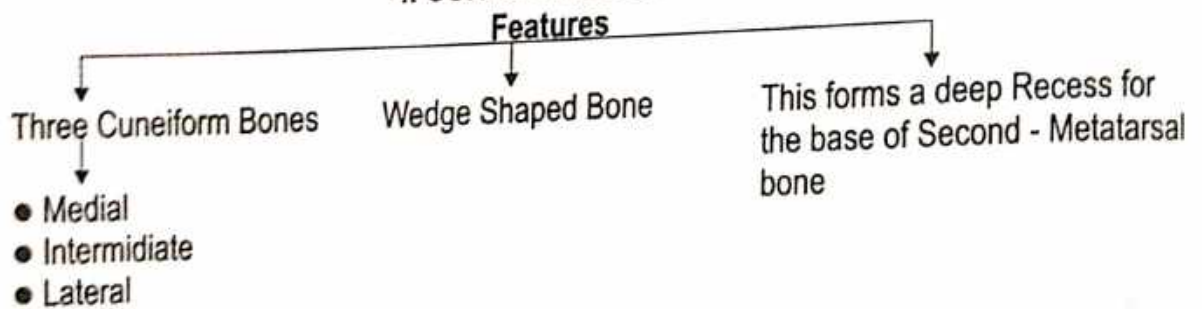


#### Attachment -

1. Tuberosity of the Navicular Bone - Tibialis posterior (I)
2. Planter surface - Spring ligament or planter calcaneonavicular ligament.
3. Lateral surface - Bifurcate ligament.

Ossification - From the centre = During the 3<sup>rd</sup> year of life.


### 4. CUNEIFORM BONES



#### Ossification -

Each Cuneiform bone ossifies from one centre, which appears during the first year in the lateral cuneiform, during the second year in the medial cuneiform, and during the third year in the intermediate cuneiform bone.

### 5. CUBOID (Lateral Bone of the Distal row of the Tarsus)



#### Attachment -

- Peroneus Longus - On the Notch of lateral surface & groove on the plantar surface.  
Long Planter Ligament - Ridge posterior to the groove.  
Short Planter Ligament - Posterior border of the plantar surface.

**Non-articular part** - Ligaments, including the lateral limbs of the bifurcate ligament.

**Ossification** - From the Centre - Appears just before birth.

# METATARSAL

**Name of the Bone :**

- According to Ayurveda - पादशलाका
- According to Modern - Metatarsal

**Type of Bone :**

- According to Ayurveda - नलकास्थि
- According to Modern - Long Bone

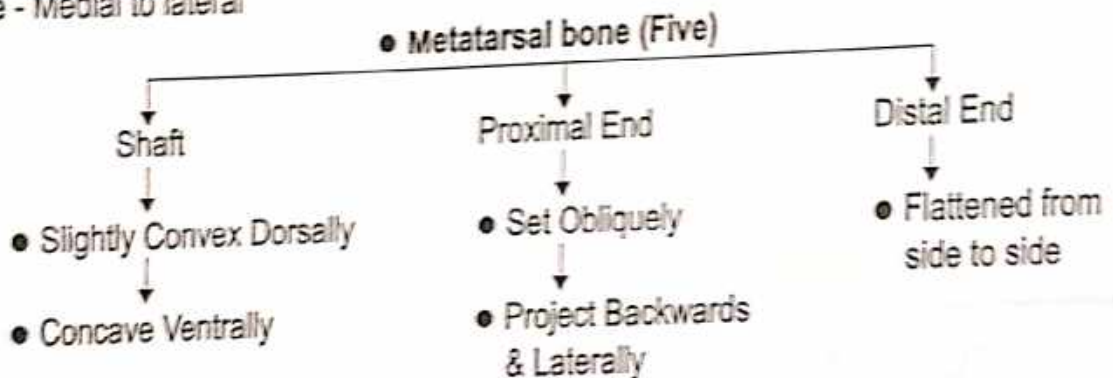
**Position :** B/n Tarsal & Phalanges.

पादशलाकाएँ - चक्रानुसार = 10

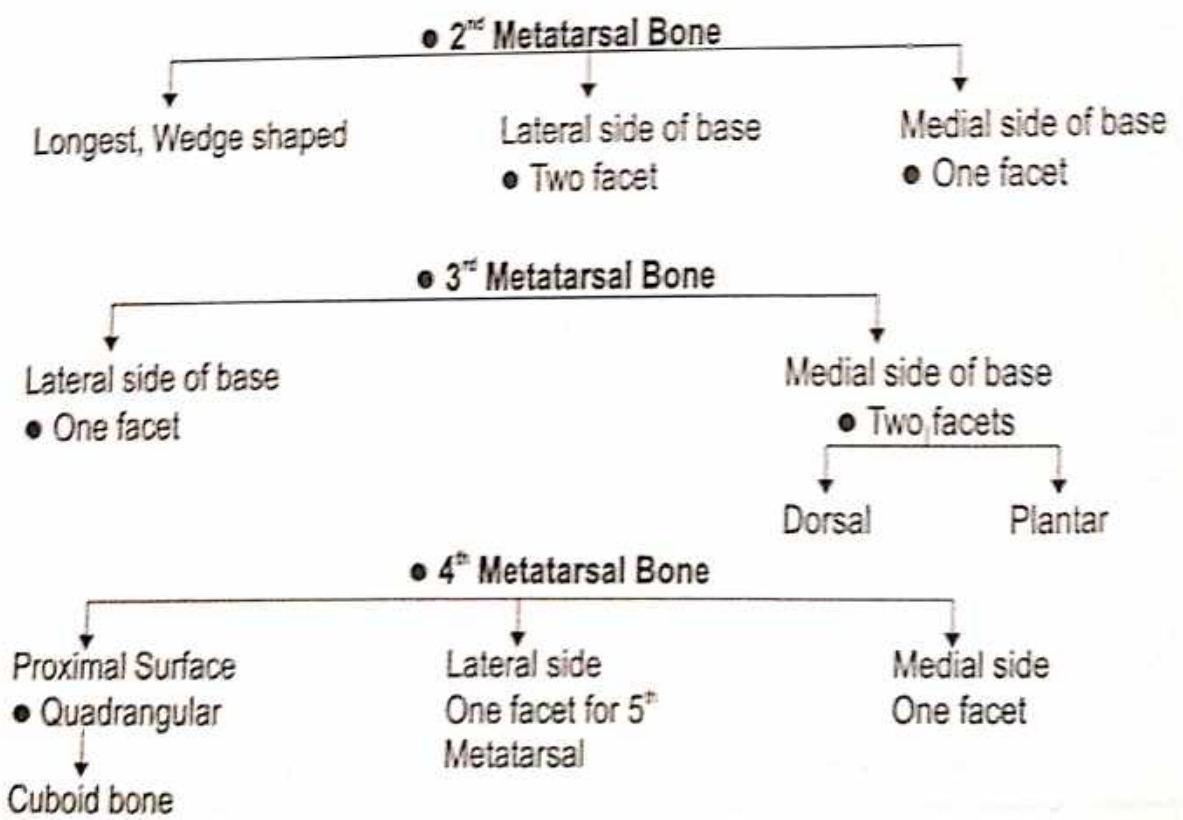
सुश्रुतानुसार = 10

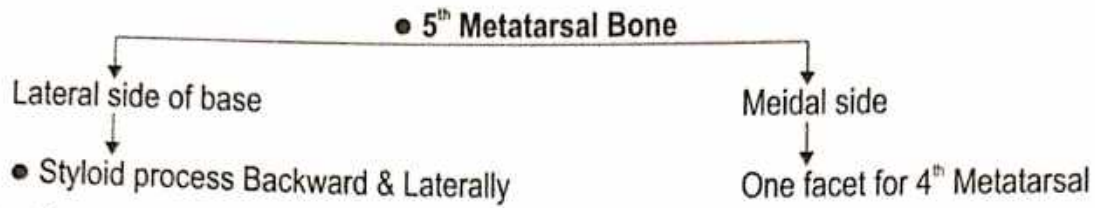
आधुनिक = 10

**Feature - Medial to lateral**



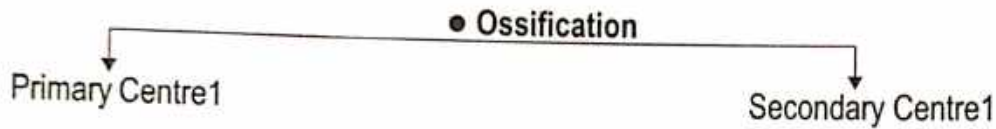
**Identification - First Metatarsal Bone -** ● Shortest and thickest ● For transmission of body weight





**Important Attachment -**

- First Metatarsal - Tibialis Anterior medial side of base.
- Shaft of Metatarsal Bone - Origin of Interosseous
- 5<sup>th</sup> Metatarsal - Peroneus Brevis, inserted on Dorsal Tuberosity.
- 5<sup>th</sup> Metatarsal - Origin of Flexor Digiti Minimi Brevis from Planter Surface.
- 1<sup>st</sup> Metatarsal Bone - Peroneus longus inserted on large impression on inferior angle of Lateral Surface.



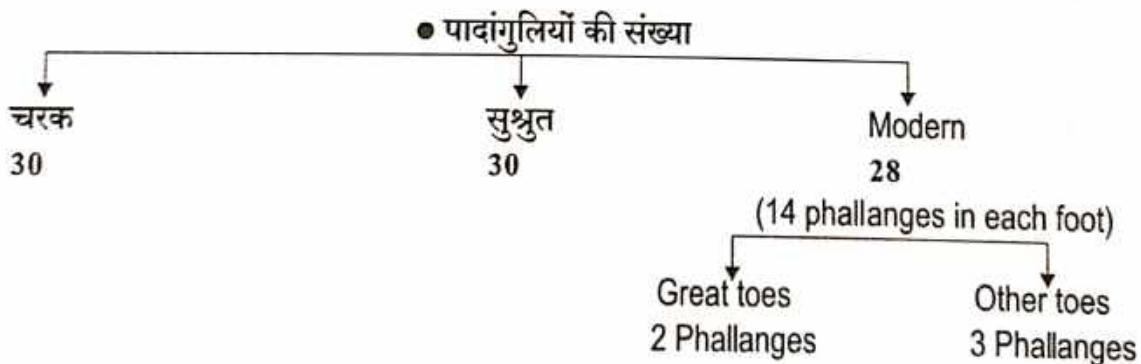
**PHALLANGES**

**Name of the Bone :**

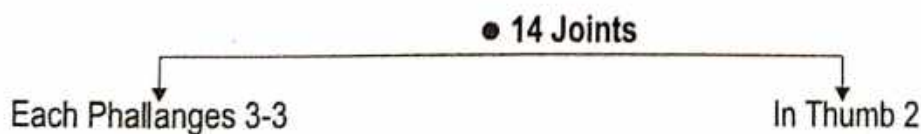
- According to Ayurveda - पादांगुली
- According to Modern - Phallanges

**Type of Bone :**

- According to Ayurveda - नलकास्थि
- According to Modern - Short Bone



● एकैकस्यां तु पादाङ्गुल्यां त्रीणि त्रीणि तानि पञ्चदश । (सु.शा. 5/19)



● एकैकस्यां पादाङ्गुल्यां त्रयस्त्रयः द्वावङ्गुष्ठेते चतुर्दश । (सु.शा. 5/28)



## STERNUM

### Name of Bone-

- According to Ayurveda - उरोस्थि
- According to Modern - Sternum

**Situation** - Medial part of anterior thoracic wall.

### General Features -

Shape - Short sword

Length - Average 17 cms or 7 inches

It is longer in males than in females.

### Type of bone -

A/c to Ayurveda - कपालस्थि

A/c to Modern - Long flat bone

**Ossification** - (Cartilaginous)

- Primary centres-5
- Secondary centres-1

### Side Determination -

1. Upper part Manubrium is quadrilateral in shape.
2. Anterior surface is convex & posterior surface is concave.
3. Lower tapering part - Xiphoid process or Xiphisternum.

### Features -

#### ● Three parts

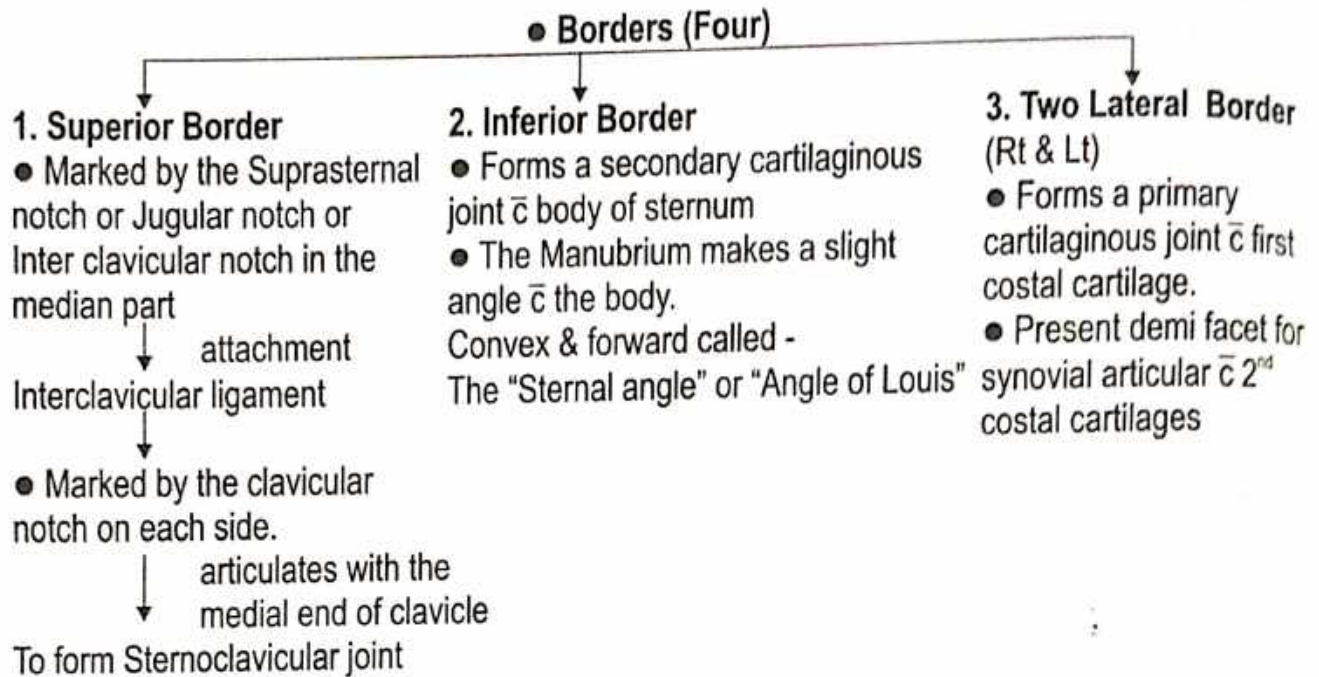
- 1. Manubrium Sterni
- 2. Body
- 3. Xiphoid Process

### 1. Manubrium Sterni

- Quadrilateral in shape.
- Thickest & strongest part of sternum.
- Lies opposite 4<sup>th</sup> Thoracic vertebra.

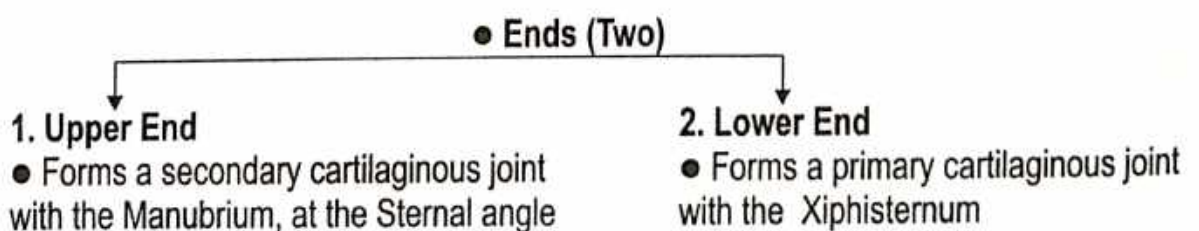
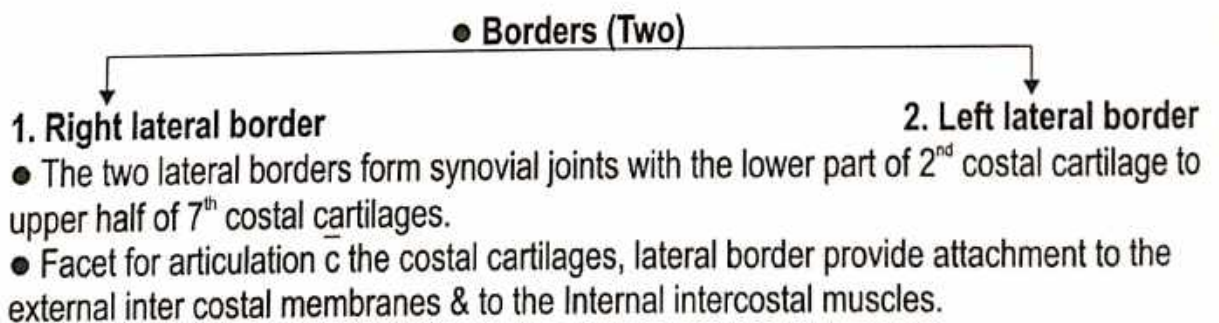

#### ● Surfaces (Two)

- 1. Anterior Surface
    - Pectoralis major (o)
    - Sternocleido mastoid (o)
  - 2. Posterior Surface
    - Sternohyoid in upper part (o)
    - Sternothyroid in lower part (o)
- Relation -  
Arch of aorta & its branches  
Left Brachiocephalic vein



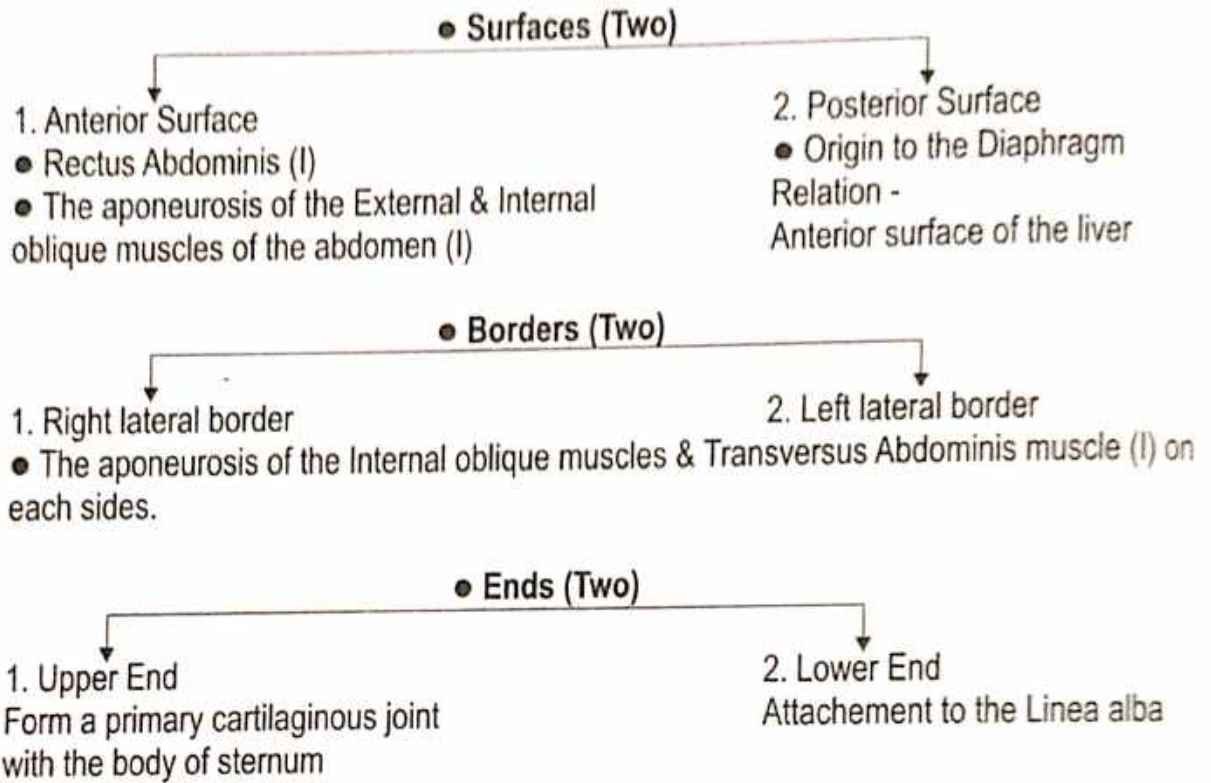
**● BODY OF STERNUM**

- Rectangular in shape.
- Longer, narrower & thinner.
- Lies opposite 5-9<sup>th</sup> Thoracic vertebra.



## ● XIPHOID PROCESS

- Smallest part of sternum.
- Shape is variable, may be bifid or perforated.
- Lies in the floor of the Epigastric fossa.



### **Applied Aspect -**

Funnel Chest - Development anomaly - Sternum is depressed.

Pigeon Chest - Developmental anomaly - Forward projection of sternum.

# RIBS

**Name of Bone-**

- According to Ayurveda- पर्शुका
- According to Modern- Ribs / Costae

**Position -** 1<sup>st</sup> Thoracic vertebra - 12<sup>th</sup> Thoracic vertebra

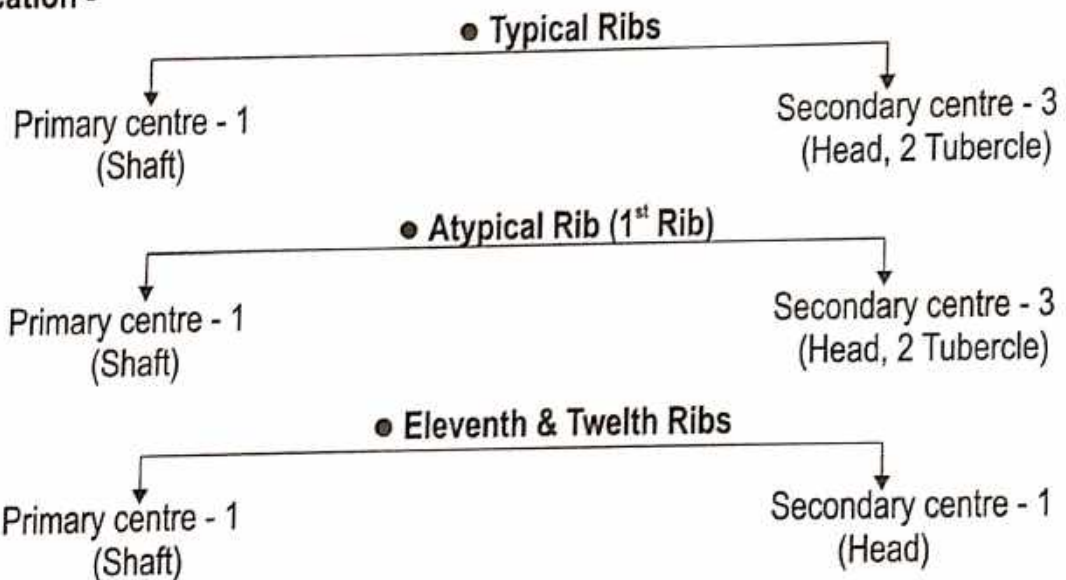
**Type of Bone-**

- According to Ayurveda- चलयस्थि
- According to Modern - Irregular bone

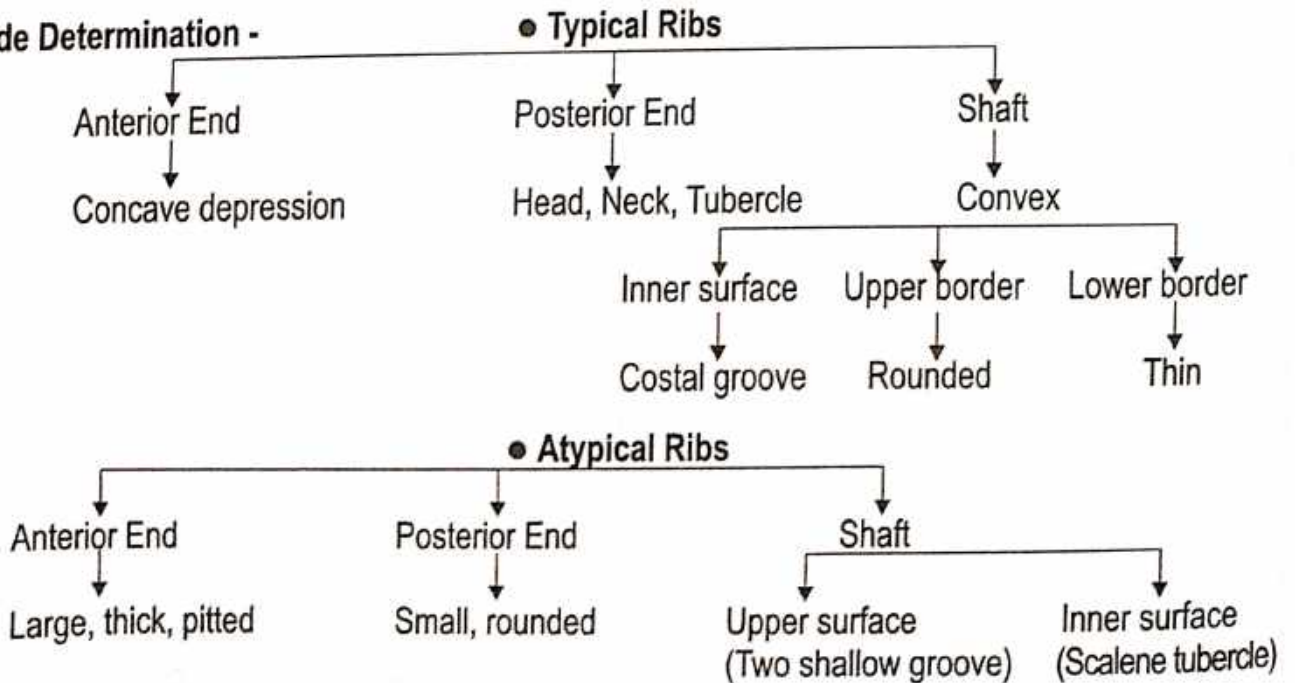
**Type of Rib -**



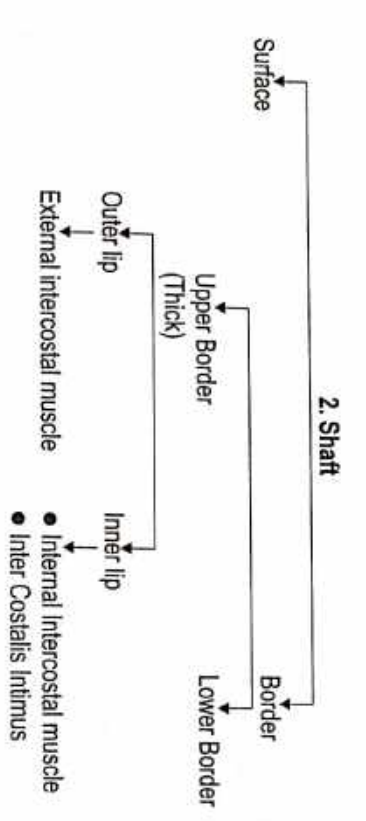
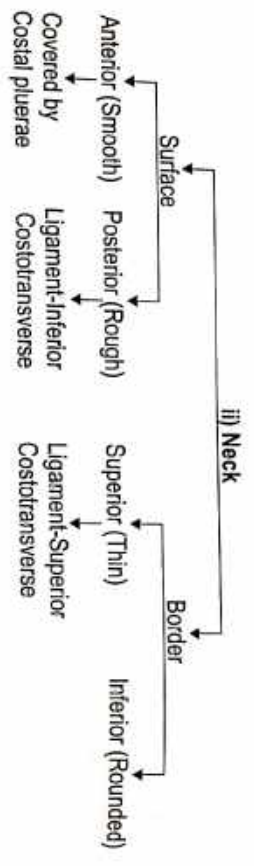
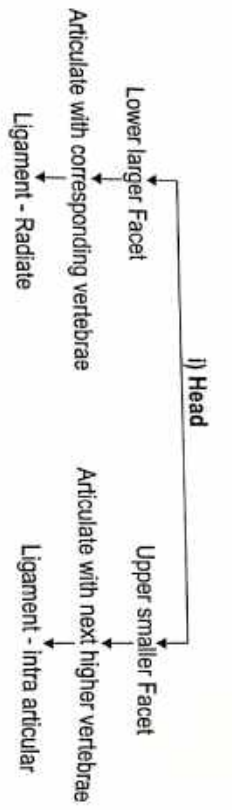
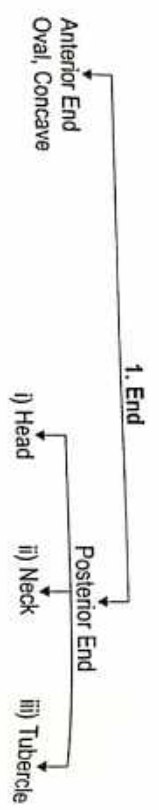
**Ossification -**



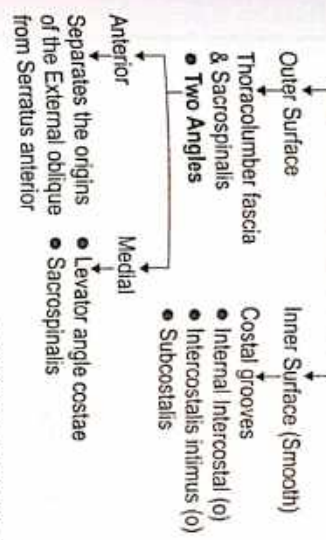
**Side Determination -**



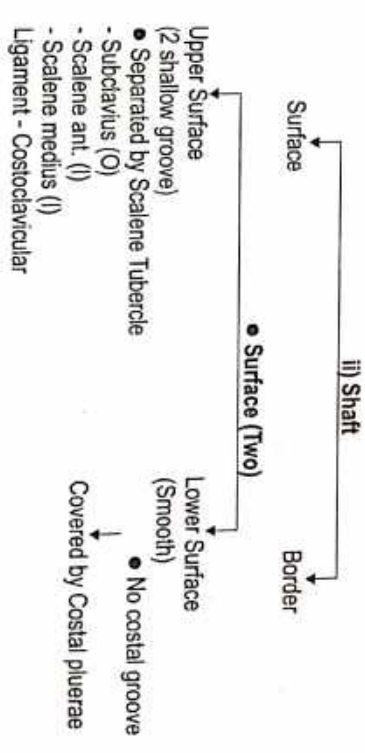
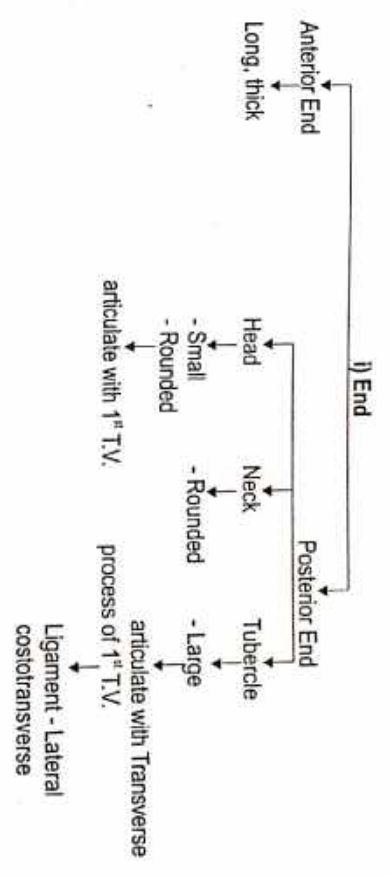
• Typical Ribs

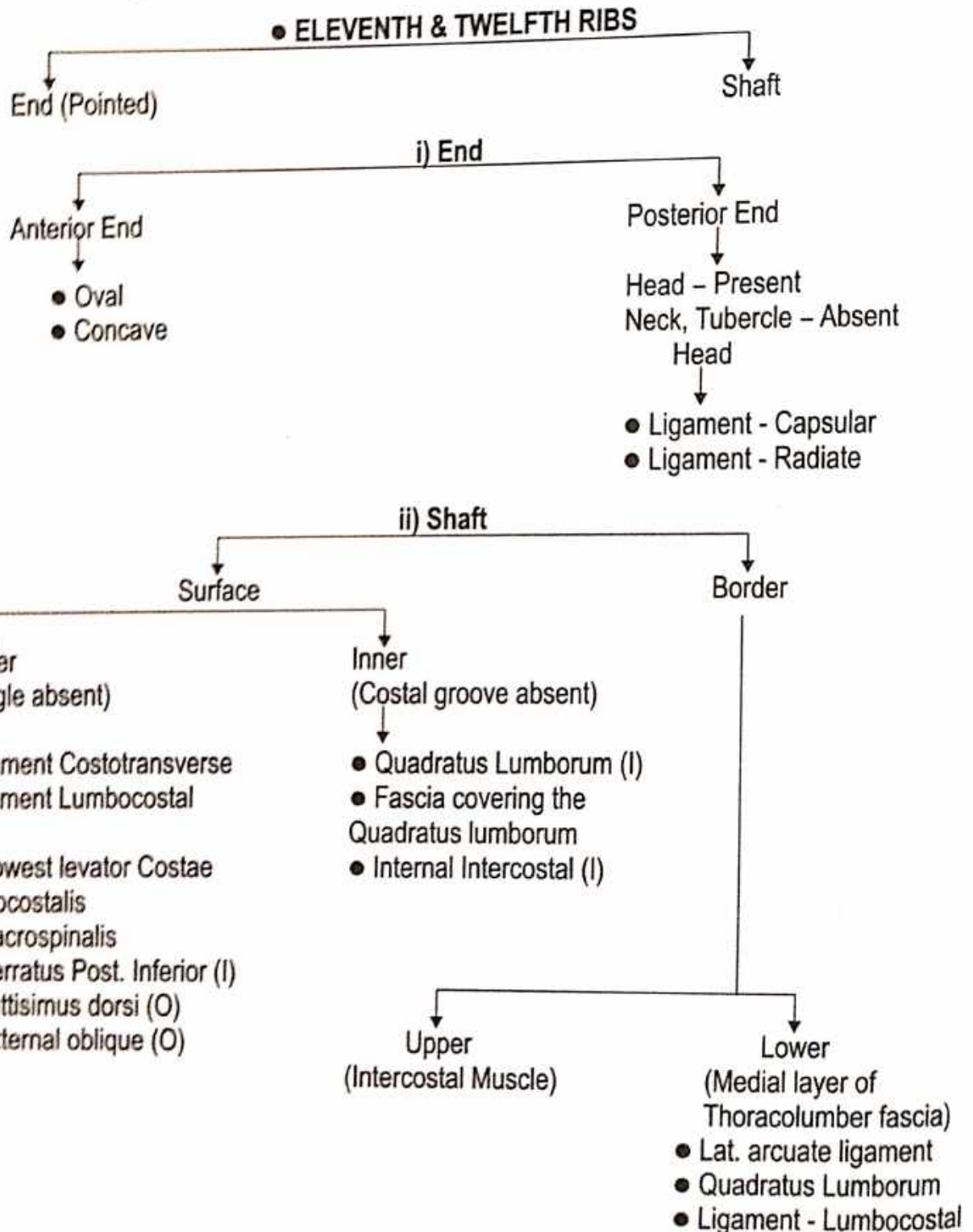
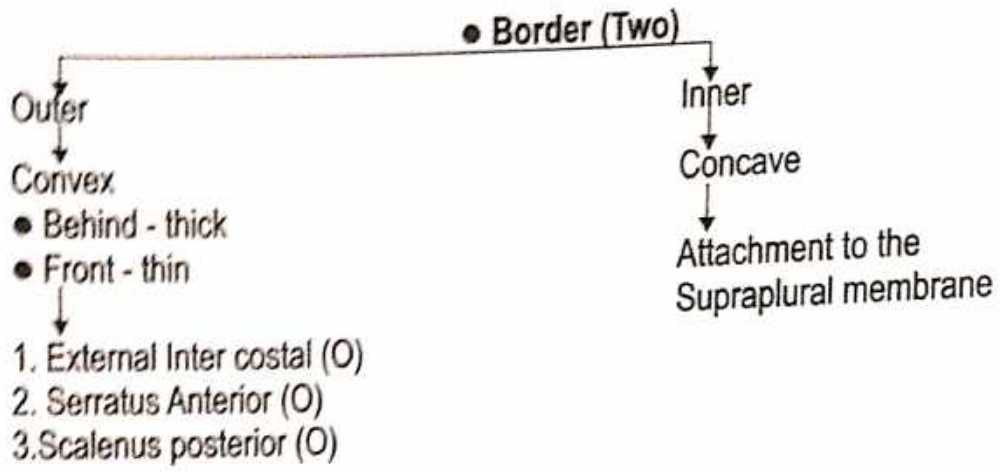


• Surface



• ATYPICAL RIBS (First Rib)





# VERTEBRAE

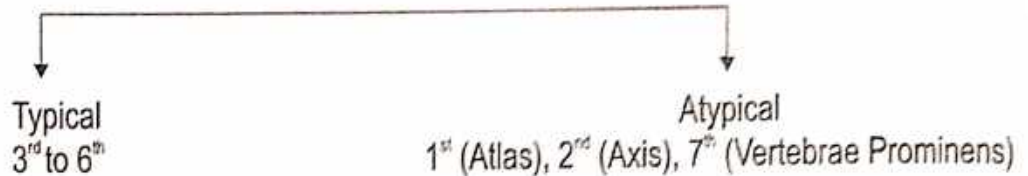
**Types of Vertebra** - Cervical-7, Thoracic-12, Lumbar-5, Sacral-5, Coccygeal-4

## Cervical Vertebrae

**Cervical Vertebra :** ● According to Ayurveda - ग्रीवा कशेरुका

**Identification :** Presence of Foramina Transversarium

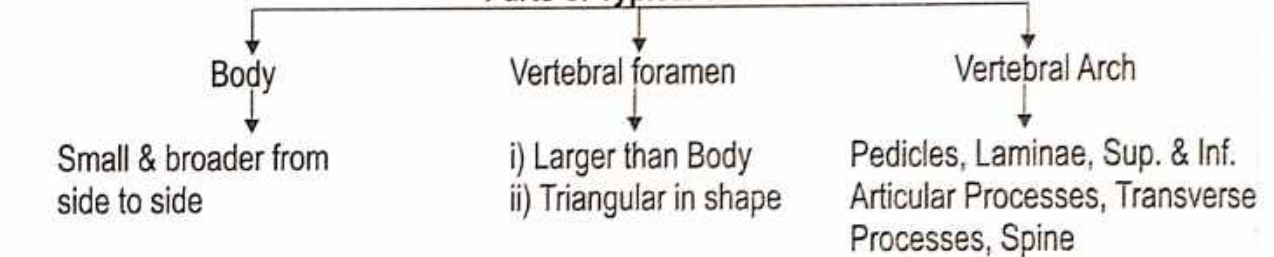
**Type of C.V. :**



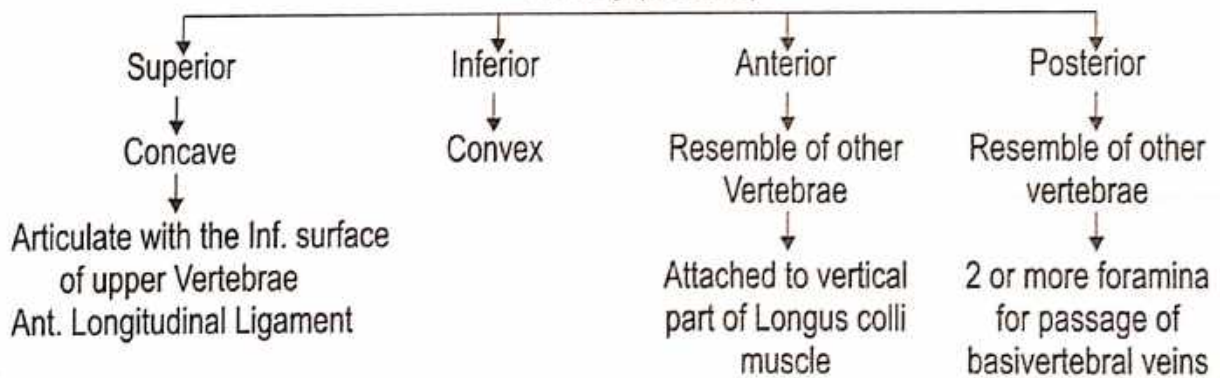
### ● TYPICAL C.V.

**Ossification :** Primary Centre - 3, Secondary Centre - 6

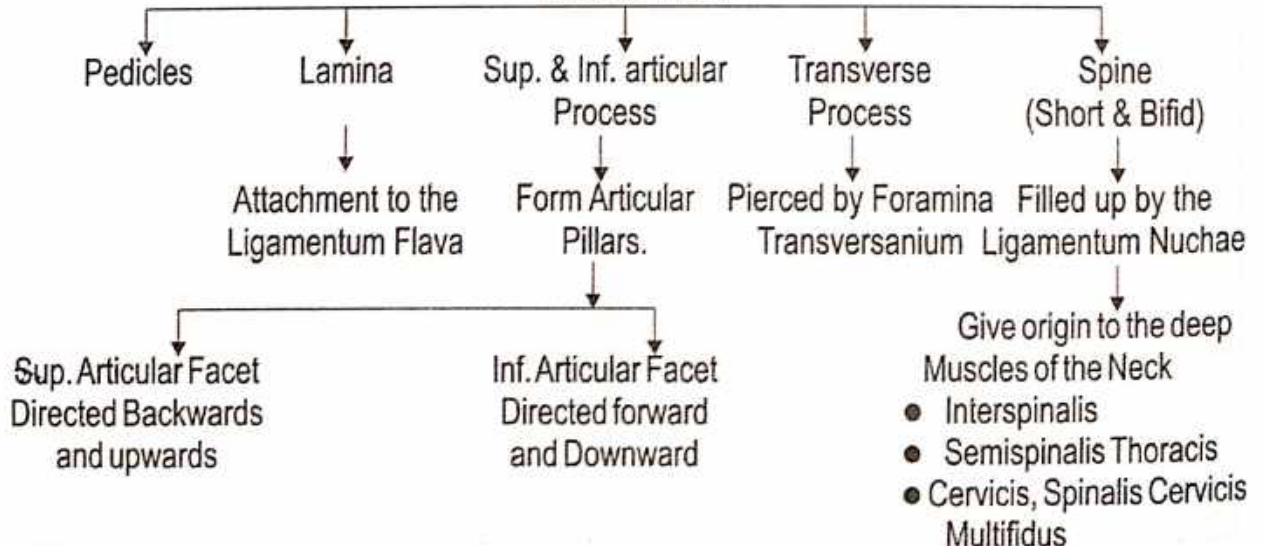
#### ● Parts of Typical Vertebrae



#### 1. Body (Surface)



#### Vertebral Arch



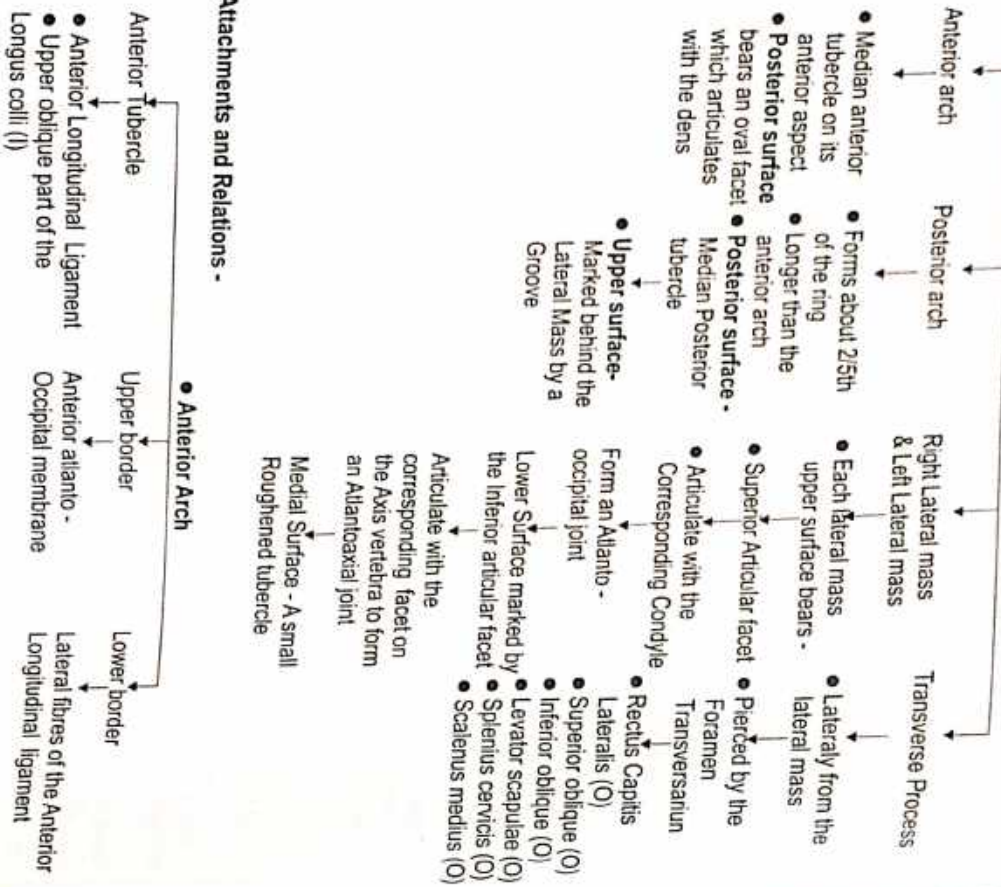
## First Cervical Vertebra

Name of Bone :

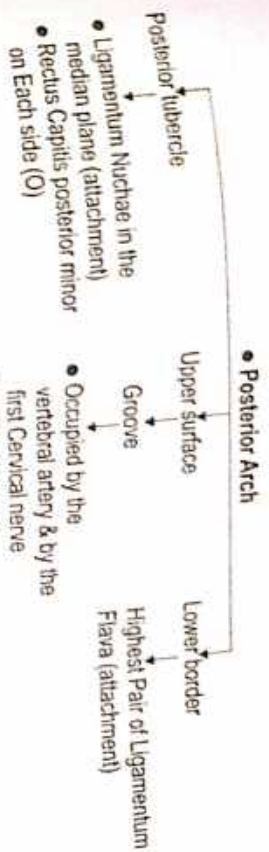
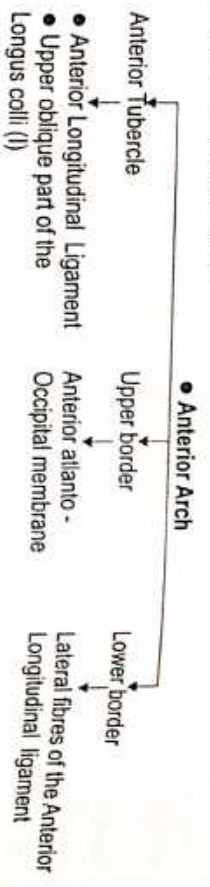
- According to Ayurveda - शृङ्गा वक्राङ्ग
- According to Modern - Atlas

- Identification :
- It is identified by the its ring - Shaped Structure
  - It has no Body
  - It has no spine

### Parts of First Cervical Vertebra



### Attachments and Relations -



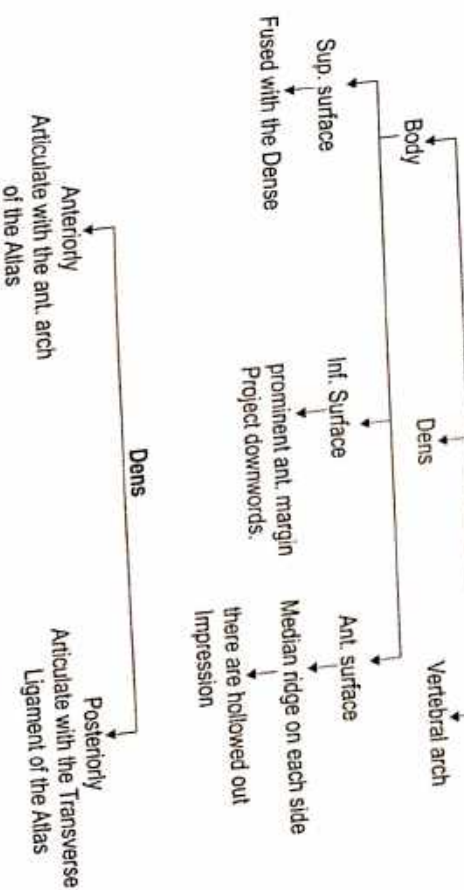
## SECOND CERVICAL VERTEBRA

Name of Bone :

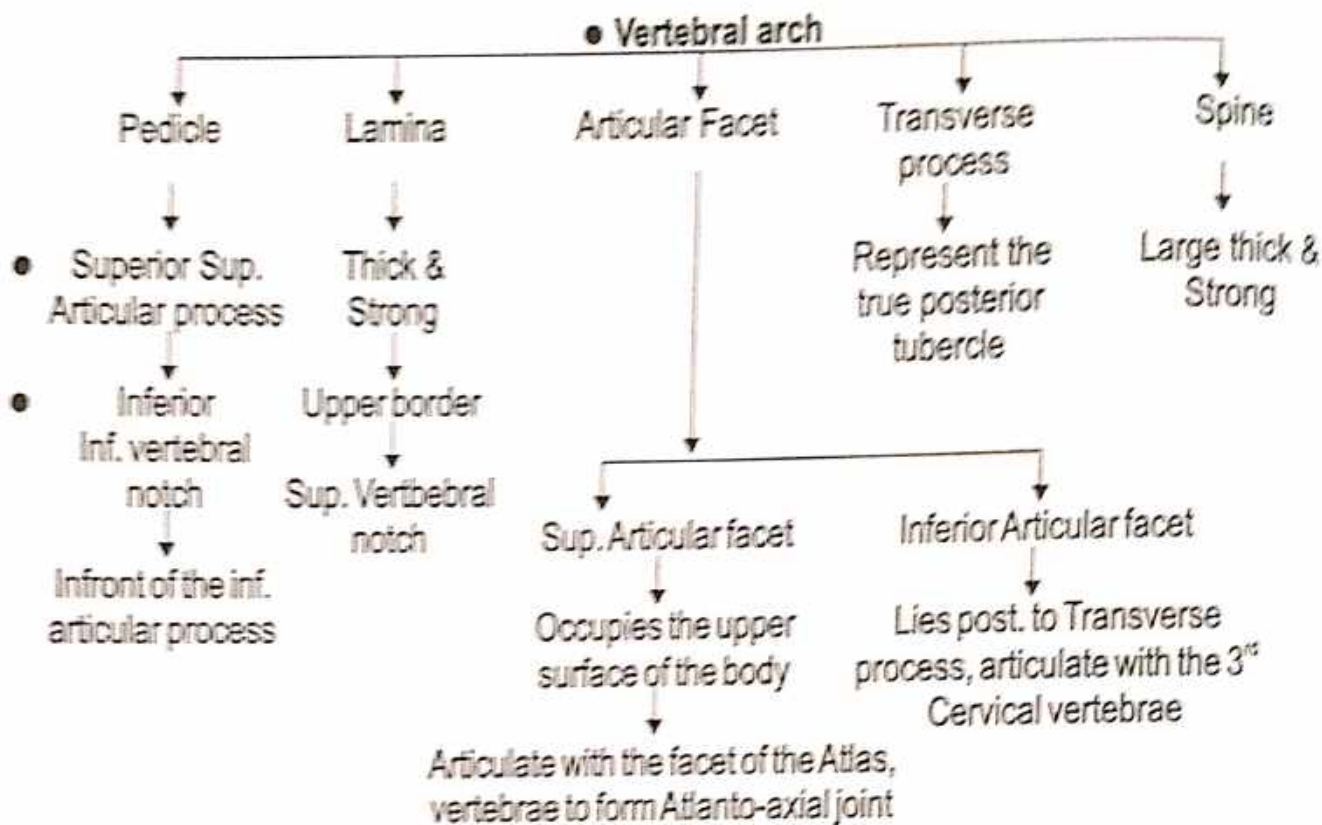
- According to Ayurveda - शृङ्गा वक्राङ्ग (शृङ्गा वक्राङ्ग)
- According to Modern - Axis vertebra

- Identification :
- It is identified by the presence of the Dens (Odontoid process)
  - The dens is usually believed to represent the Centrum of the axis

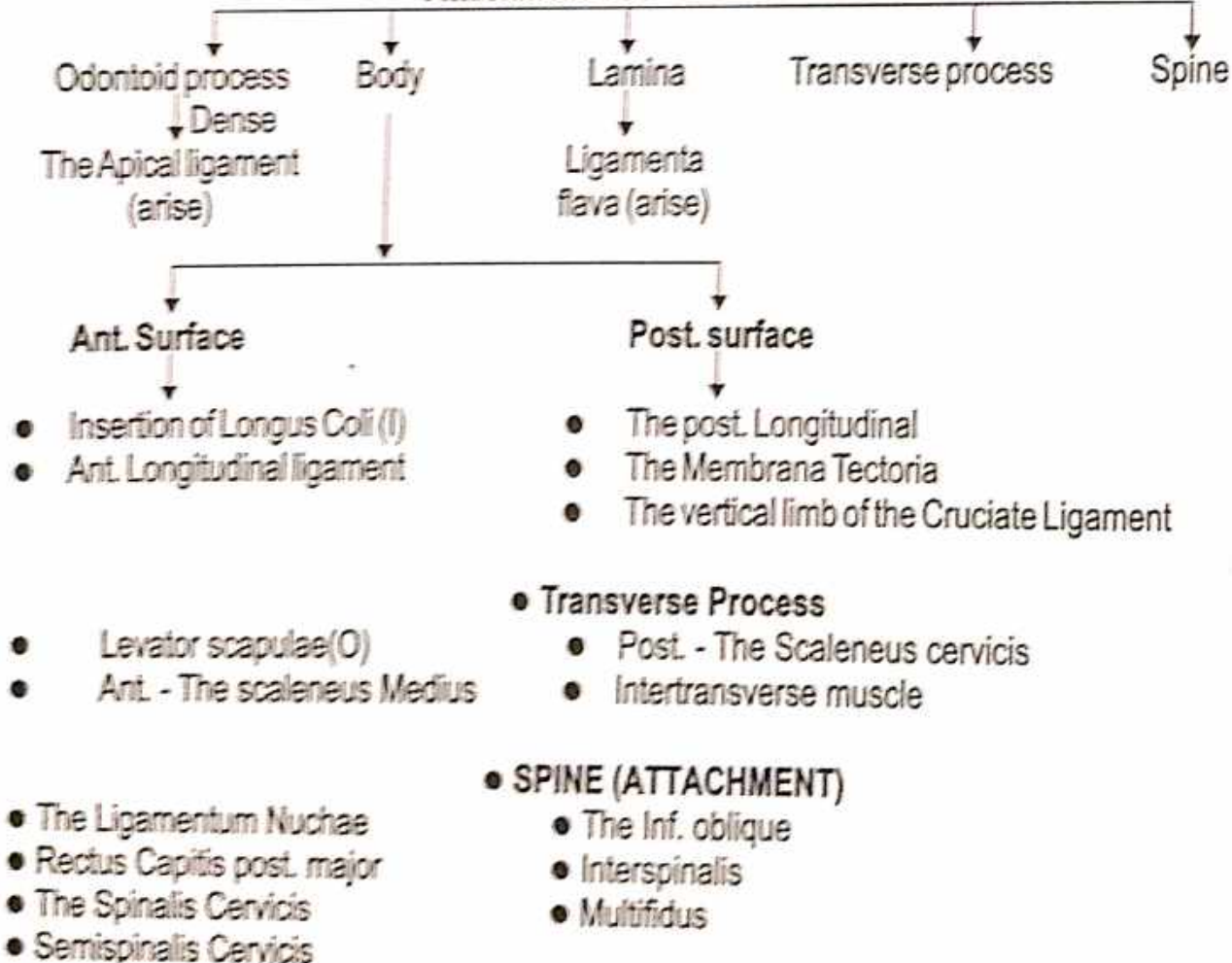
### Parts of Second Cervical Vertebra







**Attachment of 2<sup>nd</sup> Cervical Vertebrae**



## SEVENTH CERVICAL VERTEBRA

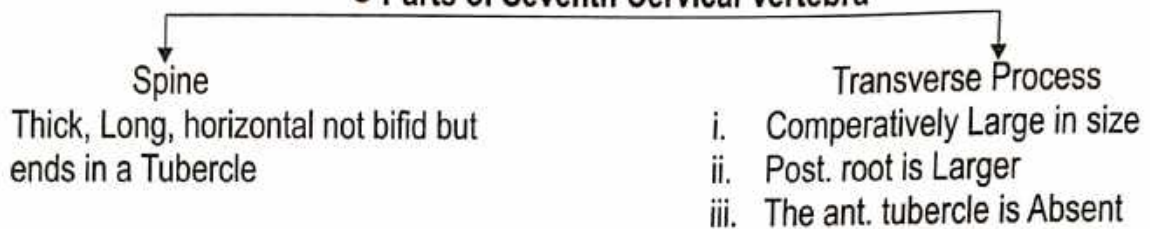
It is also known as the Vertebrae Prominence because of its Long spinous process.

### Name of Bone :


- According to Modern - Vertebra Prominence

**Ossification :** Ossification is similar to that of a Typical Cervical vertebrae.

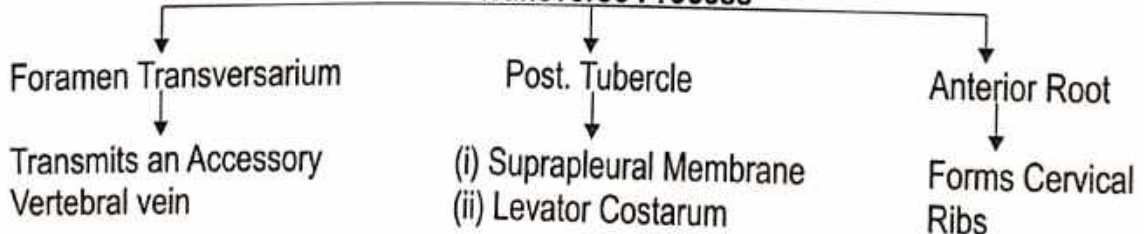
### ● Parts of Seventh Cervical Vertebra



### ● Attachments of 7<sup>th</sup> Cervical Vertebra



### ● Transverse Process



## Thoracic Vertebra

**Thoracic Vertebra :** ● According to Ayurveda - चक्ष कशेरुका

**Type of Bone :**

- According to Ayurveda - चक्षयास्थि
- According to Modern - Irregular

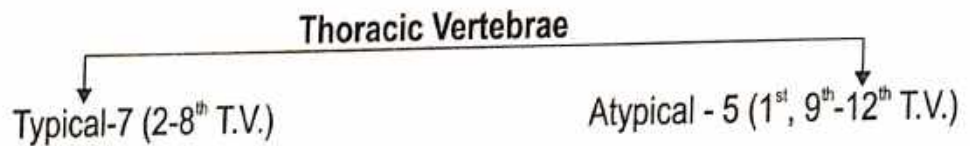
**Identification of Thoracic Vertebra -**

- Presence of costal facet on the sides of vertebral bodies.
- Upper six vertebrae - Costal facet are concave & face forward
- Lower six vertebrae - Costal facet are flat & face upword


**Position :**

- Part of Vertebral coloumn
- Form Central axis of body
- B/n C<sub>7</sub> and L<sub>1</sub>
- Forms part of the Posterior wall of Thorax

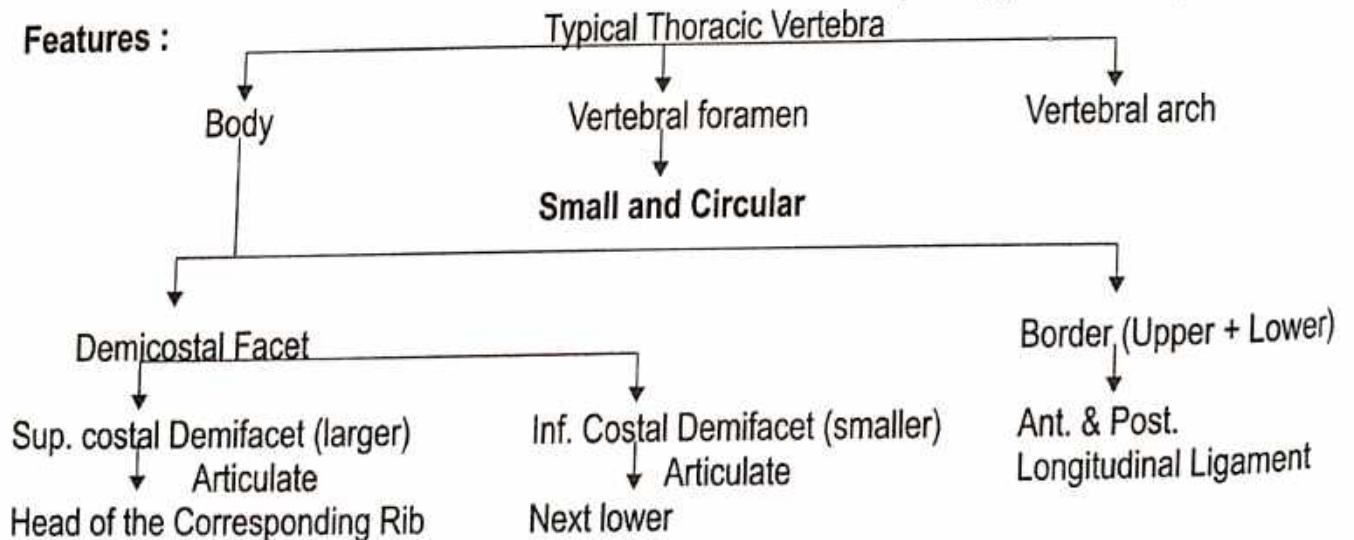
**Type :**

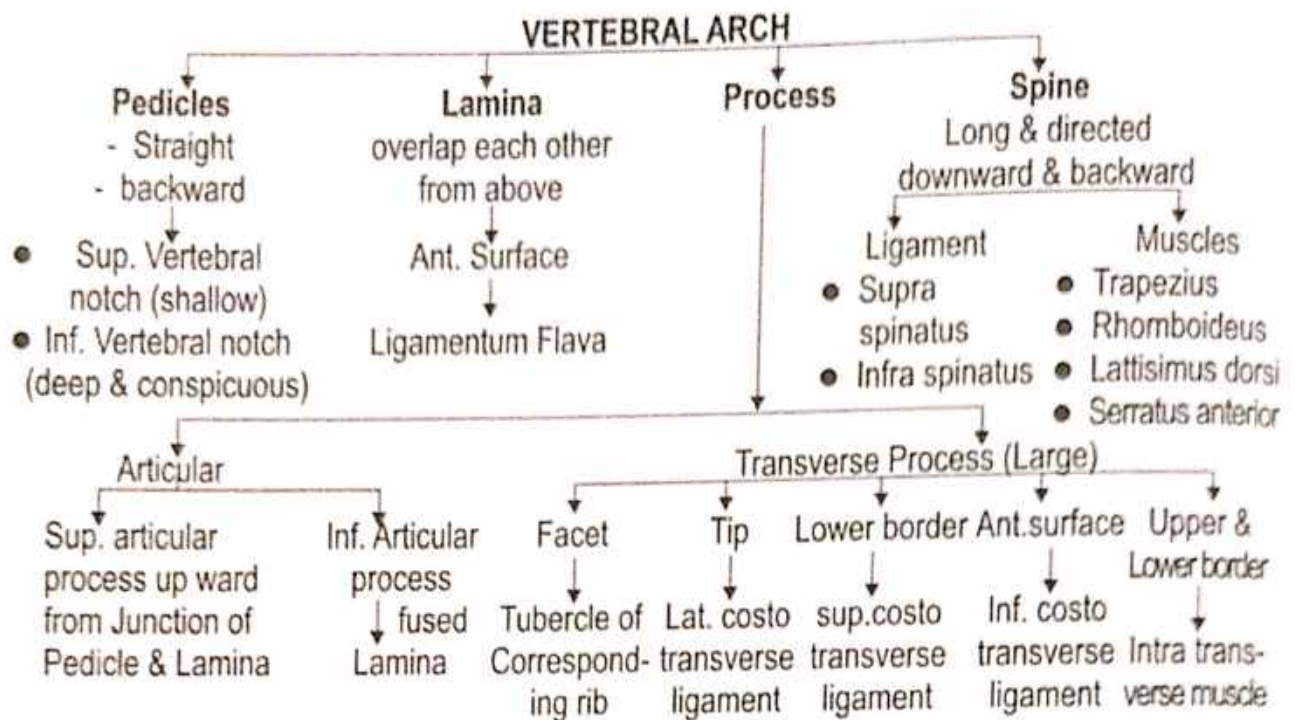


**Ossification :**



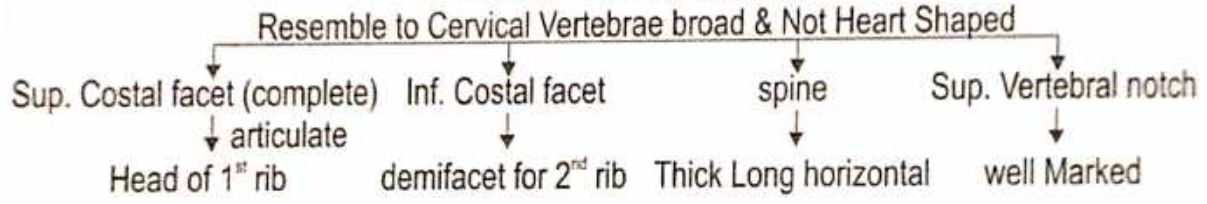
**Features :**



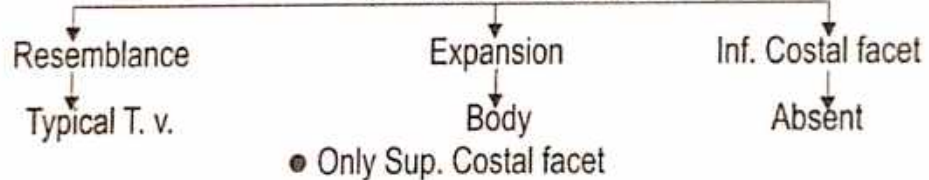


**• ATYPICAL THORACIC VERTEBRA**

**• First Thoracic Vertebra**



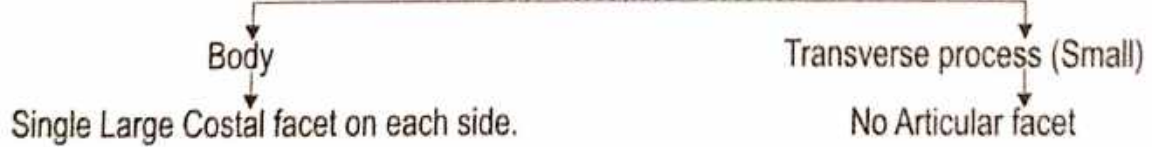
**• 9<sup>th</sup> Thoracic Vertebra**



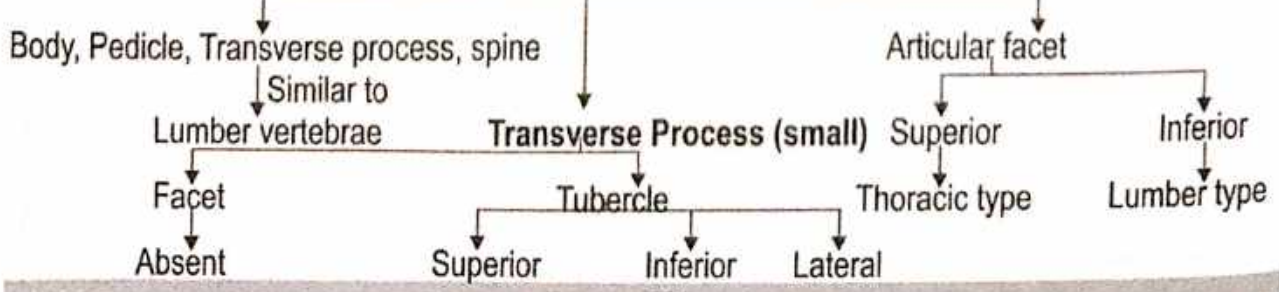
**• 10<sup>th</sup> Thoracic Vertebra**



**• 11<sup>th</sup> Thoracic Vertebra**



**• 12<sup>th</sup> Thoracic Vertebra**



## Lumber Vertebra

**Lumber Vertebra :** ● According To Ayurveda - कटि कशेरूका

**Type of Bone :** ● According to Ayurveda - चलयस्थि  
● According to Modern - Irregular

**Position :** ● Part of Vertebral Coloumn ● Form Central Axis of body ● B/n T<sub>12</sub> & Sacrum

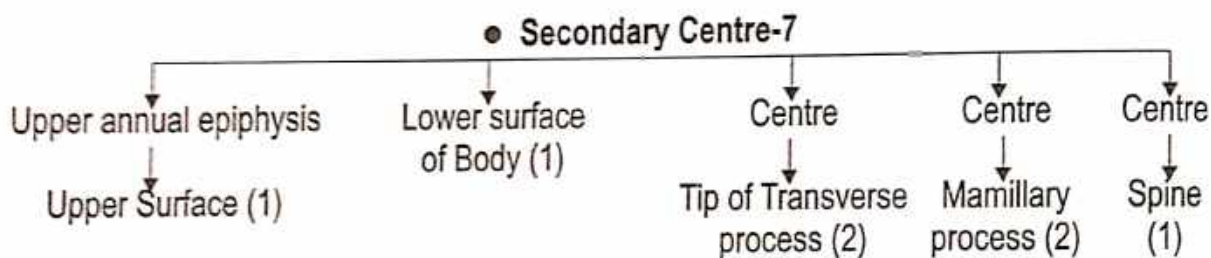
**No. of Lumber Vertebra : 5** ● **Lumber Vertebrae**

```

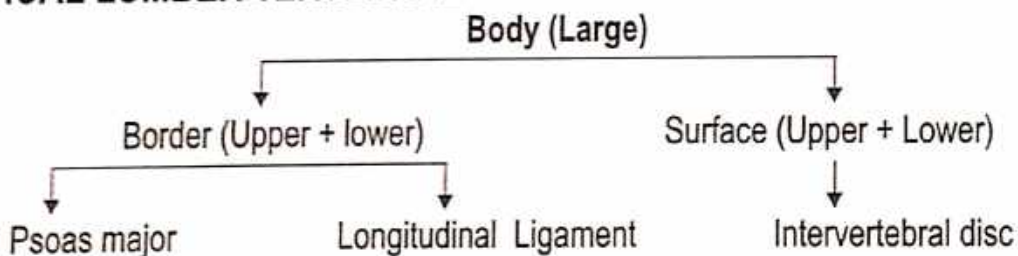
    graph TD
      A[No. of Lumber Vertebra : 5] --> B[Typical -4 (1st-4th L. V.)]
      A --> C[Atypical-1 (5th L. V.)]
  
```

**Identification of L. V.-** ● Body large size ● Absense of Costal facet  
● Body or centrum ● Neural arch (2)

**Ossification centre :** ● Primary centre-3



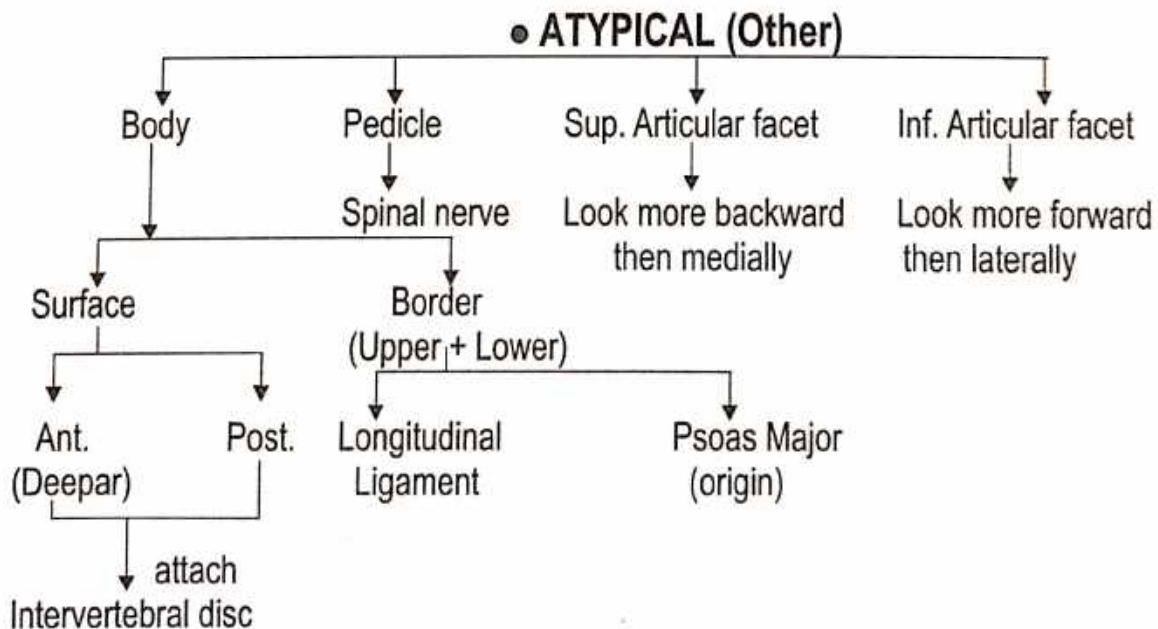
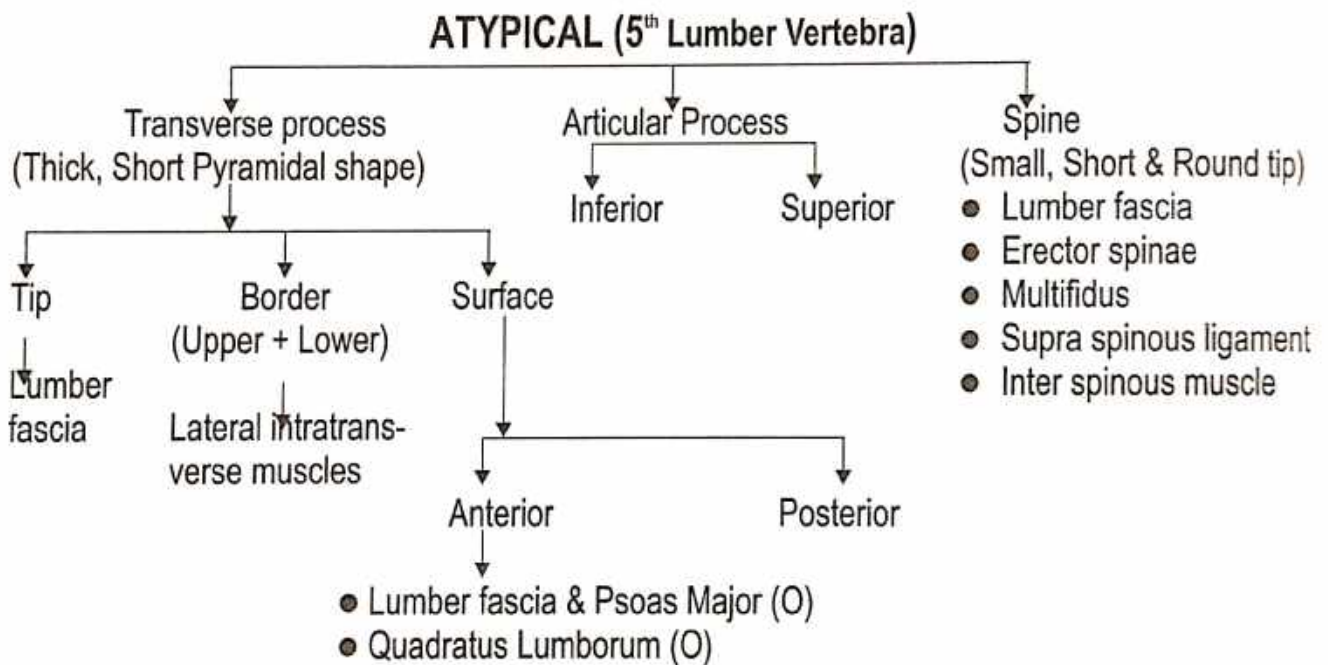
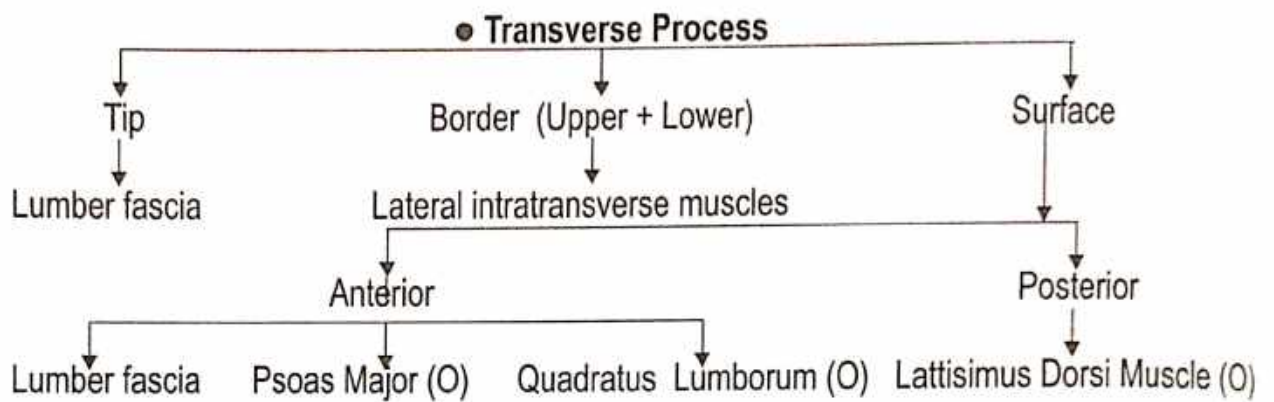

### ● **TYPICAL LUMBER VERTEBRAE**



- **Vertebral Foramen**
- Triangular in shape

● **Pedicles**  
(short and strong)  
↓  
Spinal nerve

● **Laminae**  
(Short, thick, broad)  
↓  
Ligamentum Flava



## Sacrum

Name of Bone :

- According to Ayurveda - शिवास्त्रि
- According to Modern - Sacrum
- According to Ayurveda - वतरास्त्रि

Type of Bone :

Region : Pelvic

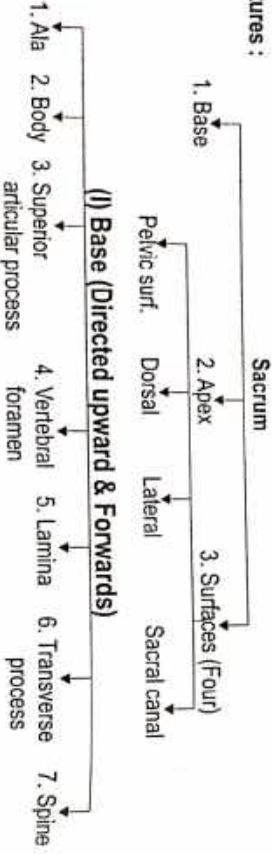
Description :

- Wedge shaped
- Situated - B/n L<sub>5</sub> - coccyx-1
- Formed - by the fusion of 5 sacral vertebrae.

Articulation :

- Above - 5<sup>th</sup> Lumber
- Below - 1 coccygeal
- Lateral - Ilium.

Features :



### 3. SUP. ARTICULAR PROCESSES

Facet (backward & medially)

### 4. VERTEBRAL FORAMEN

Triangular Shape  
Leads  
Sacral canal

### 5. LAMINA

- Oblique Ligamentum Flava attached

### 6. TRANSVERSE PROCESS

(Highly modified)

Corresponding Costal Element

Upper part the Lateral part of Sacrum

### 7. SPINE

forms  
Spinous Tubercle

Inferior surface of body of 5<sup>th</sup> Sacral Vertebrae.

### (II) APEX

- bears
- Oval facet
- articulate
- Coccyx

### 1. PELVIC SURFACE (Concave / downward)

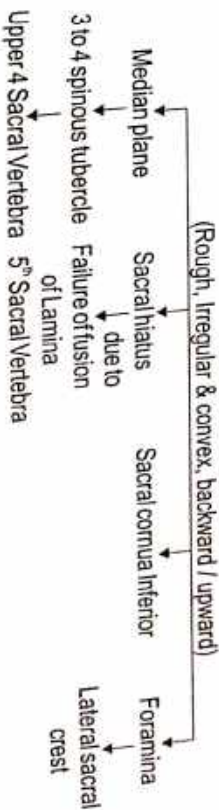
- Lateral bodies
- 3. pelce of the Sacrum piriformis (origin)

### (III) SURFACES


- (4) Transverse ridge
  - fusion
  - Body of 5<sup>th</sup> Sacral Vertebra
  - Four Pelvic Sacral foramina
  - Sacral canal through Intervertebral foramina
  - communicate
  - Bears
  - Costal Elements

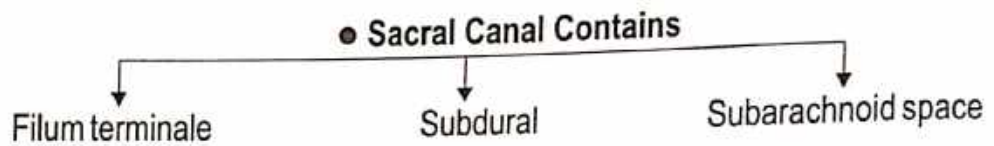
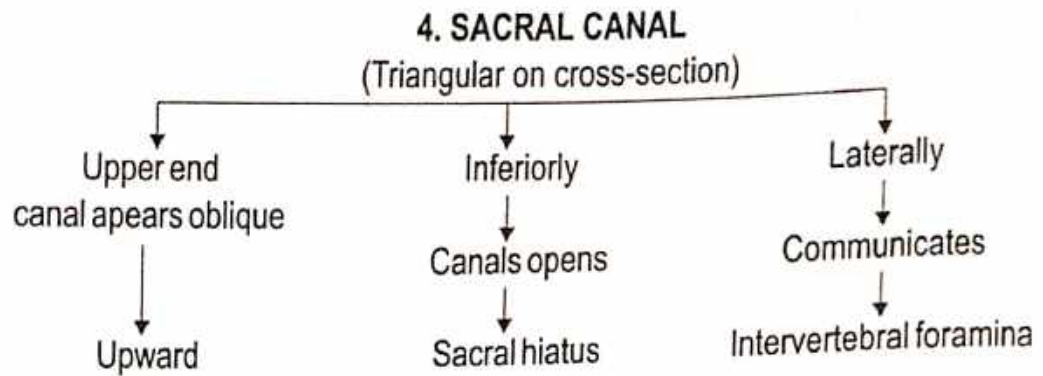
Transverse process to form the Lateral Mass of the Sacrum.

### 2. DORSAL SURFACE

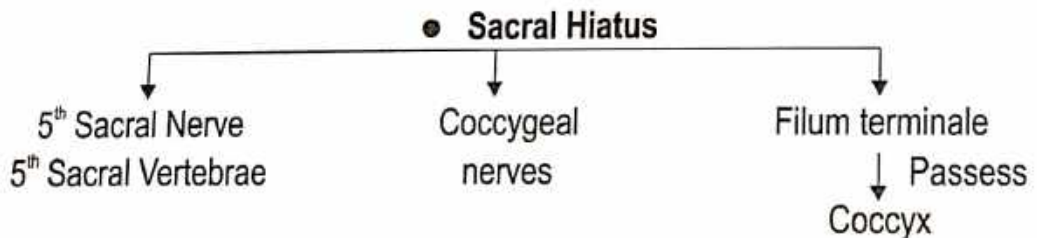
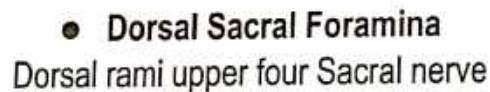



### 3. LATERAL SURFACE






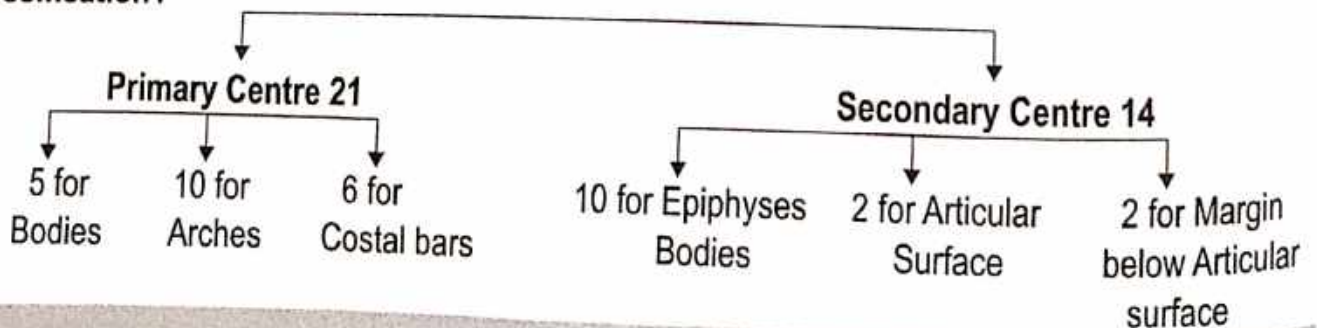
**Structure Transmitted Foramina :**



**Sex differences :**



**Ossification :**





## COCCYX

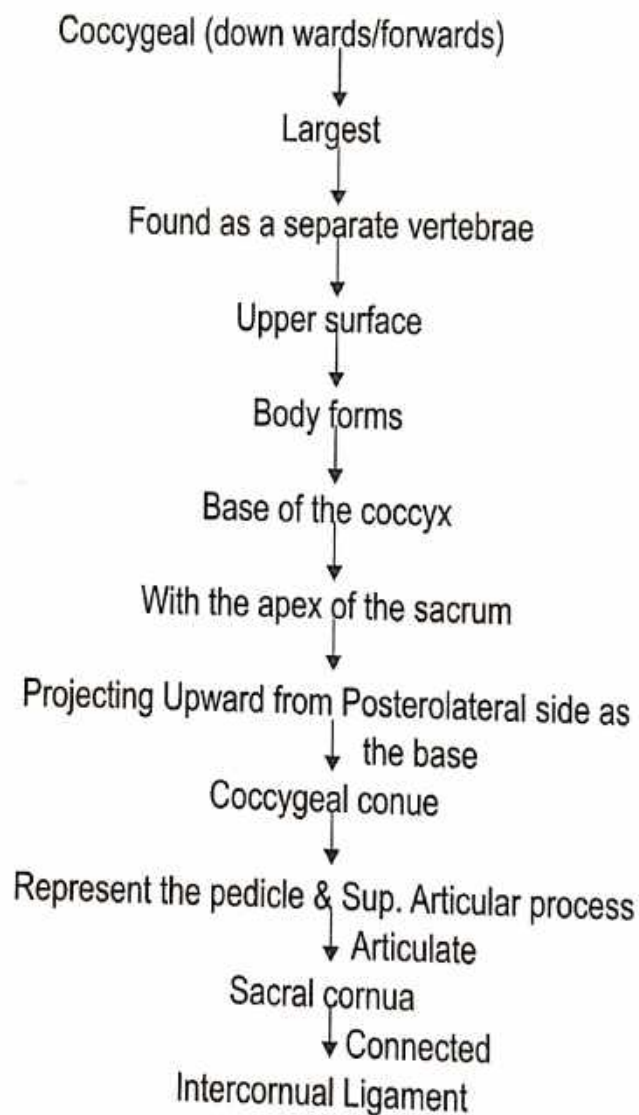
Name of Bone :  
● According to Ayurveda - अनुत्रिकास्थि  
● According to Modern - Coccyx

Name of Bone :  
● According to Ayurveda - वलयास्थि

Description : Shape - Small triangular  
Formed - By fusion as four rudimentary coccygeal vertebrae.

Articulation : With sacrum

Features :



### ● TRANSVERSE PROCESS

(Lateraly & slightly upward)

↓ Articulate & fuse

Inf. Lateral angle of the sacrum

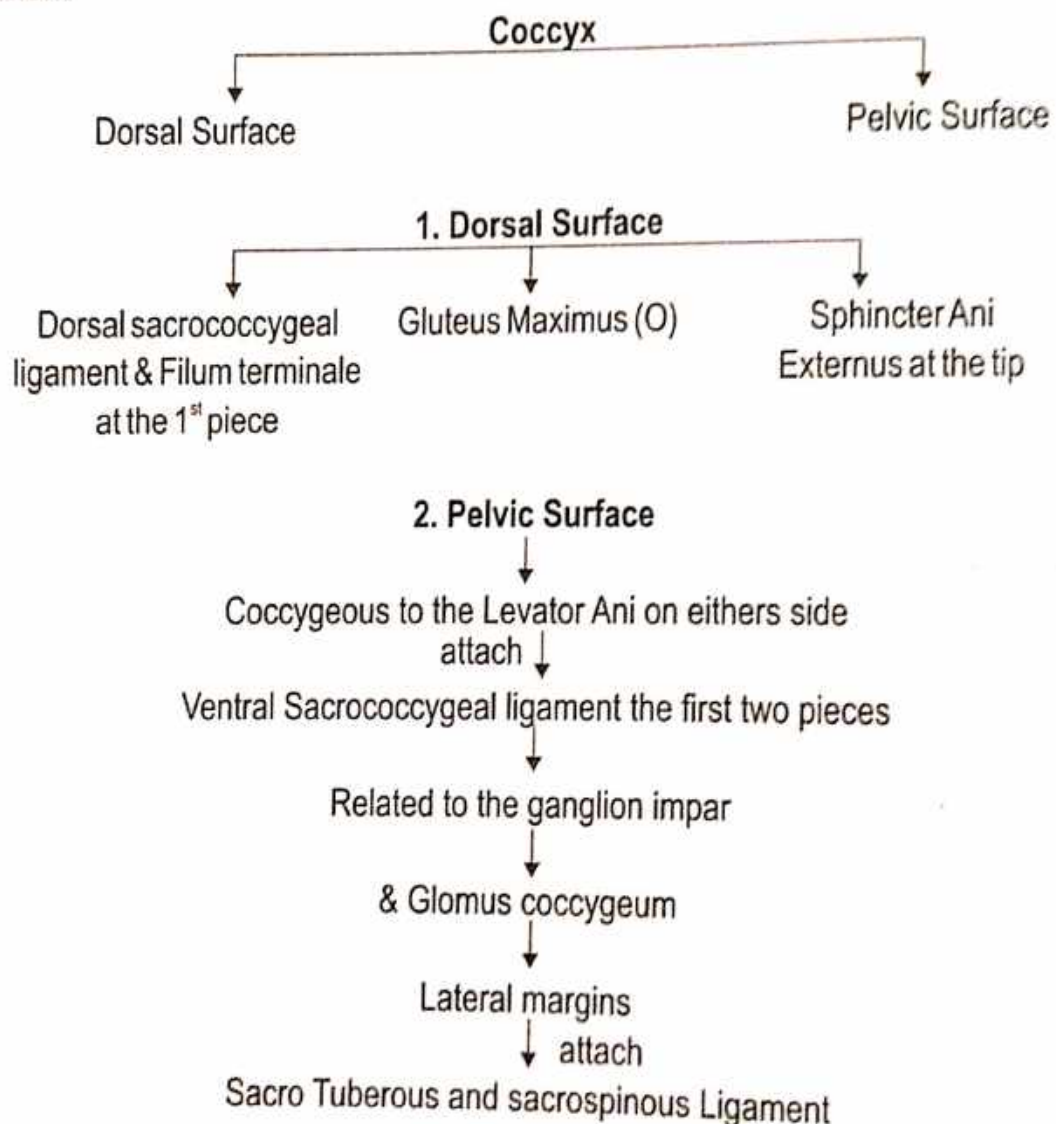
↓ Creating

5<sup>th</sup> pair of Sacral Foramina

## II<sup>nd</sup> III<sup>rd</sup> IV<sup>th</sup> COCCYGEAL VERTEBRAE

Bony nodules  
↓ size  
Diminish Successively  
↓  
Usually fused together

### ● Attachment



**Ossification** - From 4 Primary centre one for each segment.

## SKULL

**SKULL :** ● According to Ayurveda - करोटि

### Type of bone

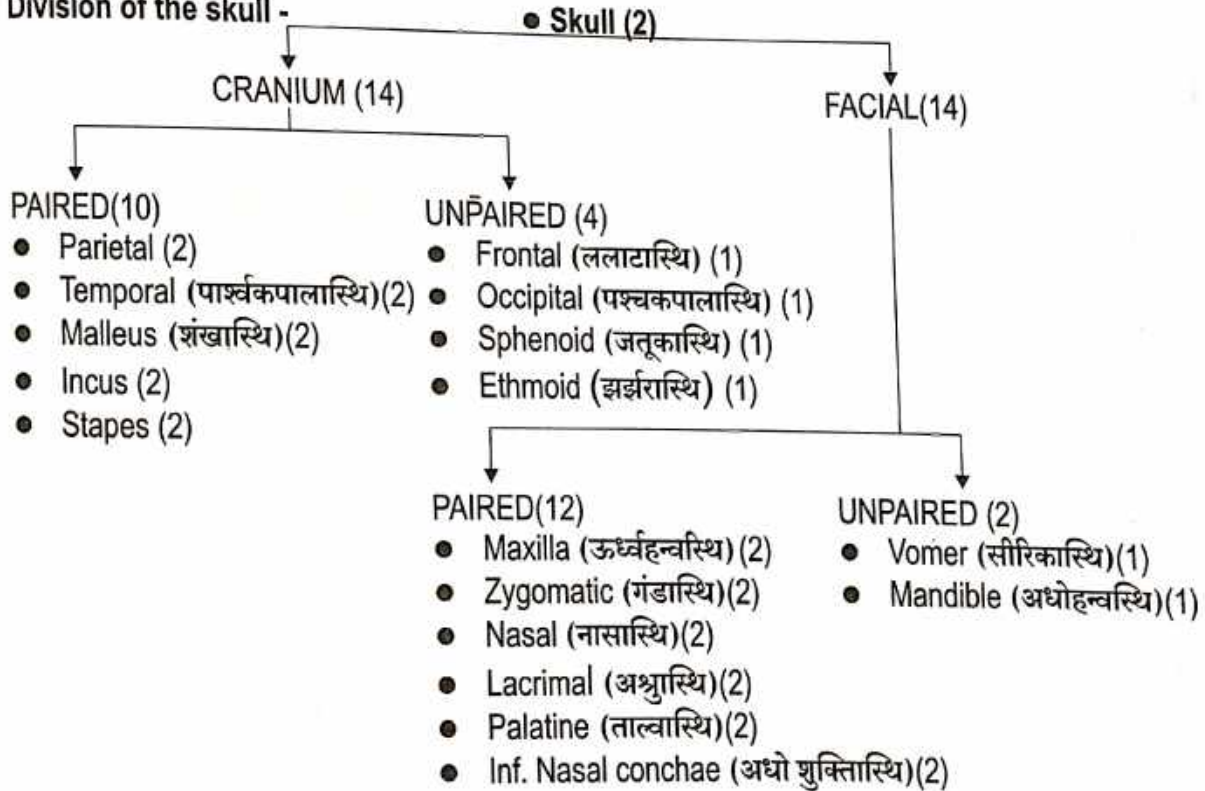
- According to Ayurveda - 1. कपालास्थि 2. तरूणास्थि - नाक, कर्ण, नेत्रकोष
- According to Modern- skull-1.Flat bone 2. Cartilaginous bone

संख्या - ● त्रीणि सषष्टीनि शतान्यस्थानां सहदन्तोलूखलनखेन । (च.शा. 7/6)

● शल्यतंत्रे तु त्रीण्येव शतानि तेषां सविंशमस्थिशतं शाखासु ।  
ग्रीवा प्रत्यूर्ध्वं त्रिषष्टिः, एवमस्थानां त्रीणि शतानिपूर्यन्ते । (सु.शा. 5/17)

● कण्ठनाड्यां चत्वारि, द्वे हन्वोः दन्ता द्वात्रिंशत्, नासायां त्रीणि,  
एकं तालुनि, गण्डकर्णशंखेवैकैकं षट् शिरसीति । (सु.शा. 5/21)

### Division of the skull -

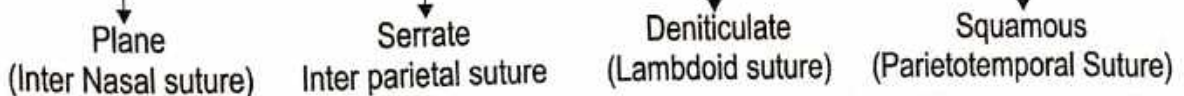


### ● Ossification

The skull cap formed by  
Intra Membranous

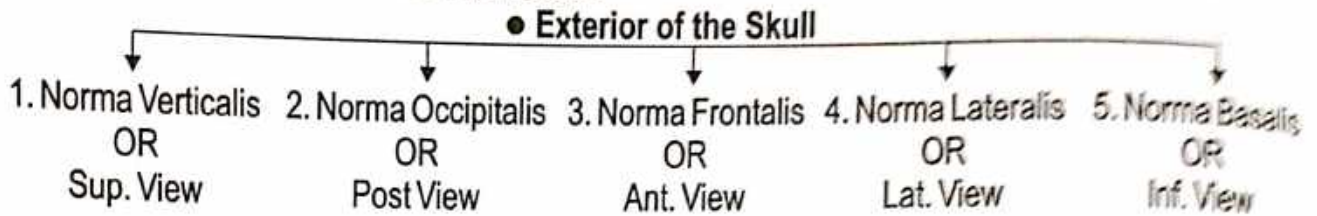
The base of skull is contrast ossifies by Intra  
Cartilagenous

### ● Sutures



## Anatomical Position of skull -

1. Reid's base line is a Horizontal line obtained by joining the Infraorbital Margin to the center of External Acoustic Meatus that is Auricular point.
2. The Frankfurt's Horizontal plane of orientation is Obtained by Joining the Infraorbital Margin to the Upper margin of External Acoustic meatus.



### 1. Norma Verticalis OR Superior View

**SHAPE** - Oval

**BONES IN VIEW** - Frontal, Parietal, Occipital.

#### SUTURES -

1. Coronal Suture (पुर: सीवनी) - Place b/n frontal and Two parietal bone.
2. Sagittal Suture (मध्य सीवनी) - In The median plane b/n the Two parietal bone.
3. Lambdoid Suture (पश्चिम सीवनी) - Lies posteriorly b/n the Occipital and the 2 parietal bone.
4. Metopic Suture - It lies in the median plane and separates the two halves of the Frontal bone.

#### OTHER FEATURES

- Vertex - Highest point on sagittal suture.
- Parietal Eminence - Area of Maximum convexity of the parietal (common site of fracture of the skull)
- Bregma - Bregma is the Meeting point b/n the Sagittal & Coronal sutures.
- Ant. frontanelle (ब्रह्मरंध्र/पूर्वरंध्र) - In the foetal skull this is the site of a Membranous Gap called the Ant. frontanelle. Which close at 1.5 years of age.
- Post. Frontanelle (पश्चिमयाशिवरंध्र) In the foetal skull this is the site of which close at 2-3 months of age.
- Lambda - It is the meeting point b/n Sagittal and Lambdoid Sutures.

### 2. Norma Occipitalis OR Post. View

**SHAPE** - Convex upward & on each side flattened below.

**BONES IN VIEW** -

- Post. part of the Parietal bone.
- Squamous part of the Occipital bone.
- Mastoid part of the Temporal bone.

#### SUTURES -

- Lambdoid Suture - Lies posteriorly b/n the Occipital and the two parietal bones.
- Sagittal Suture - In the Median plane b/n the two parietal.
- Occipitomastoid Suture - B/n Occipetal bone and Mastoid part of the temporal bone.
- Parietomastoid Suture - B/n the Parietal bone and Mastoid part of the Temporal bone.

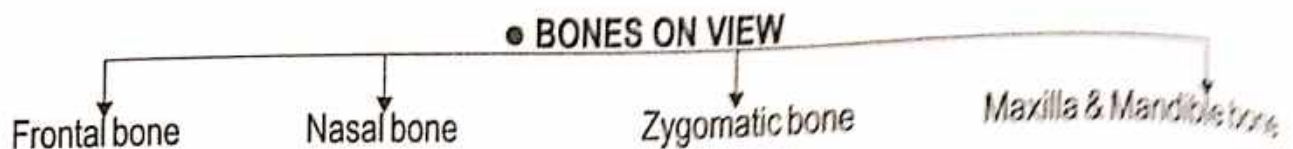
#### OTHER FEATURES

- Lambda - It is meeting point b/n sagittal and lambdoid sutures.
- Parietal Foramina - Present in the 2.5-4 cm in front of the lambda. Parietal Emissory veins transmits from it.
- Obelion - Point on the sagittal sutures b/n the two parietal foramina.
- The External occipital protuberance - Median prominence in the Lower part of this norma.
- Inion - The most prominent point on the protuberance is called Inion.

- Nuchal lines -
  - (1) Highest
  - (2) Superior
  - (3) Inferior

### 3. Norma Frontalis OR Anterior View

**SHAPE** - Roughly oval in outline.

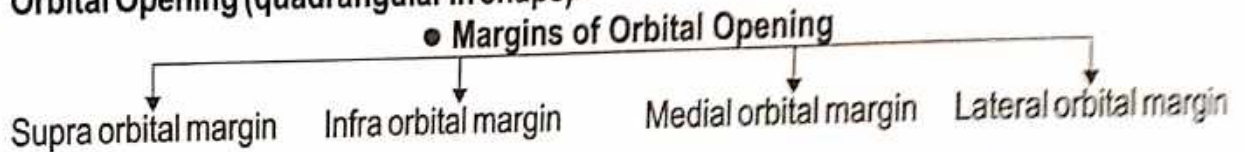


#### SUTURES -

- **Inter nasal suture** - B/n Two Nasal bone.
- **Inter maxillary suture** - B/n Two Maxillary bone.
- **Frontonasal suture** - B/n Frontal & Nasal bone.
- **Nasomaxillary suture** - B/n Nasal & Maxillary bone.
- **Zygomatico Maxillary suture** - B/n Zygomatic & Maxillary bone.
- **Zygomaticofrontal suture** - B/n Zygomatic & Frontal bone.

#### OTHER FEATURES

- **Frontal Eminences** - Rounded elevation above the superciliary arch.
- **Superciliary arch** - Gives origin to the corrugator superciliary muscles.
- **Glabella** - Is a median elevation B/n the two superciliary arches.
- **Orbital Opening (quadrangular in shape) -**



- **Incisive Fossa** - Depression that lies just below Incisor teeth.
- **Mental foramen** - Interval b/n the Premolar teeth transmits the Mental nerve & vessels.
- **Zygomaticofacial foramen** - Transmits Fascial nerve & Maxillary nerve.
- **Supraorbital notch or foramen** - Transmits Supraorbital nerve & vessels.
- **Infra orbital foramen** - Transmits Infraorbital nerve & vessels.

### 4. Norma Lateralis OR Lateral View

**BONES IN VIEW** - ● Frontal ● Parietal ● Occipital ● Sphenoid ● Mandible ● Maxilla ● Nasal  
● Temporal (Squamous, Mastoid, Tympanic) ● Zygomatic

#### SUTURES -

- **Zygomaticotemporal suture** - B/n Zygomatic and Temporal bone.
- **Squamomastoid suture** - B/n Squamous & Mastoid part of the Temporal bone.
- **Parietomastoid suture** - B/n Parietal and Mastoid bone.
- **Occipitomastoid suture** - B/n Occipital and Mastoid bone.
- **Lambdoid suture** - Lies Posteriorly B/n the Occipital and two Parietal bone.

#### OTHER FEATURES

- **Temporal Line** - Temporal fascia is attached to the sup. & inf. Temporal line.
- **Styloid process (शरीर प्रवर्ध)** - Needle like thin long projection.
- **Mastoid process** - Nipple like Large projection from the Mastoid Temporal bone. Supra mastoid Crest of Temporal bone.
- **External Acoustic Meatus (बाह्य श्रवण कुहर)**
- **Asterion** - Is the point where the Parietomastoid, Occipitomastoid and Lambdoid sutures meet.

## 5. Norma Basalis OR Inferior View

**BONES IN VIEW** - Occipital, Temporal, Maxilla, Palatine, Vomer, Sphenoid, Ethmoid, Zygomatic bone.

**SUTURES** -

- Intermaxillary sutures - B/n two Maxillary bone.
- Interpalatine suture - B/n two Palatine bone.
- Palatomaxillary suture - B/n Palatine & Maxillary bone.

**OTHER SPECIAL FEATURES** - Norma Basalis is divided into three parts

1. **Anterior part** - It is formed by hard palate & Alveolar arches.

2. **Middle part** - It is extended from the post border of the hard palate to the arbitrary transverse line.

3. **Posterior part** -

(a) Median area -

- Foramen Magnum - Largest foramen of skull.
- External Occipital crest.
- External Occipital protuberance.

(b) Lateral area -

- Occipital : ● Condylar part ● Squamous part
- Temporal : ● Mastoid part ● Styloid process
- Jugular foramen - B/n Occipital and petrous temporal bone.

● Incisive foramen

- Transmits greater palatine vessels & Nasopalatine nerve.

● Greater Palatine foramen

- Transmits Greater Palatine vessels and Ant. Palatine nerve.

● Lesser Palatine foramen

- Middle and Post. Palatine nerve.

### ● INTERIOR OF THE SKULL

1. Anterior Cranial fossa

2. Middle Cranial fossa

3. Posterior Cranial fossa

#### 1. Anterior Cranial Fossa

##### ● Boundaries

1. Anteriorly  
● Frontal bone

2. Posterior Cranial Fossa

- Lesser wing of the sphenoid
- Ant. Clinoid process
- Ant. Margin of Sulcus Chiasmaticus

##### ● Floor

In the Median plane

Anteriorly  
● Ethmoid bone

Posteriorly  
● Sphenoid or Jugum sphenoidale

#### Other special features

1. **Cribriform plate of Ethmoid bone** - Quadrilateral in shape sieve like appearance. (Separates the ant. cranial fossa from nasal cavity).

2. **The Jugum sphenoidal** - Separates the Ant. Cranial fossa from the Sphenoidal Sinuses.

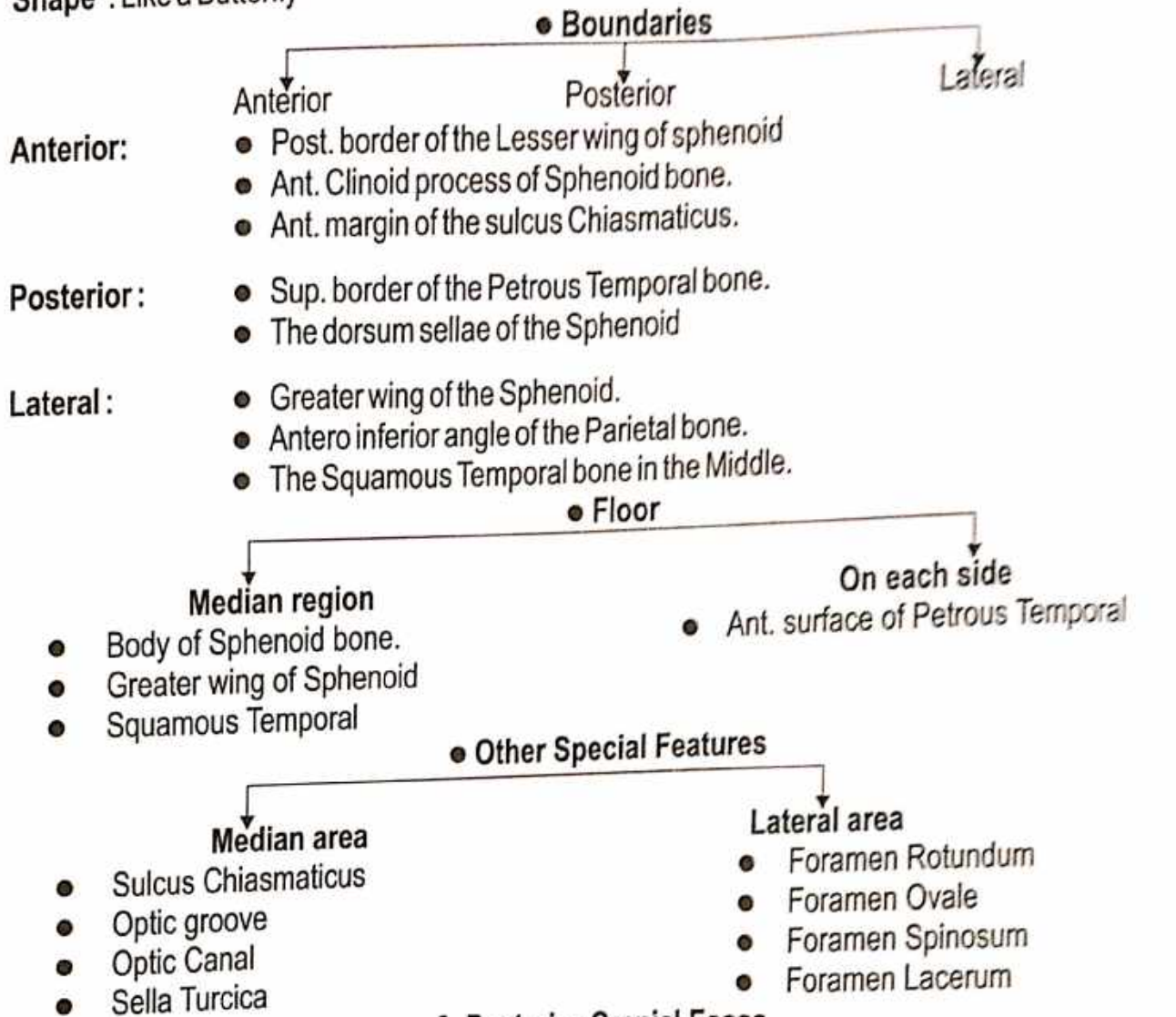
3. **Orbital Plate of the Frontal bone** - Separates the Ant. Cranial fossa from the Orbit.

4. **Lesser wing of the Sphenoid** - Medially Ant. Clinoid process. Post border form the Upper Boundary of the Sup. Orbital fissure.

5. **Crista Galli** - Anteriorly the Cribriform plate has a Midline Projection.

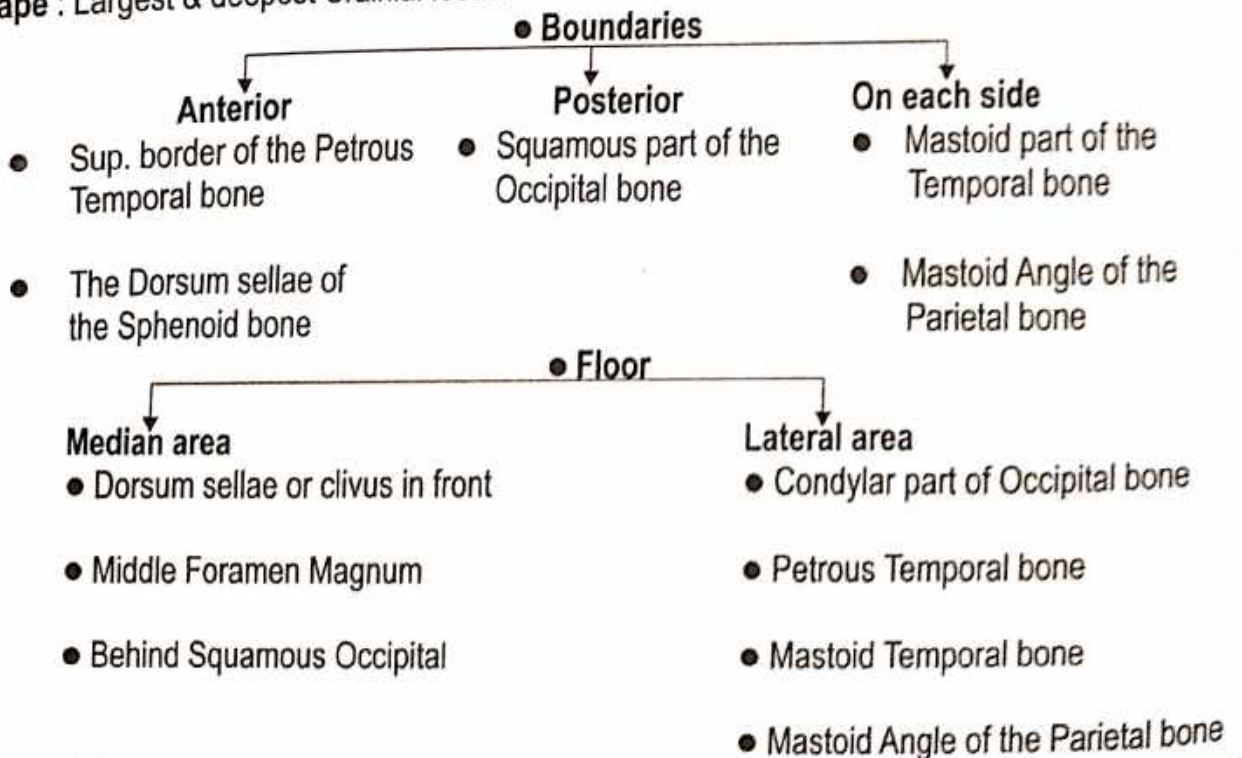
## 2. Middle Cranial Fossa

Shape : Like a Butterfly



## 3. Posterior Cranial Fossa

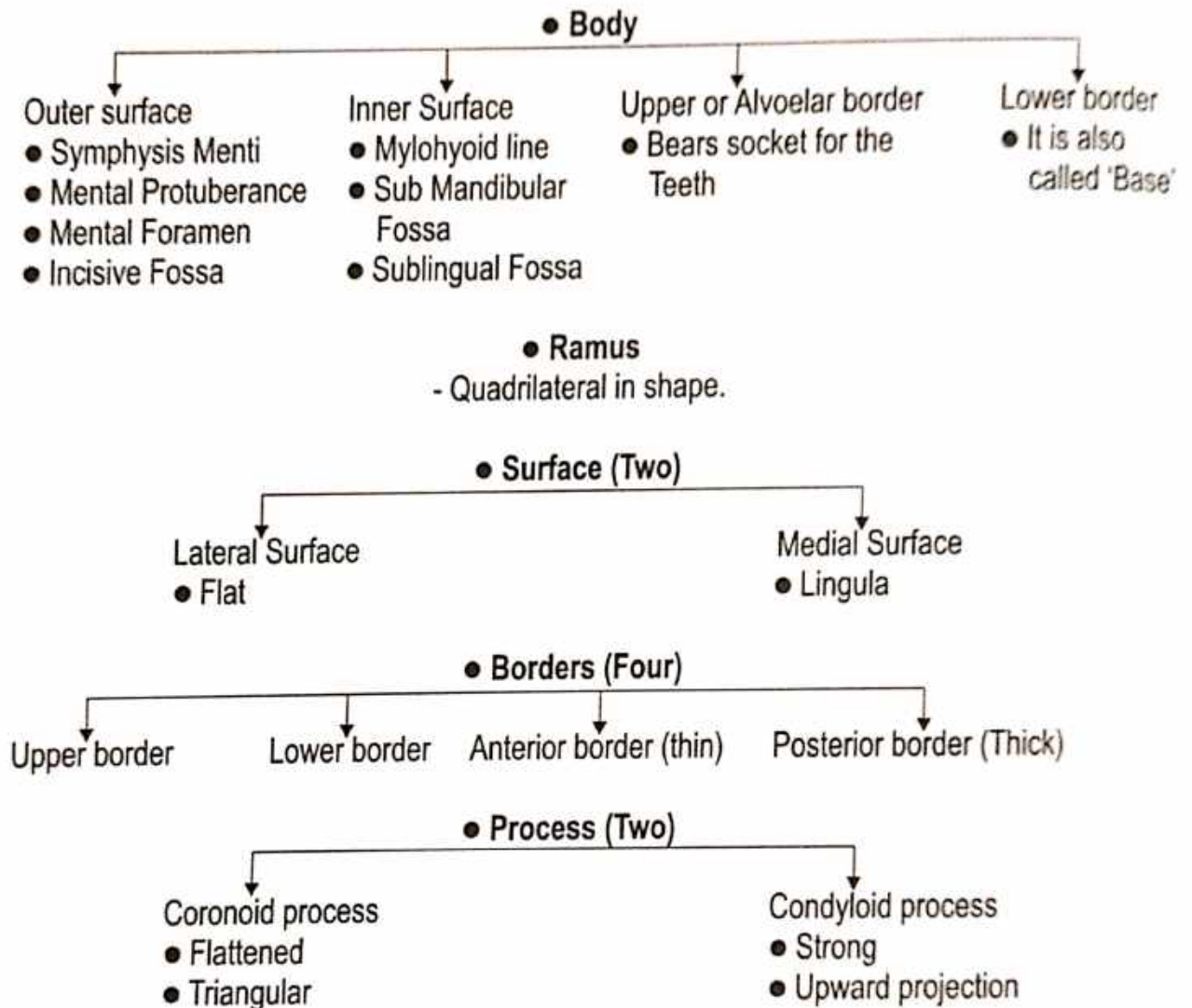
Shape : Largest & deepest Cranial fossa.



## ● MANDIBLE (Lower Jaw)

- Largest and Strongest Bone of the Skull.

Shape - Horse Shoe Shaped



### ● Ossification Centre

- Each half of Mandible Ossifies from only one centre.
- Mandible is the 2<sup>nd</sup> bone to Ossify in the Body at about 6<sup>th</sup> week of Intra Uterine life.



**SYNDESMOLOGY**  
(संघि शास्त्र)

# JOINTS

## ● संधि शरीरम्

● अस्थि संयोगस्थानम् ।

(च.शा. 7/14)

● संधियों की संख्या -

चरकानुसार - 290,

सुश्रुतानुसार - 210,

अष्टांगहृदयानुसार - 2000

Types of Joint -

● According to Ayurveda

त एते सन्धयोऽष्टविधाः -

कोरो-लूखल-सामुद्रग-प्रतर-तुन्नसेवनी-वायसतुण्ड-मण्डल-शंखावर्त्ताः ।

(सु. शा. 5/31)

1. कोर संधि

3. सामुद्रग संधि

5. तुन्नसेवनी संधि

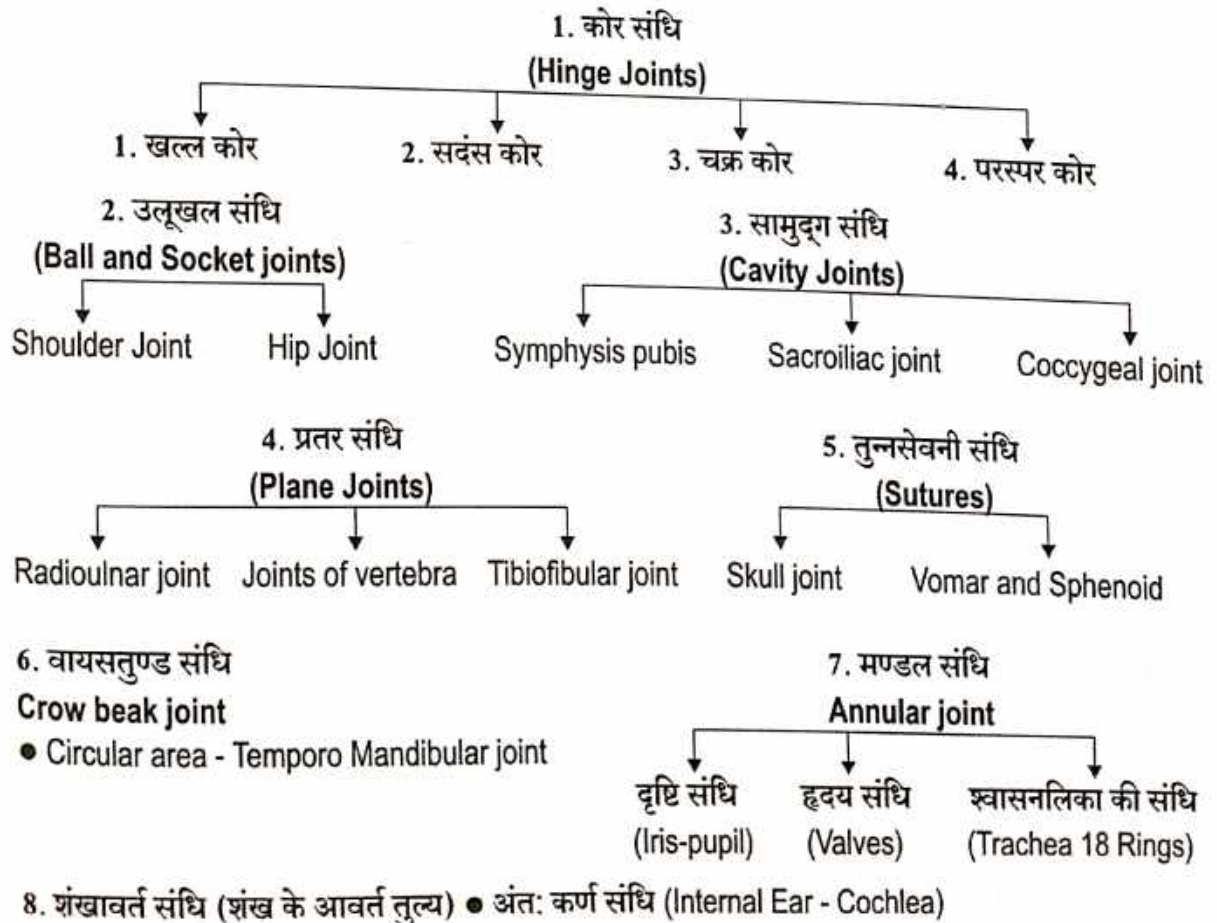
7. मण्डल संधि

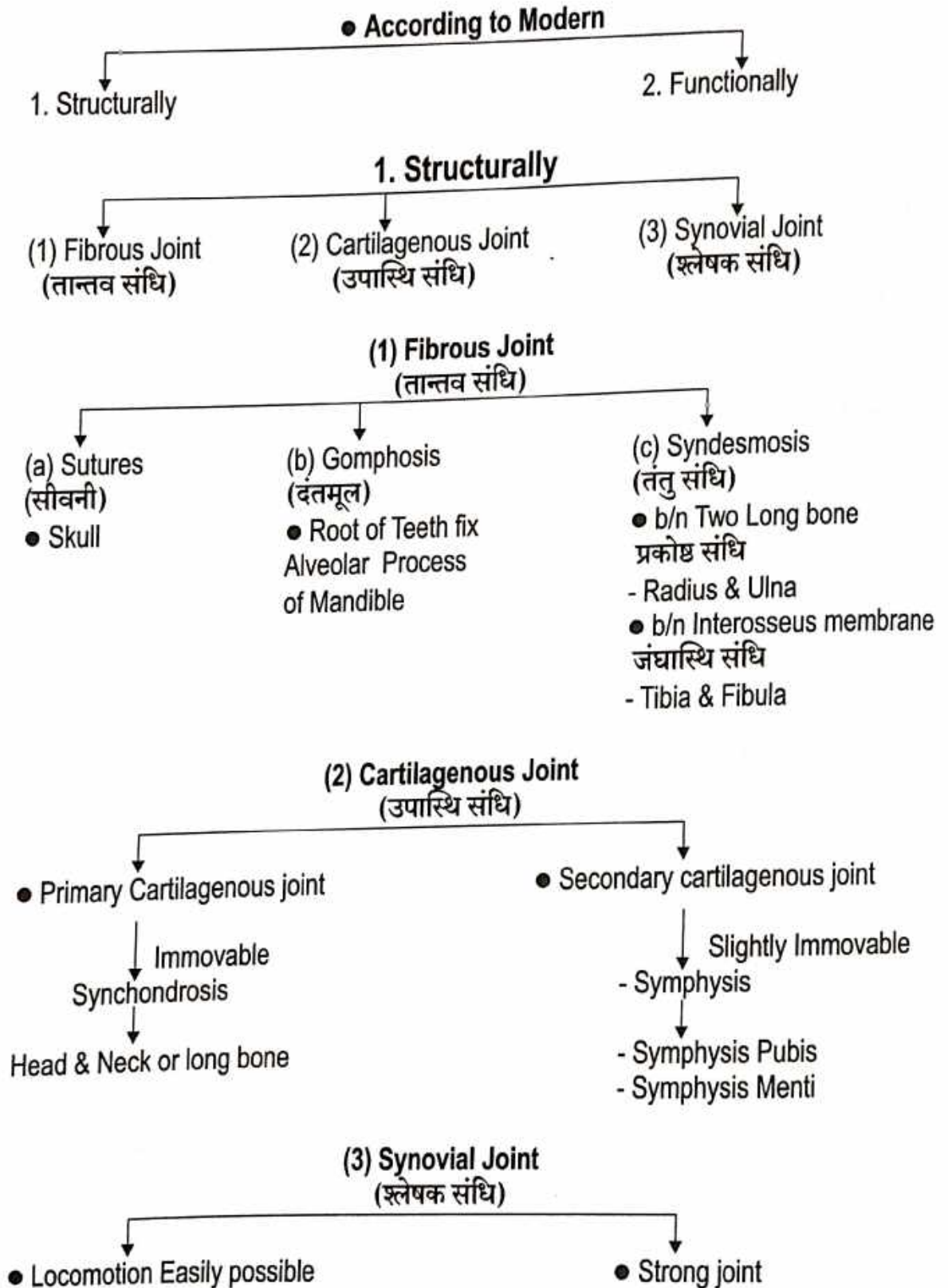
2. उलूखल संधि

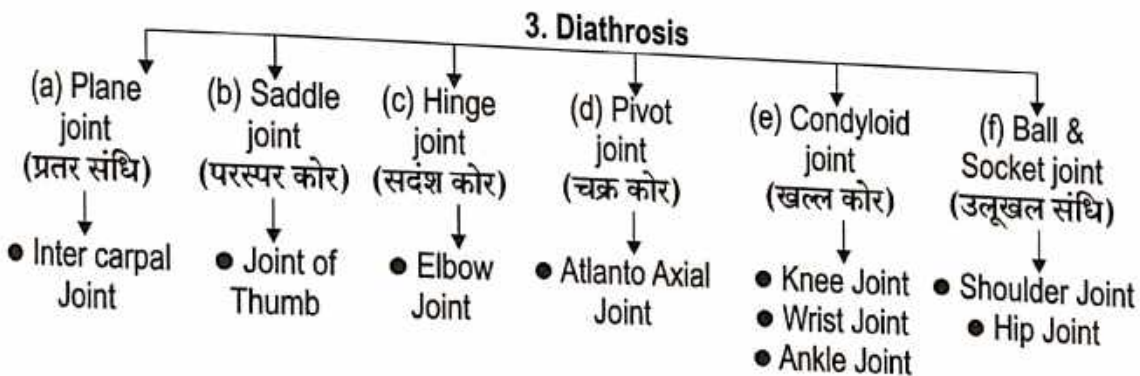
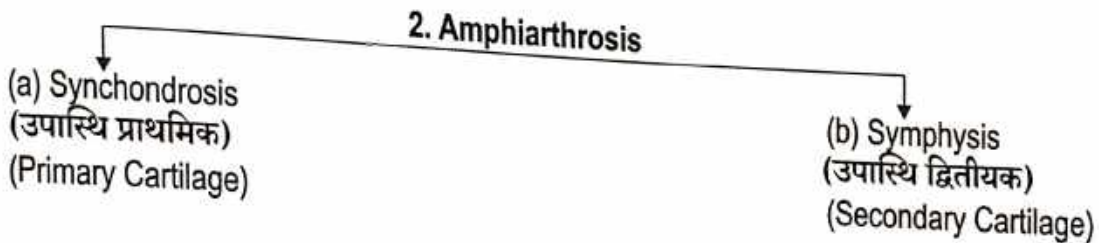
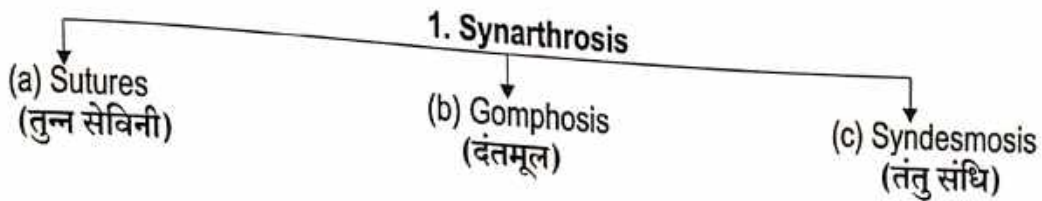
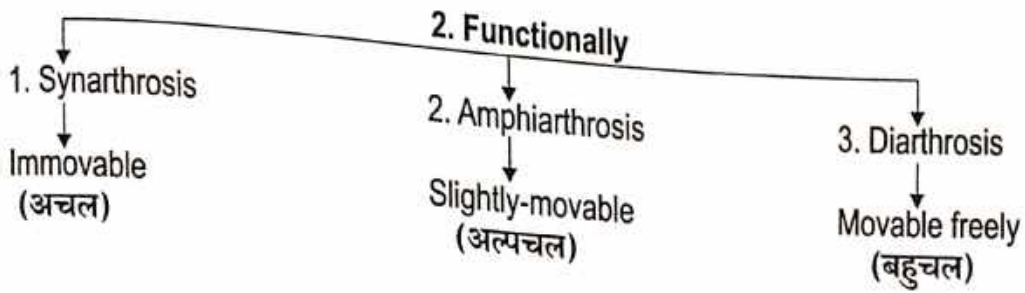
4. प्रतर संधि

6. वायसतुण्ड संधि

8. शंखावर्त संधि







# SOME IMPORTANT JOINTS

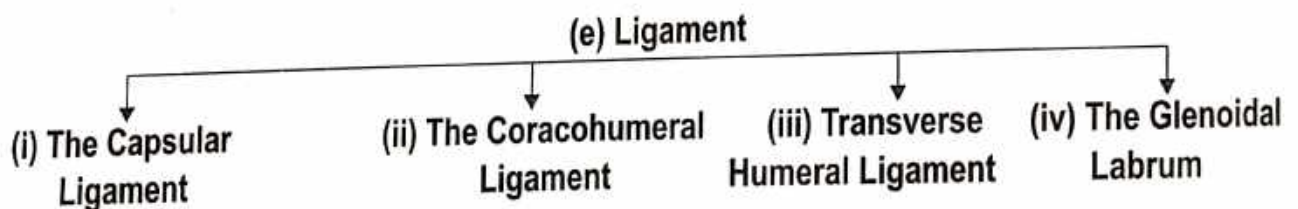
## • Joint of the Upper Limb (1) Shoulder joint OR Gleno-Humeral Joint (अंस सन्धि या कक्षा सन्धि)

(a) **Introduction** - The Anterior Margin of the Glenoid Cavity Corresponds to the Lower half of the Shoulder Joint. It is Marked by a Line 3 cm Long drawn downwards from a point just Lateral to the tip of the Coracoid Process. The Line is Slightly concave laterally.

(b) **Type** - The Shoulder joint is a synovial joint of the Ball and Socket.

(c) **Situation** - Shoulder Girdle.

(d) **Articular surface** - The joint is formed by articulation of the Scapula and the Head of the Humerus therefore, It is also known as the "Glenohumeral Articulation"



(i) **The Capsular ligament** -

- It is very Loose and permits free movement.

- It is a thin, Loose Sac that completely envelops the Joint, It extends from the Glenoid cavity to the Anatomical neck. The inferior part of the capsule is its Weakest Area.

(ii) **The Coraco Humeral ligament** -

- It is a strong broad ligament that strengthens the superior part of the articular capsule and extends from the coracoid process of Scapula to the Greater tubercle of Humerus.

(iii) **Transverse Humeral ligament** -

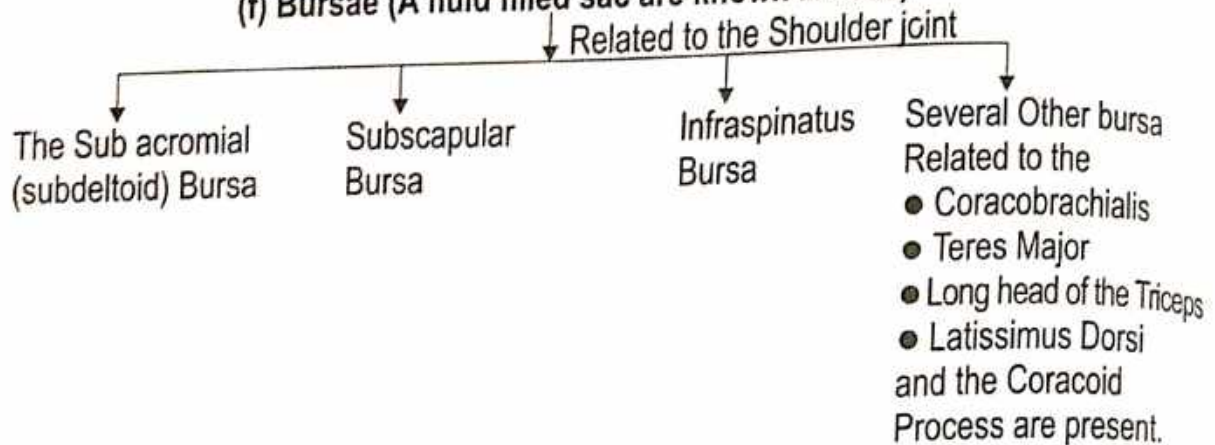
- It bridges the Upper part of the Bicipital groove of the humerus (B/n the Greater and Lesser Tubercles)  
The Tendon of the Long head of the Biceps Brachii passes deep to the Ligament.

(iv) **The Glenoidal Labrum** -

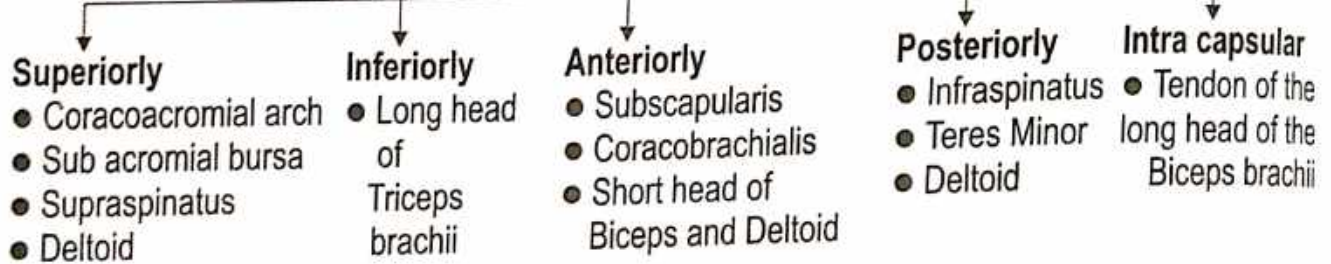
- It is a narrow margin of fibrocartilage around the edge of the Glenoid Cavity.

- It is slightly deepens and enlarges the Glenoid cavity.

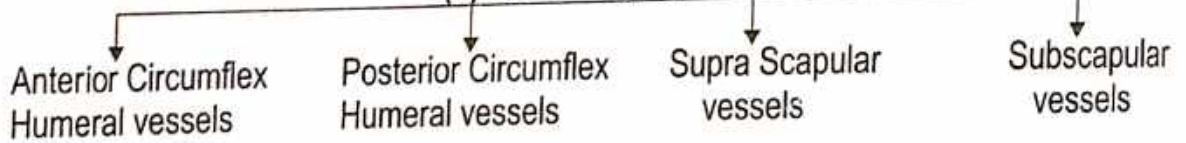
**(f) Bursae (A fluid filled sac are known bursae)**



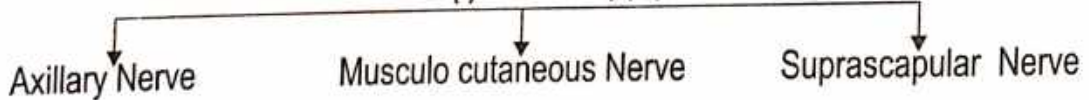
**(g) Relations to the Shoulder joint**



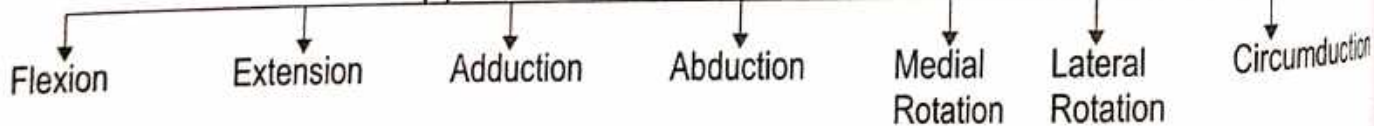
**(h) Blood Supply**



**(I) Nerve Supply**



**(J) Movements at the Shoulder joint**



**(K) Clinical Anatomy -**

- The joint most commonly dislocation in Adult is the Shoulder Joint, Because its Socket is quite Shallow Usually the Head of Humerus becomes displaced Inferiorly .
- Rotator cuff injury is a common Injury.
- Shoulder tip Pain.

## (2) Elbow Joint

(कूर्पर संधि)

(a) **Introduction** - The Joint Line is Situated 2 cm Below the Line Joining The two Epicondyles and slopes are downwards and medially.

(b) **Type** - The Elbow joint is a Synovial joint of the Hinge variety.

(c) **Situation** - At the elbow.

(d) **Articular surface** -

- The joint formed by the lower end of Humerus and the Upper end of Radius and Ulna.
- The Elbow Joint is Continuous with the Superior Radioulnar joint.

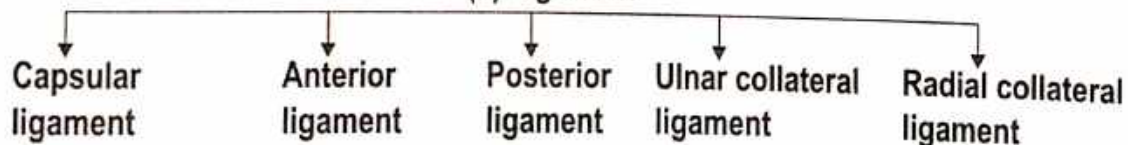
• **Humero-Radial joint** - • The Capitulum of the Humerus Articulates with the concave upper surface of the head of Radius.

• **Humero-Ulnar joint** - • The Trochlea of the Humerus articulates with the Trochlear notch of the Ulna.

• **Superior-Radio-Ulnar joint** - • The Circumference of the head of the Radius articulates with the Radial notch of Ulna.

• **Cubital articulation** - • The Humero-radial, the humero-ulnar and the superior radio-ulnar Joints are Together known as Cubital Articulation.

### (e) Ligament



• **Capsular ligament** - It is attached Lower end of the Humerus, Capitulum, Trochlea, Radial Fossa, Coronoid Fossa, Olecranon Fossa, Trochlear notch of Ulna, Annular ligament of Superior Radio-Ulnar joint.

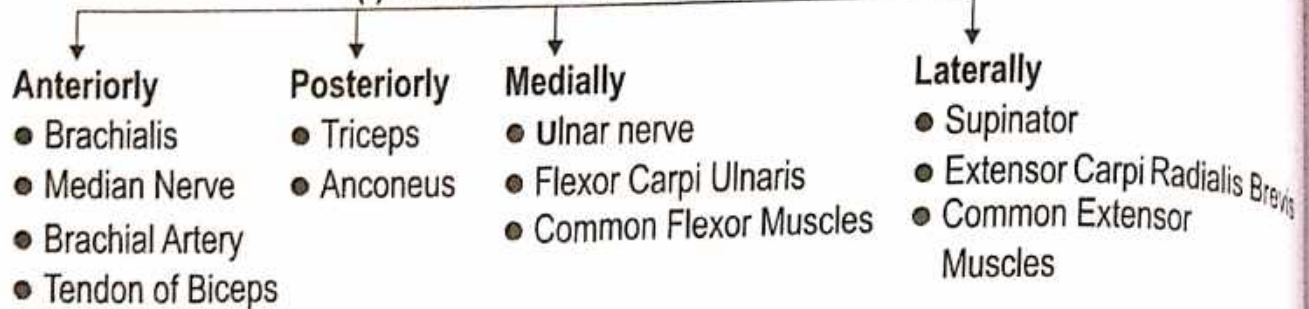
• **Anterior ligament** - It is thickening of the capsule.

• **Posterior ligament** - It is thickening of the capsule.

• **Ulnar Collateral ligament** - • It is triangular in shape  
• Its apex is attached to the Medial epicondyle of Humerus and its base to the Ulna.

• **Radial Collateral ligament** - It is attached at its upper end to the Lateral epicondyle of Humerus and below to the Annular ligament of the Superior Radio-Ulnar joint.

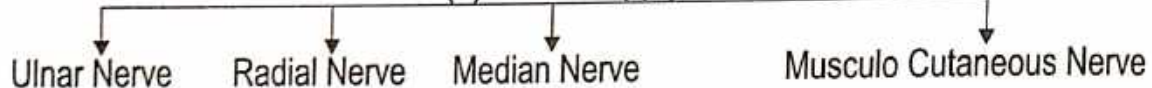
### (f) Relations to the Elbow joint



### (g) Blood Supply

From the Anastomosis around the Elbow joint (Branches of Brachial, Radial and Ulnar artery)

### (h) Nerve Supply



### (I) Movement at the Elbow joint



### (J) Clinical Anatomy -

- (i) **Distension** - Distension of the Elbow Joint by an Effusion occurs posteriorly because here the capsule is weak and the covering deep fascia is thin, Aspiration is done posteriorly on any side of the Olecranon Process.
- (ii) **Dislocation** - Dislocation of the Elbow is Usually posterior, and is often Associated with the Fracture of the Coronoid Process.
- (iii) **Subluxation** - Subluxation of the head of the Radius occurs in children when the forearm is suddenly pulled in pronation. The head of the Radius slip out from the Annular ligament.
- (iv) **Tennis Elbow** - Abrupt Pronation may lead to pain and tenderness over the lateral epicondyle.  
This is possible due to -
  - Sprain of Radial Collateral Ligament
  - Fearing of fibres of the Extensor Carpi Radialis Brevis.
- (v) **Student's Elbow OR Mineri's Elbow** - It is characterized by Effusion into the bursa over the Subcutaneous posterior surface of the Olecranon process.
- (vi) **Carrying Angle** -
  - It is the angle between the long axis of the Arm and that of Forearm.
  - It is open outwards and measures about 163 Degree.
  - It is cause by the following factors -
    - (1) Medial edge of Trochlea projecting 6 mm below its lateral end.
    - (2) Obliquity of Articulating surface of the Coronoid process.



### (3) Wrist joint OR Radiocarpal Joint (मणिबन्ध संधि)

(a) Introduction - The joint line is obtained by joining the Styloid Processes of the Radius and Ulna. It is convex upwards. The Joint neither communicates with the inferior Radioulnar joint nor with the Intercarpal Joints.

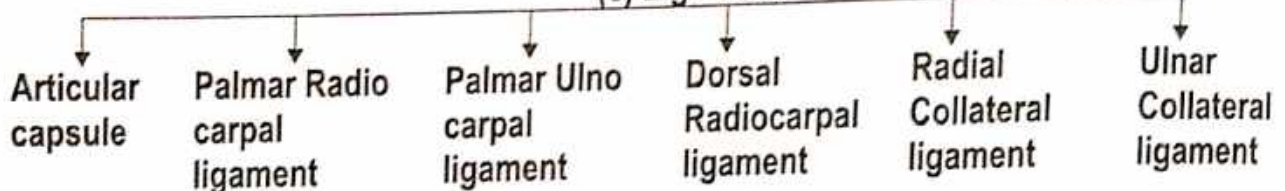
(b) Type - This is a Synovial joint of the Ellipsoid variety.

(c) Situation - At the wrist.

(d) Articular surface -

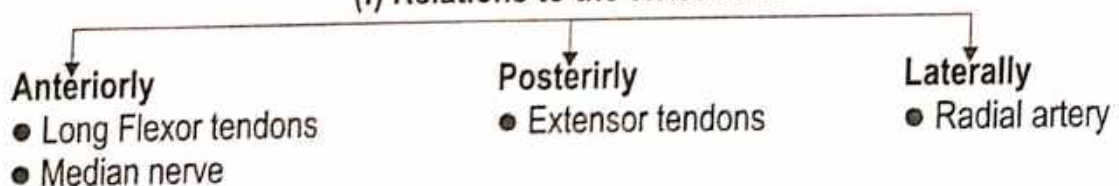
- The Joint formed by the Lower end of Radius and three lateral bones of proximal row of carpals.
- Inferior surface of the lower end of Radius and articular disc of the Inferior Radio ulnar joint articulates with the proximal surface of Scaphoid, Lunate and Triquetral bones.

#### (e) Ligament

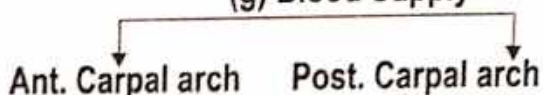


- Articular capsule - Surrounds the joint.
- Palmar Radio carpal ligament - Anterior part of capsule is thickened in its lateral part.
- Palmar Ulna carpal ligament - Anterior part of capsule is thickened in its medial part.
- Dorsal Radio carpal ligament - Posterior part of capsule is thickened in its lateral part.
- Radial Collateral ligament - It is attached proximally to the Styloid process of the Ulna and distally to the Medial side of the Triquetral bone.
- Ulnar Collateral ligament - It is attached proximally to the Styloid Process of the Ulna and distally to the Medial side of the Triquetral bone.

#### (f) Relations to the Wrist Joint



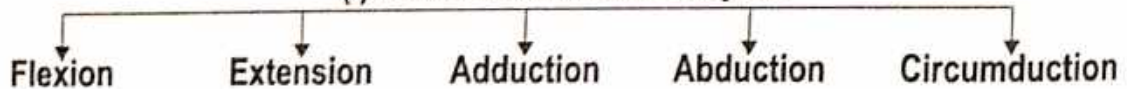
#### (g) Blood Supply



#### (h) Nerve Supply



#### (i) Movements at the wrist joint



#### (J) Clinical Anatomy -

- The wrist Joint is commonly involved in Rheumatoid Arthritis. (R.A.) In which collagen tissue is mostly Affected.
- The back of the wrist is the common site for a Ganglion. It is a cystic swelling resulting from Mucoïd Degeneration of connective tissue of the joint capsule.
- Wrist drop is Indicated Radial nerve Injury.
- Smith's Fracture - A fall of the dorsum of the wrist may cause the reversed called Smith's fracture Reduction is an alongs but with Immobilization with the wrist in same extension.

**• The Joints of the Lower Limbs**  
**(1) Hip Joint or coxal joint**  
 (रज्जुवा संज्ञित)

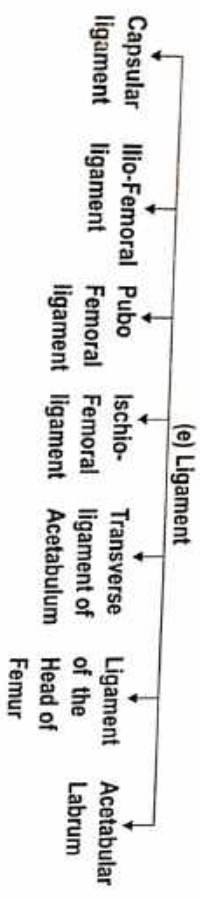
(a) **Introduction** - The weight-bearing joints of the Lower limb are more stable. Hip joint allows the same movement as the mobile shoulder joint, but the range of movement is restricted.

(b) **Type** - Hip Joint is the Ball and Socket variety of Synovial Joint (Multiaxial).

(c) **Situation** - At the Pelvic Region.

(d) **Articular surface** - (i) Joint formed by the head of the Femur and the Acetabulum of the Hip Bone.


- (ii) The Hip Joint is unique in having a high degree of stability as well as Mobility. The Stability or strength depends upon -
- Depth of the Acetabulum and the narrowing of its mouth by the Acetabular Labrum.
  - Tension and Strength of Ligaments.
  - Strength of the Surrounding Muscles.
  - Length and obliquity of the Neck of the Femur.
  - **Atmospheric pressure** - A fairly wide range of Mobility is possible because of the fact that the Femur has a Long neck which is Narrower than the equatorial diameter of the Head.



- **Capsular ligament** - It is Strong Ligament.
- It is attached to Acetabulum, Neck of Femur, Greater Trochanter, Lesser Trochanter, Trochanteric line and Trochanteric Crest.
- The capsule is strengthened by the Presence of three Ligaments.

• **Ilio-Femoral ligament** - It is "Y" Shaped Ligament. It is attached by Anterior Inferior iliac spine to Medial band-Lower part of Trochanteric line and Lateral band-Upper part of Trochanteric line.

- **Pubo Femoral ligament** - Superior Ramus of Pubis to Medial band of Ilio femoral Ligament.
- **Ischio Femoral ligament** - Ischium to Greater Trochanter of Femur.
- **Transverse ligament of Acetabulum** - Bridge across the Acetabular Notch.
- **Ligament of Head of the Femur** - Fovea on the Head of Femur to Acetabular notch.
- **Acetabular Labrum** - Acetabulum is increased by the presence of rim of fibrocartilage called Acetabular Labrum.

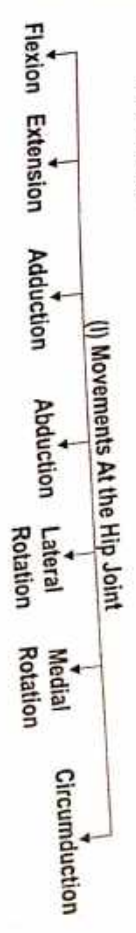
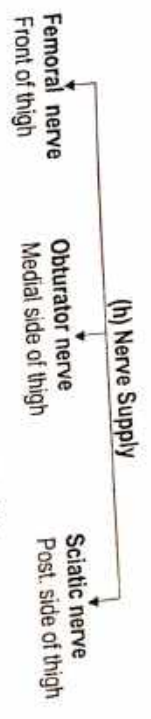



**Anterior Relation** - Tendon of the Iliopsoas separated from the joint by a bursa and Femoral vein, Femoral artery and Femoral nerve.

**Posterior Relation** - The Joint, from below upwards, is related to the following Muscles - Tendon of Obturator Externus covered by the Quadratus Femoris, Obturator Internus and Gemelli, Piriformis, Sciatic nerve and the Gluteus Maximus muscle.

**Superior Relation** - Reflected head of the Rectus Femoris covered by the Gluteus Minimus, Gluteus Medius and partly by Gluteus Maximus. Lateral fibres of the Pectineus and the Obturator Externus. In Addition there are Gracilis, Adductors Longus, Brevis, Magnus and Hamstring Muscles.

**Inferior Relation** -



**(J) Clinical Anatomy -**

● **Developmentally -**

1. **Congenital Dislocation -**

Congenital dislocation is more common in the hip than in any other joint of the body.

2. **Perthe's Disease (Pseudocoxalgia) -** Perthe's disease or Pseudocoxalgia is characterized by destruction and flattening of the head of the Femur, with an increased joint space in X-ray pictures.

3. **Coxa vara -**

Coxa vara is a condition in which the Neck-Shaft angle is Reduced from the Normal angle of about  $150^{\circ}$  in a Child, and  $127^{\circ}$  in an Adult.

● **Injuries -**

1. **Dislocation of the Hip -**

Dislocation of the hip may be Posterior (more common), Anterior (less common), or central (rare). The Sciatic nerve may be injured in Posterior dislocations.

2. **Fracture of Neck of Femur -** Fracture of the neck of Femur are common in Old age also Called Senile Degeneration.

● The sciatic nerve may be damage in Posterior dislocation

● Osteoarthritis is a disease of Old age - Painful movement.

● **Aspiration of the Hip joint -** Aspiration of the hip joint can be done by passing a needle from a point 5 cm below the Anterior superior iliac spine, upwards, backwards and medially. It can also be done from the side by Passing the needle from the posterior edge of the Greater Trochanter, upwards and medially, parallel with the Neck of the Femur.

● **Disease of the Hip bone -** Disease of the hip bone (like T.B.) may Caused Referred pain in the knee because of the common nerve supply of the Joint.

● **Shenton's line -**

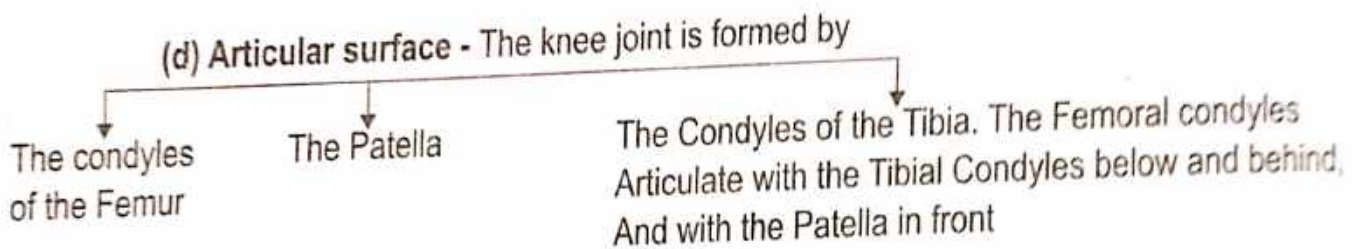
Is a continuous curve formed by the upper border of the Oburator Foramen and the Lower border of the Neck of the Femur.

## 2) Knee Joint or Tibio Femoral Joint (जानु संधि)

(a) **Introduction** - The knee is the largest and Most Complex Joint of the Body. The complexity is the result of articulation of three joints in one. It is formed by articulation B/N Lateral Femorotibial, Medial Femorotibial, and Femoropatellar Joints.

(b) **Type** - It is Condylar synovial Joint, Incorporating two Condylar Joints between the condyles of the Femur and Tibia, and one saddle joint between the Femur and the Patella. It is also a Complex Joint as the cavity is divided by the Menisci.

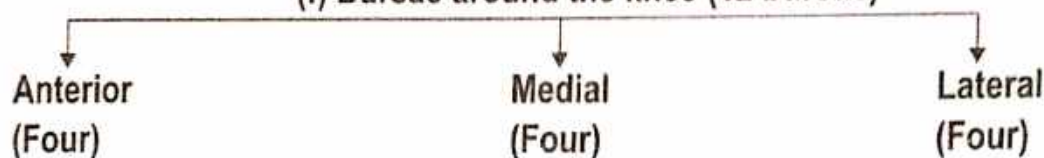
(c) **Situation** - At the knee.

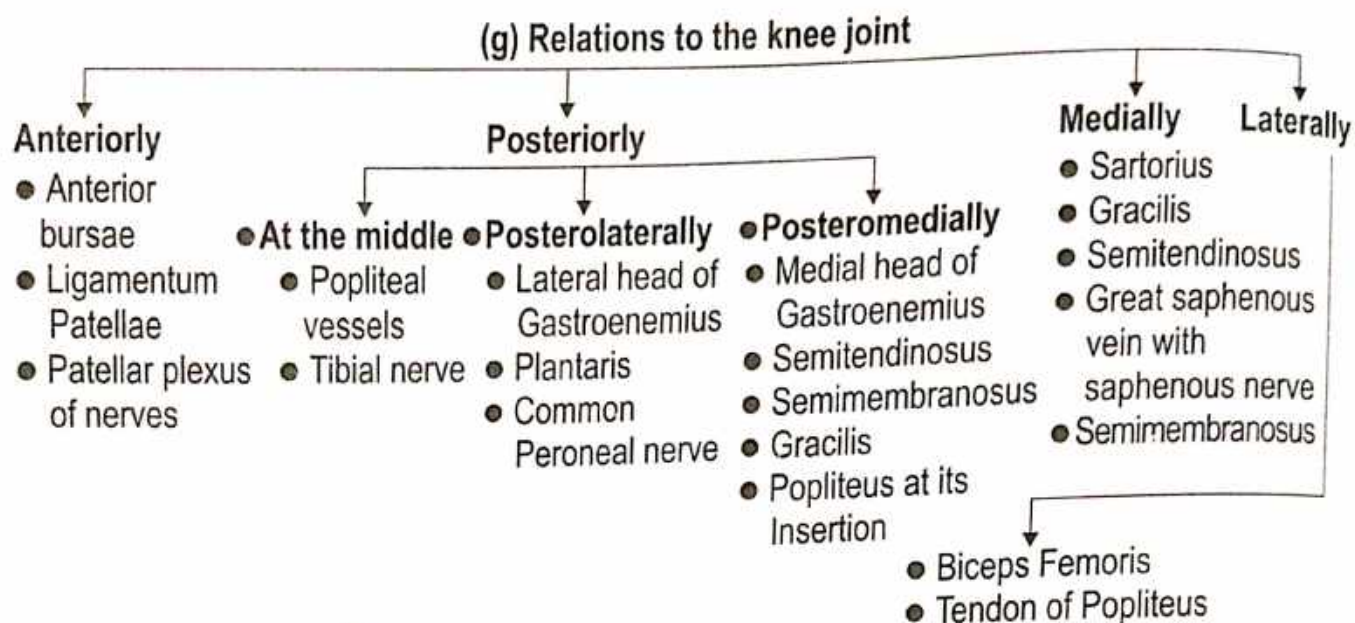


(e) **Ligament**

- |                                |  |
|--------------------------------|--|
| 1. Articular Capsule           | - Capsular ligament is weak and thin.  |
| 2. Ligamentum Patellae         | - are fused tendons of the Quadriceps Femoris muscles.   |
| 3. Oblique Popliteal ligament  | - Lateral condyle of Femur to fibrous capsule.   |
| 4. Arcuate Popliteal ligament  | - Lateral condyle of Femur to Styloid Process of Head of Fibula.   |
| 5. Tibial Collateral ligament  | - Medial condyle of Femur to Medial Condyle of Tibia.  |
| 6. Fibular Collateral ligament | - Lateral condyle of Femur to head of Fibula.  |
| 7. Anterior Cruciate ligament  | - Lateral condyle of Femur to Inter-condylar area of Tibia.  |
| 8. Posterior Cruciate ligament | - Medial condyle of Femur to Inter-condylar area of Tibia.   |
| 9. Medial Meniscus             | - The Medial Meniscus is nearly semicircular, being wider behind than in front.  |
| 10. Lateral Meniscus           | - The Lateral Meniscus is nearly Circular. The posterior end of the meniscus is attached to the Medial condyle of Femur through two Meniscoefemoral Ligaments. |
| 11. Transverse ligament        | - It Connects The Anterior ends of the Medial and Lateral menisci.   |

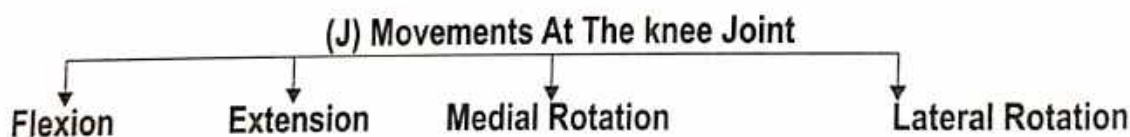
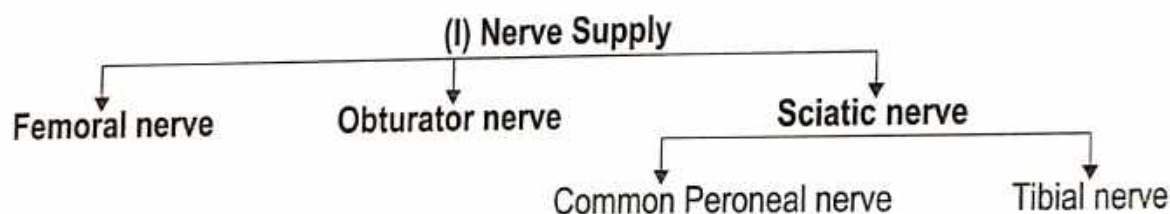
(f) **Bursae around the knee (12 bursae)**





**(h) Blood Supply**

1. Five Genicular branches of the Popliteal artery.
2. The Descending Genicular branch of the Femoral artery.
3. The Descending branch of the Lateral Circumflex Femoral artery.
4. Two Recurrent branches of the Anterior Tibial artery.
5. The Circumflex Fibular branch of the Posterior Tibial artery.



**(K) Clinical Anatomy -**

- Osteoarthritis is an Age related Cartilage Degeneration of the Articular Surfaces.
- Structurally, The knee is a weak Joint because the Articular surfaces are Not congruent.
- The Stability of the Joint is Maintained by a number of factor's -
  - (i) The Cruciate Ligaments Maintain Anteroposterior Stability.
  - (ii) The Collateral Ligaments Maintain side to side Stability.
  - (iii) The factors strengthening the capsule have been enumerated earlier.
  - (iv) The Iliotibial tract plays an important role in stabilizing the knee.
- **Injuries to the Collateral Ligament** - Less Common and may be produced by severe Abduction and Adduction Strains.
- **Injuries to the Cruciate Ligament** - are common. The Anterior Cruciate Ligament is more common then the Posterior Ligament.
- **Injuries to the Meniscus** - are commonly produced by the twisting in a slightly flexed knee as in kicking knee.

### 3) Ankle Joint or Talo-Crural Joint (गुल्फ संधि)

(a) Introduction - The Ankle Joint is the strong joint. The Stability of the Joint due to -

- Close interlocking of the articular surface.
- Strong collateral Ligaments on the side.
- The tendons cross the joint 4 in front and 5 in behind.

(b) Type

- The ankle joint is a synovial joint of the hinge variety.

(c) Situation

- At the ankle.

(d) Articular surface - (i) The upper articular surface is formed by -

- The lower end of the Tibia including the Medial Malleolus.
- The lateral Malleolus of the Fibula.
- The Inferior Transverse Tibiofibular ligament. These structures form a deep socket

(ii) The inferior articular surface is formed by articular areas on the upper, medial and lateral aspects of the Talus.

#### (e) Ligament

Fibrous Capsule    The Deltoid or Medial Ligament    A Lateral Ligament

● Fibrous Capsule - It Surrounds the Joint.

● The Deltoid or Medial Ligament - It is a very strong Triangular ligament. Present on the Medial side of the Ankle.

● It is divided two part

Superior part

Deep part

Anterior fibres  
Tibio-Navicular

Middle fibres  
Tibio-Calcanean

Posterior fibres  
Posterior Tibio Talur

Anterior Tibio-Talar

● A Lateral ligament - This ligament consists of three bands

Anterior Talo-Fibular ligament

Posterior Talo-Fibular ligament

Calcaneo-Fibular ligament

#### (f) Relations to the Ankle Joint

Anteriorly

(From medial to lateral side)

- Tibialis Anterior
- Extensor Hallucis Longus
- Anterior Tibial vessels
- Deep Peroneal nerve
- Extensor Digitorum Longus
- Peroneus Tertius

Posteromedially

(From Medial to Lateral side)

- Tibialis Posterior
- Flexor Digitorum Longus
- Posterior Tibial vessels
- Tibial nerve
- Flexor Hallucis Longus

Posterolaterally

- Peroneus Longus
- Peroneus Brevis

(g) Blood Supply - ● Anterior Tibial artery

- Peroneal artery ● Posterior Tibial artery

(h) Nerve Supply - ● Deep Peroneal nerve ● Tibial nerve

(i) Movements at the Ankle joint - ● Dorsi flexion

- Planter flexion

#### (J) Clinical Anatomy -

- Dislocations & Sprains of Ankle
- Foot drop - Injury to common Peroneal nerve.
- Injury to the Tibia & Fibula in the Ankle are Referred to as Pott's Fracture
- (i) Fracture of Lateral Malleolus.
- (ii) Fracture of Medial Malleolus.
- (iii) Injury to Medial Ligament.
- (iv) Injury to Interosseus Tibiofibular Ligament.

## ● The Joint of the Skull Temporo-Mandibular Joint (T.M.J.) (हनुसंधि)

(a) **Introduction** - The Temporo-Mandibular Joint is the joint of jaw and is frequently Referred to as TMJ.

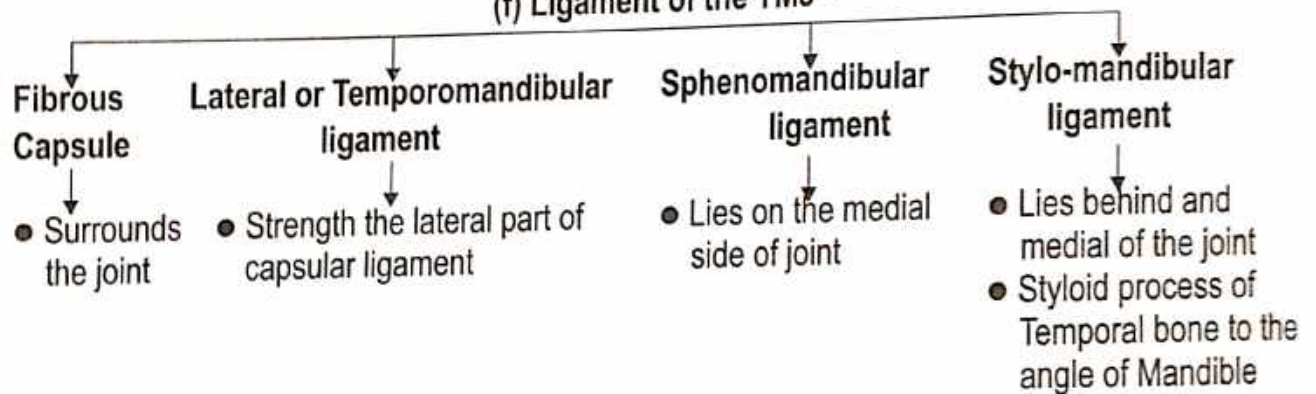
(b) **Type** - ● TMJ is a synovial joint of the condylar variety.  
● The TMJ is the only movable joint of the skull. All other skull joint are fibrous in type, (sutures) and therefore immovable.

(c) **Situation** - At the skull.

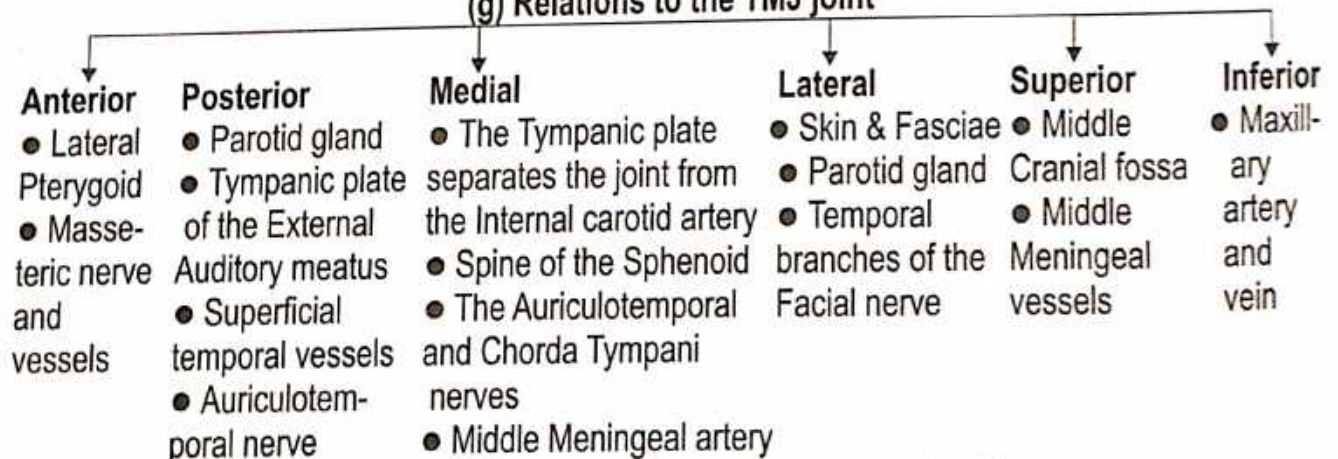
(d) **Articular surface** - ● Articulation of the Mandible with the Temporal bone.  
● The Condylar process of the Mandible articulate with the mandibular fossa and articulating tubercle of the Temporal bone.  
● The articular surfaces are covered with fibrocartilage. The joint cavity is divided into upper and lower parts by an intra-articular disc.

(e) **Articular Disc** - The Articular disc is an oval fibrous plate that divides the joint into an upper and a lower compartments.

### (f) Ligament of the TMJ -



### (g) Relations to the TMJ joint



(h) **Blood Supply (Branches from)** - ● Superior Temporal artery ● Maxillary artery

(i) **Nerve Supply** - ● Auriculotemporal nerve ● Masseteric nerve

(j) **Movements At the TMJ Joint** - ● Depression ● Elevation ● Protraction ● Retraction ● Lateral

(k) **Clinical Anatomy** -

- **Dislocation of Mandible** - During Excessive Opening of the Mouth or During a convulsion.
- **In operation on the joint** - The Seventh Cranial nerve should be preserved with care.
- **Dearrangement of the articular disc** - Dearrangement of the articular disc may result from any Injury, Like overclosure or malocclusion. This gives rise to clicking and pain during movements of the jaw.

# **SPLANCHNOLOGY**

**प्रत्यंता शास्त्र**



# RESPIRATORY SYSTEM

## Lungs

Lungs : ● According to Ayurveda - फुफ्फुस

Origin : ● According to Ayurveda.  
 (क) शोणितफेनप्रभवः फुफ्फुसः । (सु.शा. 4/24)  
 (ख) रक्तफेनात् फुफ्फुसम् । (अ. सं. शा. 5/48)  
 (ग) फुफ्फुसो रक्तफेनजः । (अ.ह.शा. 3/12)

● According to Modern - Mesoderm.

System of Organ : Respiratory System

स्रोतस : प्राणवह स्रोतस

Situation : In the Thoracic Cavity.

● तस्याधो वामतः प्लीहा फुफ्फुसश्च दक्षिणतो यकृत क्लोम च (सु.शा. 4/30)

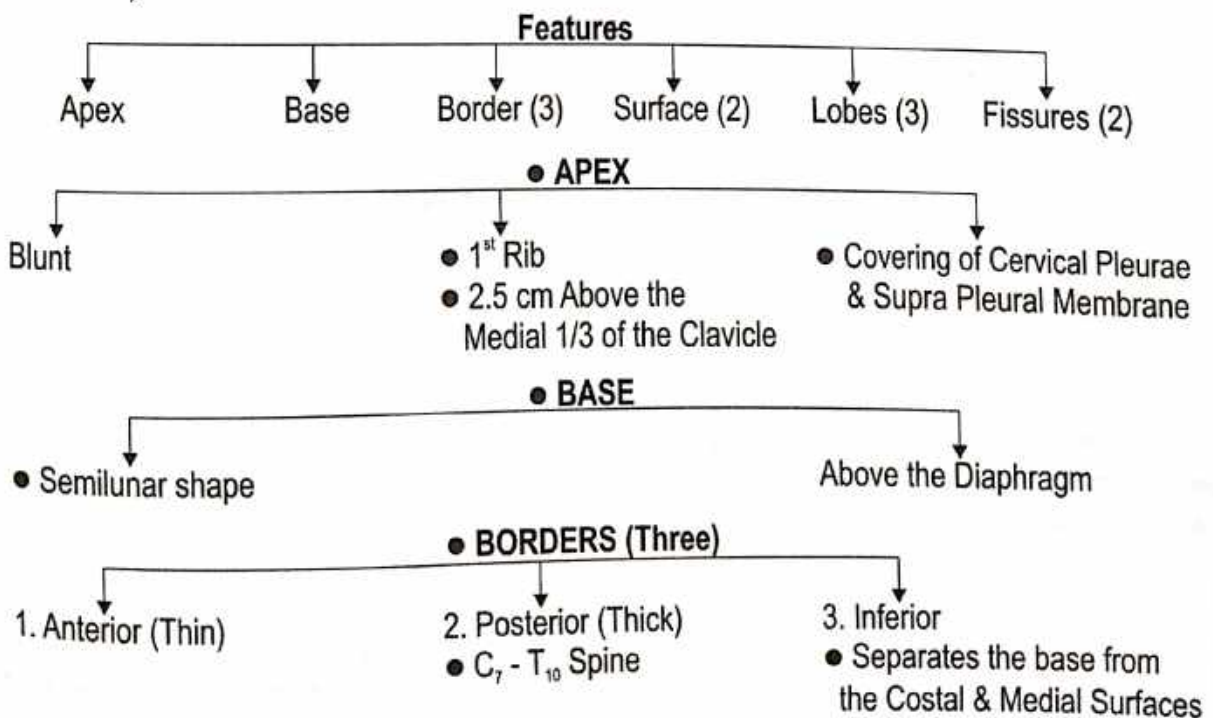
● तस्य (हृदयस्य) दक्षिणतः क्लोम यकृत फुफ्फुसमास्थितम् (अ.ह.शा. 3/12)

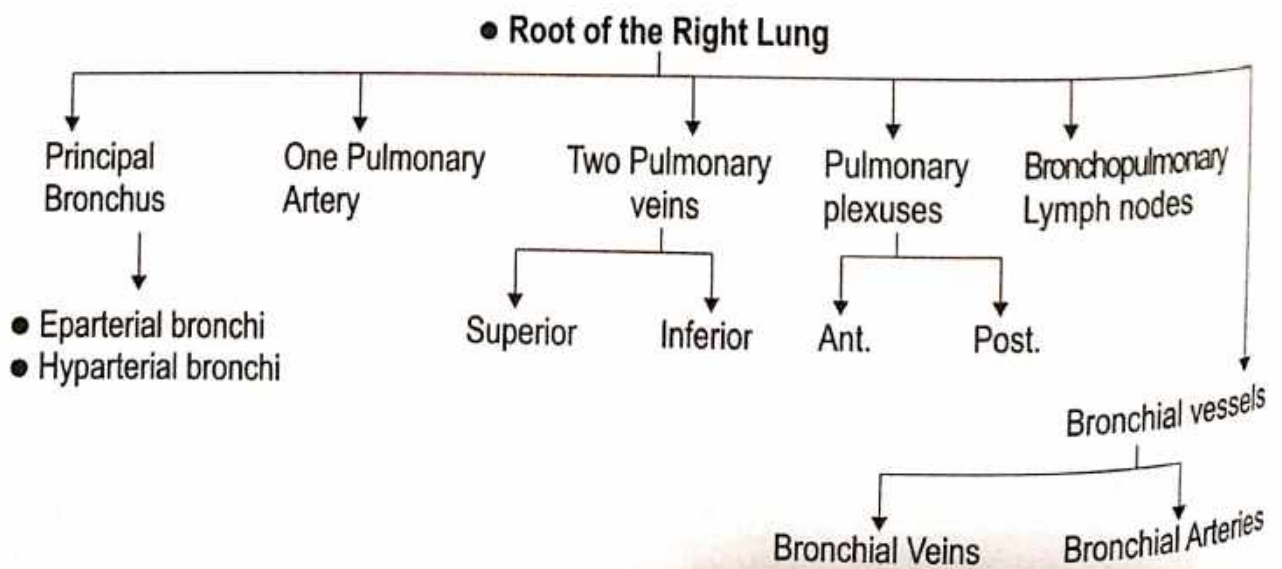
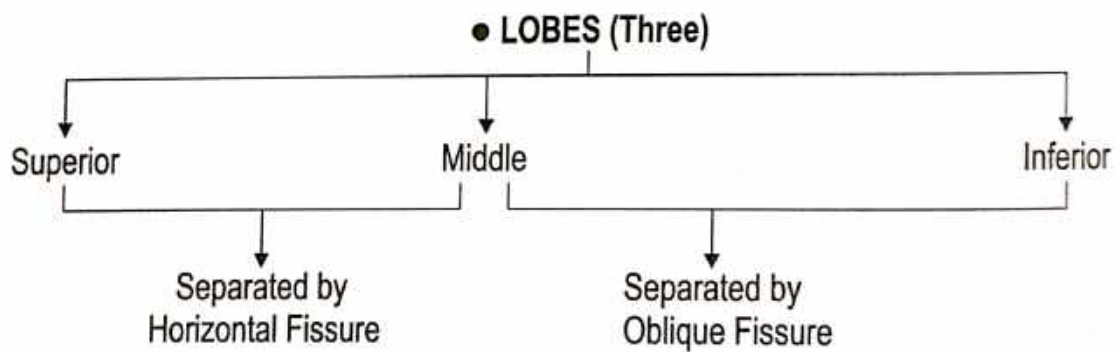
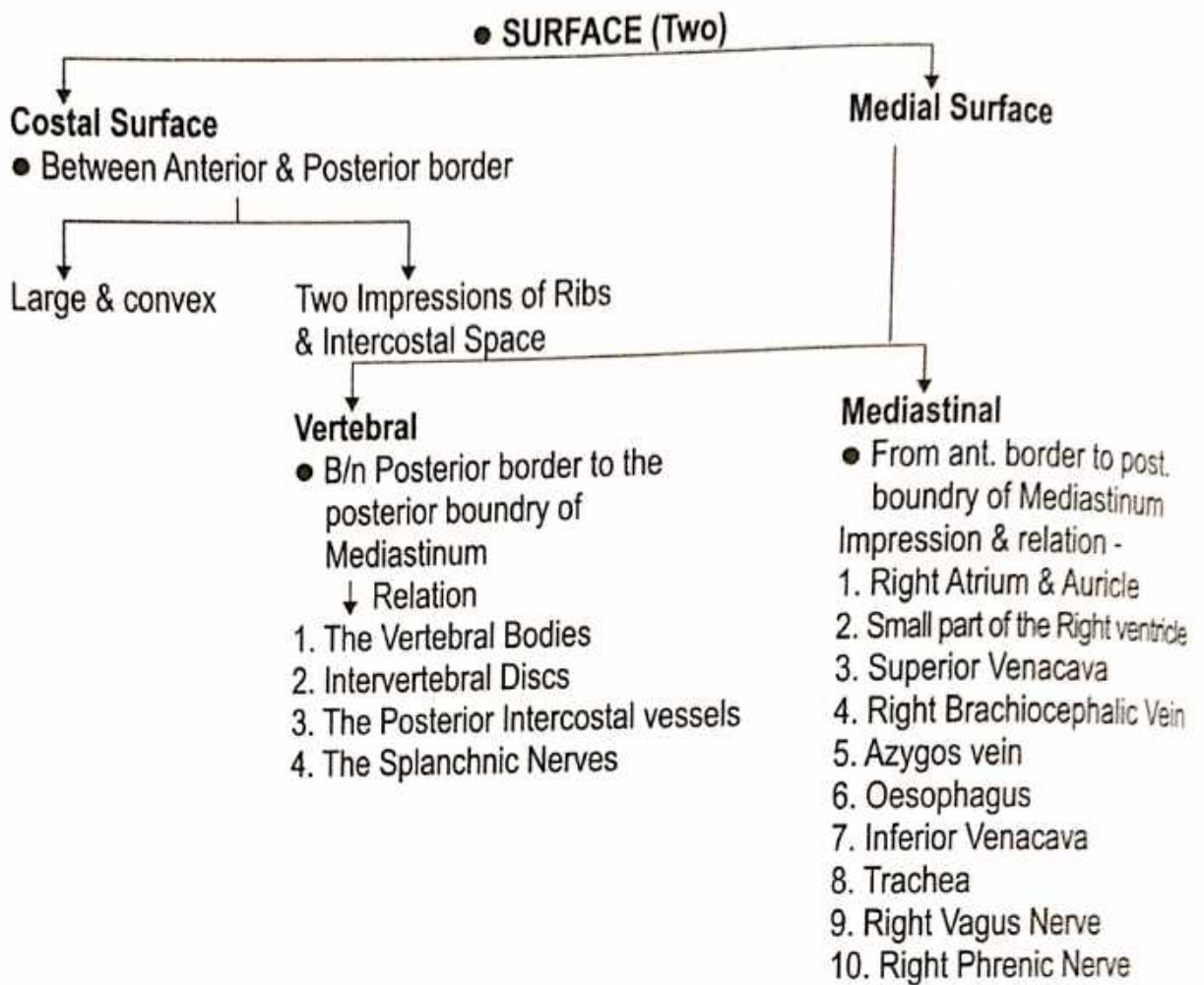
General Features :

- Number - Two
- Shape - Conical
- Weight - Right Lung = 625 gm, Left Lung = 565 gm
- Colour - Child = Pink Colour, Young = Brown or Grey.
- Texture - Spongy

### ● RIGHT LUNG

● Shorter and Broader

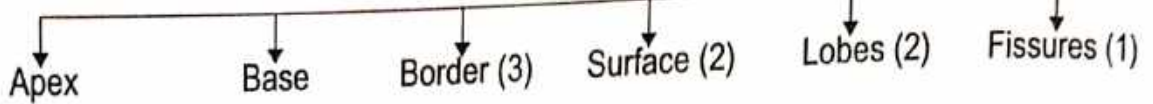




**• LEFT LUNG**

• Longer and Narrower


**• Features**



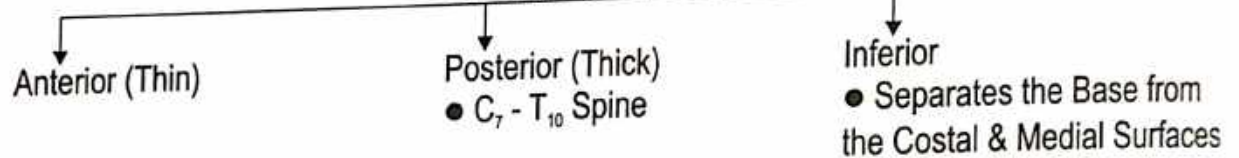
**• APEX**



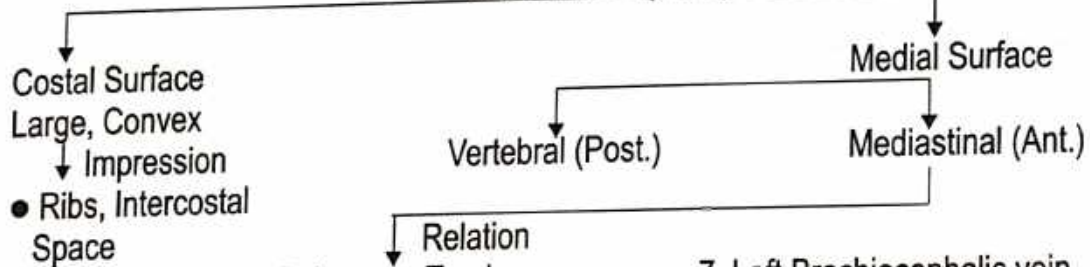
**• BASE**



**• BORDERS (Three)**

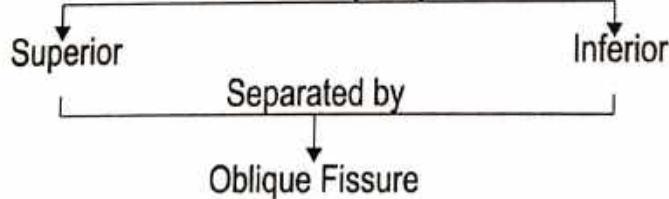


**• SURFACE (Two)**

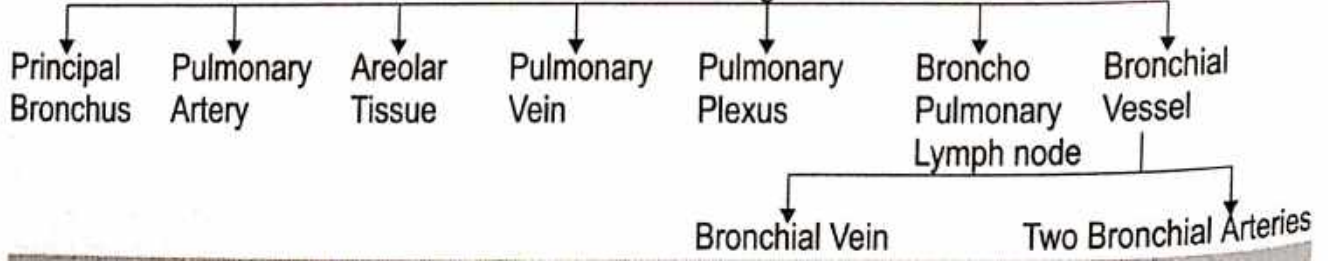


- Relation
- |                              |  |
|------------------------------|--|
| 1. Pulmonary Trunk           | 7. Left Brachiocephalic vein   |
| 2. Arch of Aorta             | 8. Left Vagus nerve  |
| 3. Descending Thoracic Aorta | 9. Left Phrenic nerve  |
| 4. Left Subclavian artery    | 10. Left Recurrent Laryngeal nerve   |
| 5. Thoracic Duct             | 11. Left Ventricle, Left Auricle, Infundibulum adjoining part of the Right Ventricle |
| 6. Oesophagus                |  |

**• LOBES (Two)**



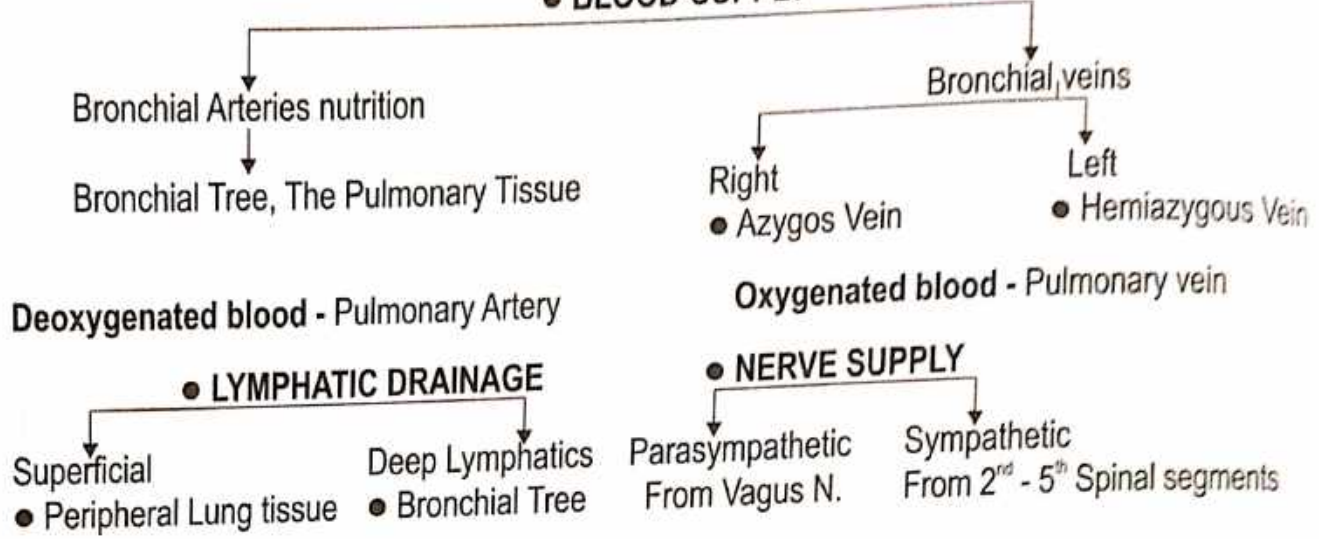
**Root of Left Lung**



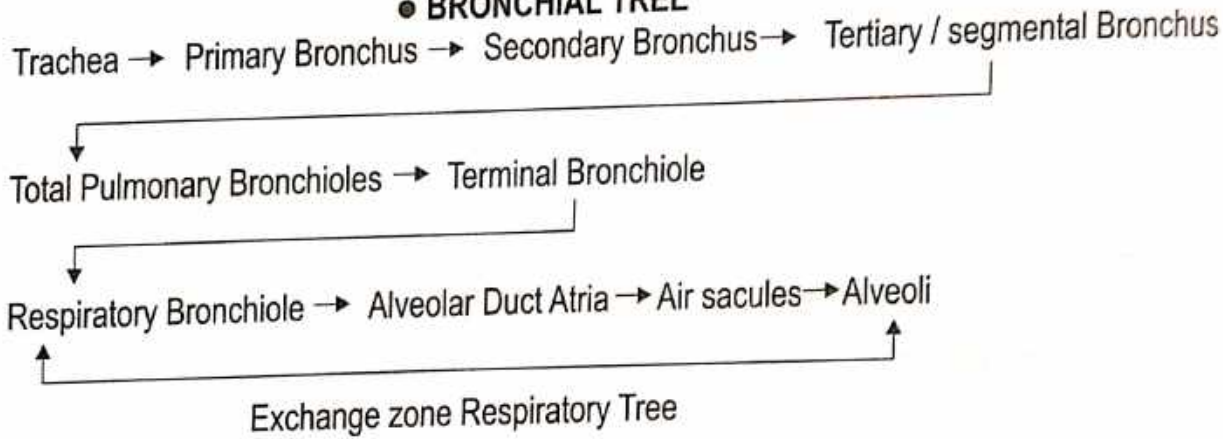
● **LINGULA**

The Tongue shaped projection of the left lung below the Cardiac Notch is called the Lingula.

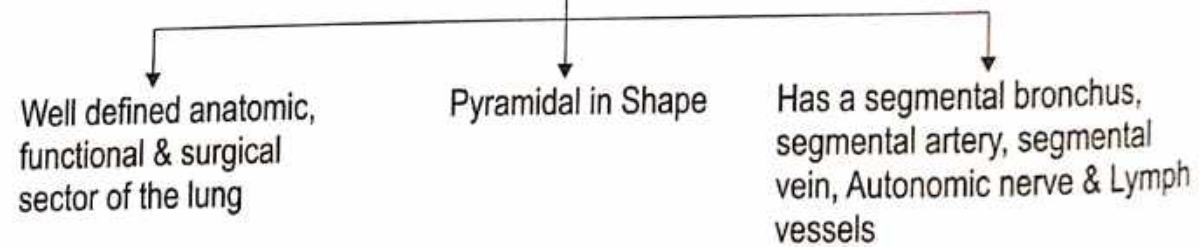
● **BLOOD-SUPPLY**



● **BRONCHIAL TREE**



**Bronchopulmonary Segments**



**Bronchopulmonary segment of the Right Lung**

- Upper lobe
  - Apical
  - Posterior
  - Anterior
- Middle lobe
  - Lateral
  - Medial
- Lower lobe
  - Superior
  - Anterior basal
  - Medial basal
  - Lateral basal
  - Posterior basal

● **Bronchopulmonary segment of the Left Lung**

- Upper lobe
  - Apical
  - Posterior
  - Anterior
  - Superior Lingular
  - Inferior Lingular
- Lower lobe
  - Superior
  - Medial basal
  - Anterior basal
  - Lateral basal
  - Posterior basal

# Diaphragm

**Name :** ● According to Ayurveda - महाप्राचीरा

**Shape :** Dome shape

**Position :** B/n the Thoracic & Abdominal cavities.

**Origin :** Muscles fibres may be grouped into 3 parts

**1. Sternal part**

● Arises from the back of Xiphoid process.

**2. Costal part**

● Arises from the inner surface of Cartilages

**3. Lumber part**

● Arises from the Medial Lateral lumbo Costal arches.

**Insertion :** Diaphragm is inserted into the edge of the Central Tendon

**Features :**

● **Arcuate Ligament (Two)**

**Medial**

● Covering the Psoas Major muscle

**Lateral**

● Covering the Quadratus Lumborum Muscle.

● **Crus (Two)**

**Right**

● Large, Strong  
- Arises from the Upper 3 Lumber Vertebrae

**Left**

● Short  
- Arises from the Upper Two Lumber Vertebrae

**Openings in the Diaphragm :**

**1. Large or Main Opening**

**1. Aortic Opening**

It transmits

- Aorta
- Thoracic Duct
- Azygos Vein

**2. Oesophageal Opening**

It transmits

- Oesophagus
- Gastric or Vagus Nerve
- Left Gastric Artery

**3. Venacaval opening**

It transmits

- Inferior Venacava
- Right Phrenic Nerve

● **2. Small Opening**

1. Greater and Lesser Splanchnic Nerves

2. Subcostal Nerve & Vessels

3. Superior Epigastric Vessels

4. Musculo Phrenic Vessels

5. Sympathetic Chain

● **Relation**

● **Superiorly**

- 1. Pleurae
- 2. Pericardium

● **Inferiorly**

- 1. Peritoneum
- 2. Liver
- 3. Fundus of Stomach
- 4. Spleen
- 5. Kidneys
- 6. Suprarenal Glands

● **Nerve Supply :**

● **Motor**

Phrenic nerve

Phrenic nerves to the central part

● **Sensory**

Lower six Thoracic Nerves to the Peripheral part

# CIRCULATORY SYSTEM

## HEART

Name : ● According to Ayurveda - हृदय

Situation : According to Ayurveda -  
तस्याधो वामतः प्लीहा फुफ्फुसश्च दक्षिणतो यकृत क्लोम च,  
तद्विशेषेण चेतनास्थानम्

(सु.शा. 4/30)

According to Modern - Middle Mediastinum

Origin : Ayurveda - शोणितकफप्रसादजं हृदयं ।  
"रक्त और कफ के प्रसाद से"

- सु. शा. 4/30

Modern - Mesoderm.

System of Organ : Circulatory System

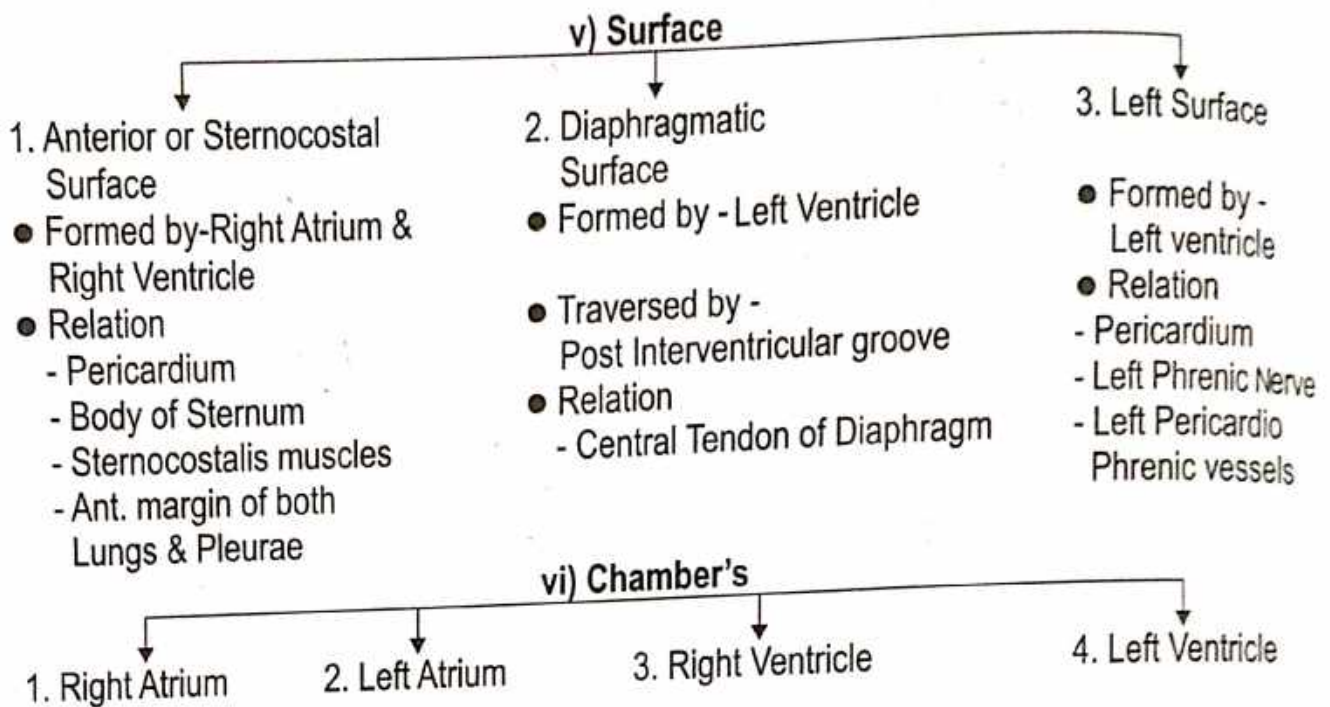
स्रोतस : रस वह स्रोतस, रक्तवह स्रोतस.

General Features : ● Shape - Conical → [ पुण्डरीकेण सदृशं हृदयं स्यादधोमुखम् ।  
● Size - जाग्रतस्तद्विकसति स्वपतश्च निमीलति । (सु.शा.4/31) ]  
i) Length = 12 cm      iii) Thickning = 6 cm  
ii) Breadth = 8-9 cm      iv) Weight= ● Male - 300 gm ● Female - 250 gm

### ● External Features

- i) Grooves or sulci    ii) Base    iii) Apex    iv) Border    v) Surface    vi) Chamber's

|  |  |
|--|--|
| <b>i) Grooves or sulci -</b>   | <b>ii) Base -</b>  |
| 1. Coronary sulcus (Atrioventricular sulcus)<br>2. Inter Atrial groove.<br>3. Anterior Interventricular groove.<br>4. Posterior Interventricular groove. | Formed by - Left Atrium (small part Right Atrium)<br>Relation - Thoracic vertebra ( $T_5 - T_8$ )<br>Separated from - Pericardium, Right Pulmonary vein, Oesophagus & Aorta.         |
| <b>iii) Apex -</b>   | <b>iv) Borders -</b>   |
| Formed by - Left ventricle.<br>Direction - Downward & Forward.<br>Relation - 6 <sup>th</sup> Intercostal space,<br>Left Lung & Pleura.                   | 1. Upper border - Formed by Two Atria.<br>2. Right border - Formed by Right Atrium.<br>3. Inferior border - Formed by Right ventricle.<br>4. Left border - Formed by Left ventricle. |



### RIGHT ATRIUM

- Receives venous blood from whole body & pumps into Rt. Ventricle

#### External Feature :-

- i) Auricle covers root of Ascending Aorta.
  - ii) Right border of Atrium - Shallow Vertical groove called "Sulcus Terminalis"
- It produced by internal muscular ridge called "Crista Terminalis", upper part of the sulcus contain SA node or sinuatrial node (Pacemaker of heart)

#### Internal Features :- 3 Parts

- 
- ```

graph TD
    A["Internal Features :- 3 Parts"] --> B["1. Sinus Venarum (Smooth Post. part)"]
    A --> C["2. Pectinate Part (Rough Ant. part)"]
    A --> D["3. Inter atrial Septum"]
    
    B --- B_desc["i) Upper end - Superior Venacava  
ii) Lower end - Inf. Venacava guarded by - Eustachian Valve  
iii) Coronary sinus b/n Inferior Venacava & Tricuspid orifice  
iv) Venae cordis minimi  
v) Intervenous Tubercle"]
    
    C --- C_desc["Muscular ridge arised from Crista Terminalis called = 'Musculi Pectinati' (like teeth of comb)"]
    
    D --- D_desc["i) Fossa Ovalis - Saucer shaped, Shallow depression  
ii) Limbus Fossa Ovalis or Annulus Ovalis (margin of fossa Ovalis)"]
  
```
1. Sinus Venarum (Smooth Post. part)
    - i) Upper end - Superior Venacava
    - ii) Lower end - Inf. Venacava guarded by - Eustachian Valve
    - iii) Coronary sinus b/n Inferior Venacava & Tricuspid orifice
    - iv) Venae cordis minimi
    - v) Intervenous Tubercle
  2. Pectinate Part (Rough Ant. part)
 

Muscular ridge arised from Crista Terminalis called = 'Musculi Pectinati' (like teeth of comb)
  3. Inter atrial Septum
    - i) Fossa Ovalis - Saucer shaped, Shallow depression
    - ii) Limbus Fossa Ovalis or Annulus Ovalis (margin of fossa Ovalis)

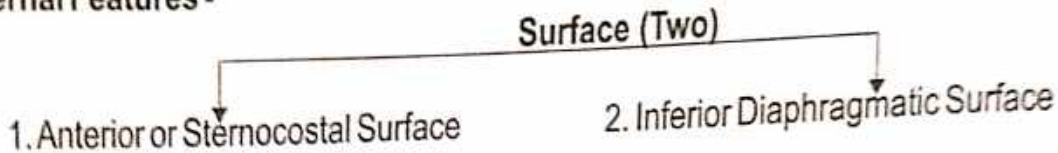
#### Inlets of the Right Atrium -

1. Superior venacava
2. Inferior venacava
3. Coronary Sinus
4. Anterior cardiac Veins
5. Venae cordis minimi (Thebesian veins)
6. Right marginal Veins

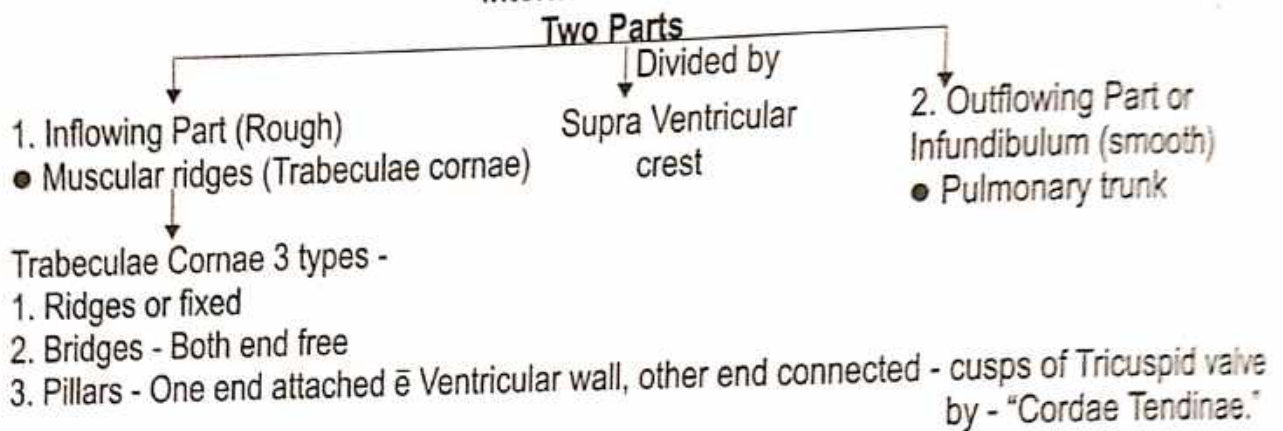
## ● RIGHT VENTRICLE

- Triangular Chamber.
- Receives blood from Right Atrium through Tricuspid valve & pumps into lungs through Pulmonary Trunk & Arteries. (Deoxygenated blood).

### External Features -



### Internal Features -



### Orifice (Two)

- ```

    graph TD
      Orifice[Orifice (Two)] --> Atrioventricular[1. Right Atrioventricular or Tricuspid orifice guarded by - Tricuspid Valve]
      Orifice --> Pulmonary[2. Pulmonary Orifice guarded by - Semilunar Valve]
  
```

- Right Ventricle wall is thinner than left ventricle wall in ratio 1:3.

## ● LEFT ATRIUM

- Situated - Posteriorly base of Heart
- Receives Oxygenated blood from lungs through 4 Pulmonary Veins & pumps into Left ventricle, through Bicuspid or Mitral valve.

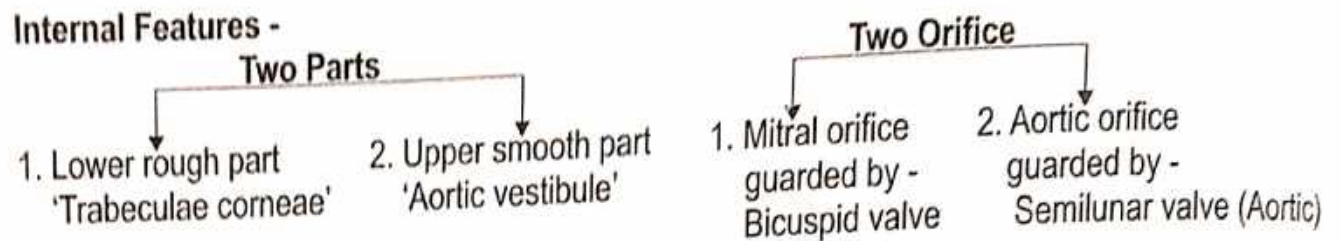
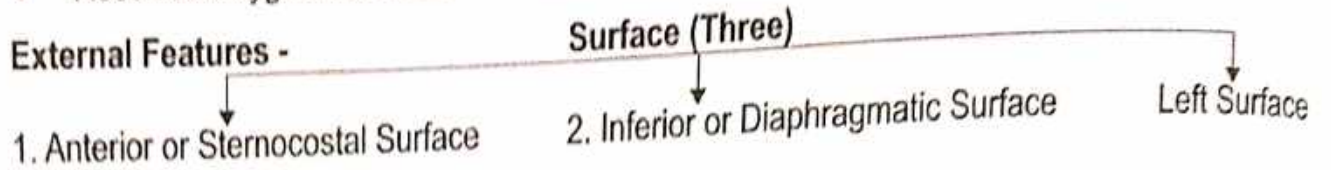
- External Features -**
- Posterior surface.
  - Anterior wall.
  - 4 Pulmonary Vein.

- Internal Features -**
1. Bicuspid opening.
  2. Musculi pectinati.
  3. Interior Atrium - Smooth walled.
  4. Septal wall shows "Fossa Lunata".



## ● LEFT VENTRICLE

- Conical Shape chamber (Apex of Heart).
- Receives Oxygenated blood from Left Atrium through Bicuspid valve & pumps into Aorta.



- Cavity of Left ventricle "Circular" in cross section.
- Left Ventricle wall three times thicker than right ventricle.

## Valves of Heart

1. Two pairs Atrioventricular Valves (Right & Left).
2. Semilunar valve (Aortic & Pulmonary)

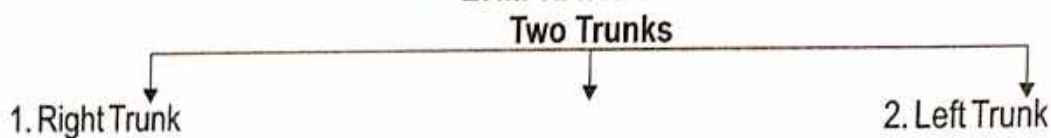
## Conducting System

1. **Sinoatrial node or SA node** - 'Pacemaker of Heart', impulse rate - 70/min situated Atrio caval junction in upper part of Sulcus Terminalis. Impulse travels AV node through atrial wall.
2. **Atrioventricular or AV node** - 'Paceseter of Heart', impulse rate - 60/min situated lower & dorsal part of atrial septum, just above the coronary sinus.
3. **Bundles of His** - Muscular connection B/n Atrial & Ventricular musculatures. Upper border of the muscular part of septum, it divided into right & left branches, reaches RT & LT Ventricles.
4. **Purkinje Fibres** - Form a Subendocardial plexus.

● **ARTERIAL SUPPLY** - ● **Two Coronary arteries** : (Right & Left)

● **VENOUS SUPPLY** - 1. Coronary sinus 2. Ant. cardiac veins 3. Venae cordis minimi

## ● LYMPHATIC SUPPLY



## ● NERVE SUPPLY



Both Parasympathetic & Sympathetic nerves form superficial & deep cardiac plexuses.

# DIGESTIVE SYSTEM

## STOMACH

**Name :**

- According to Ayurveda - आमाशय
- According to Modern - Stomach

**Origin :** Endodermal

**System of Organ :** Digestive System

**Situation :**

- Lies Obliquely in Left Part of Abdomen Occupying the Epigastric, Umbilical & Left Hypochondriac regions

- Most of It lies Under cover of the Left Costal margin and the Ribs.

- तत्राप्यामाशयो विशेषेण पित्त स्थानम् ।

(च.सू. 20/8)

- तत्र आमाशयः चतुर्विधस्याहारस्याधारः ।

(सू.सू. 21/12)

- आमाशयः पित्ताशयस्योपरिष्ठात् ।

(सु.सू. 21/12)

- आमाशय श्लेष्मणः ।

(सु.सू. 21/6)

- नाभिस्तनान्तरं जन्तोरामाशय इति स्मृतः ।

(च.वि. 2/17)

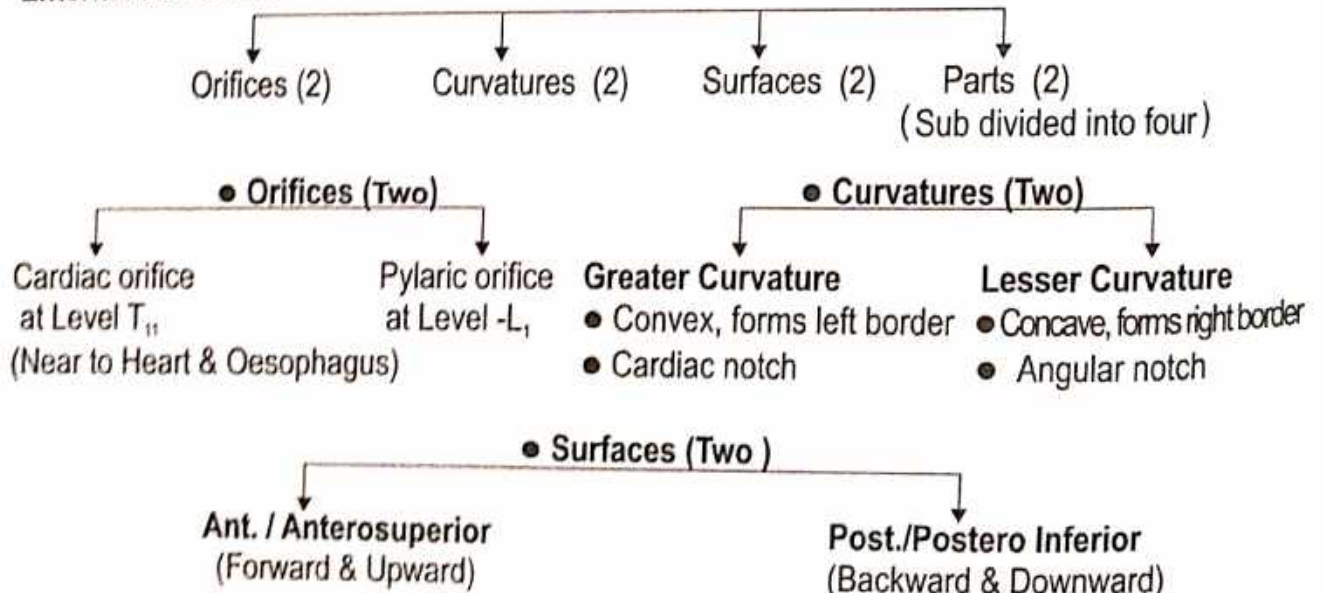
**Shape :** Empty = J-shaped  
Partially distend = Pyriform

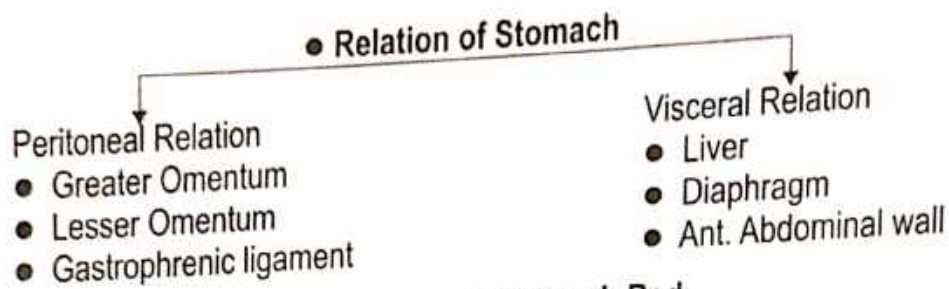
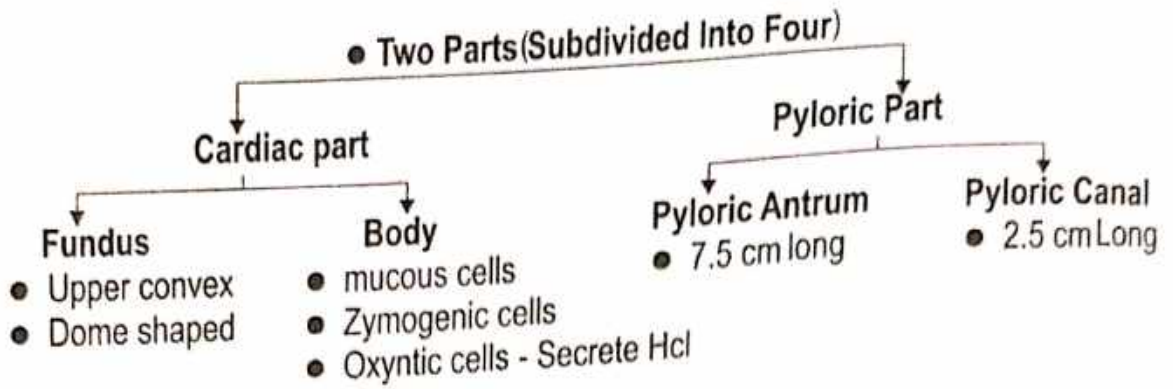
**Size :** 25 cm long

**Mean Capacity**

|         |                 |
|---------|-----------------|
| Birth   | : 30 ml         |
| Puberty | : 1000 ml       |
| Adult   | : 1500-2000 ml. |

**External Features :**





● Stomach Bed

(1) Diaphragm (2) Left kidney (3) Left Suprarenal gland (4) Pancreas (5) Transverse Mesocolon (6) Splenic Flexure of the Colon (7) Splenic artery (8) Sometimes the Spleen is also Included.

● Interior of Stomach

1. The mucosa - Folds term as Gastric rugae.
2. Submucosa Coat - Connective tissue arterioles.
3. Muscular coat - Longitudinal & Circular
4. Serosa coat - Peritoneal Covering.

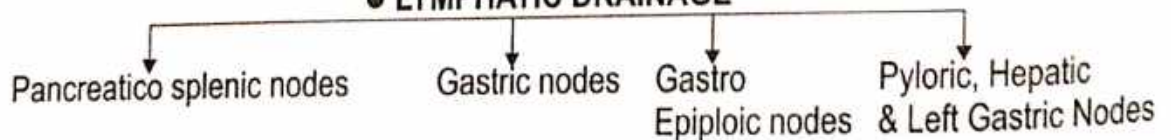
● BLOOD SUPPLY

- Left Gastric Artery.
- Right Gastric Artery.
- Right Gastroepiploic Artery.
- Left Gastroepiploic Artery.
- Branches of Splenic Artery (five to seven Short Gastric artery).


● VENOUS DRAINAGE

Veins drain Into Portal, Superior Mesentric & Splenic vein.

● LYMPHATIC DRAINAGE



● NERVE SUPPLY



## LIVER

**Name :** ● According to Ayurveda - यकृत  
● According to Modern - Liver

**Synonym :** Hepar

**Origin :** ● According to Ayurveda

गर्भस्य यकृत् शोणितजौ ।

(सु.शा. 4/25)

● According to Modern - Endoderm

द्वितीया रक्तधरानाम मांसस्याभ्यन्तरतः, तस्यां शोणितं ।  
विशेषतश्च सिरासु यकृतप्लीहोश्च भवति ॥

(सु.शा. 4/9)

**स्त्रोतस :** रक्तवहे द्वै, तयोर्मूलं यकृतप्लीहानौ रक्तवाहिन्यश्च धमन्यः

(सु.शा. 9/16)

**Shape :** Wedge

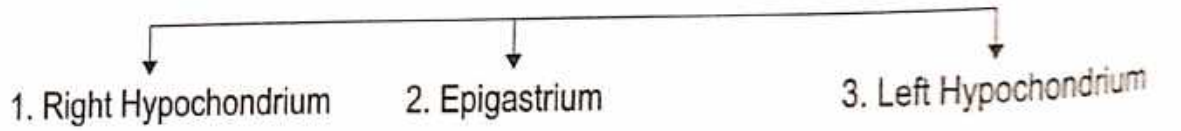
**Colour :** Reddish Brown

**Weight :** Male - 1600 gm Female - 1300 gm

**Consistency:** Soft


**System of organ :** Digestive system & Circulatory system

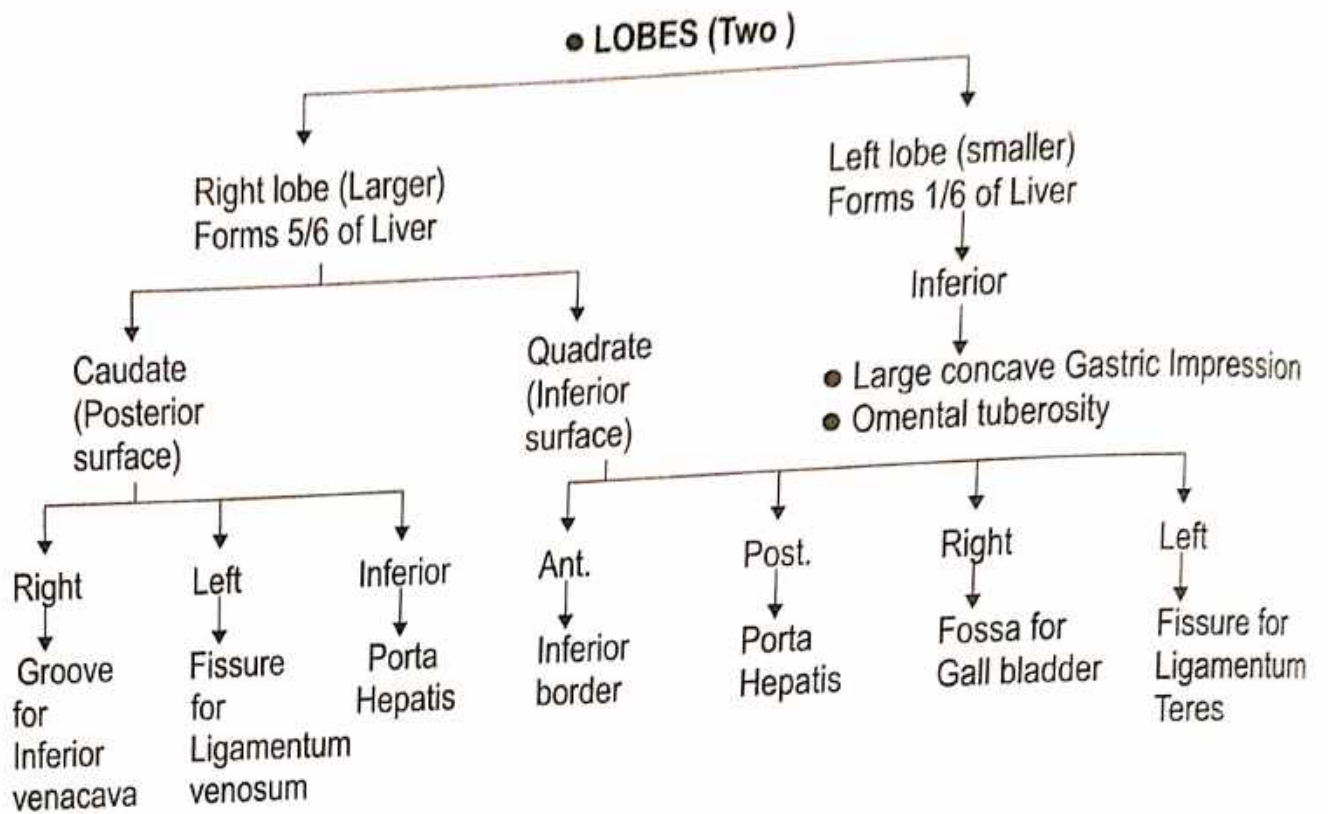
### ● Situation



**Features :**


### ● Attachment



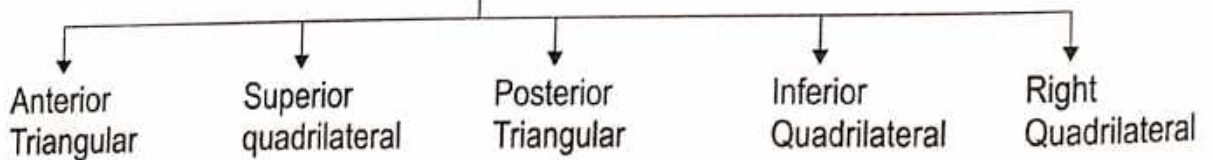


**● BORDER (ONE)**

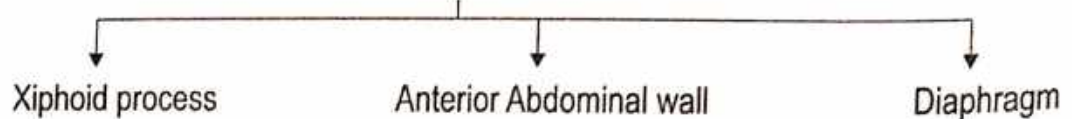
One Prominant Border, Inferior Border. In the Epigastrium extend from the Left 8<sup>th</sup> Costal Cartilage to 9<sup>th</sup> Costal Cartilage, Anterior part is Sharp marked.



**● SURFACES (FIVE)**



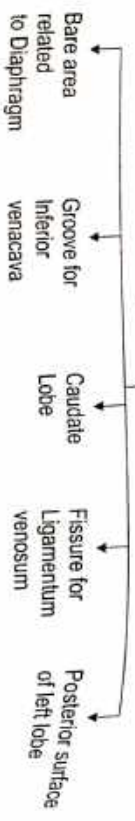
**1. Anterior Surface**



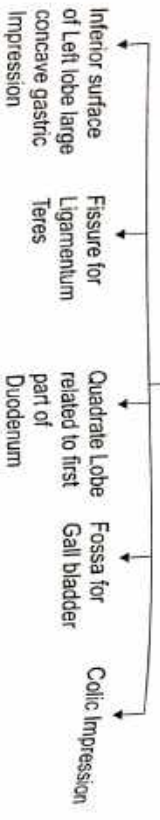
## 2. Superior Surface



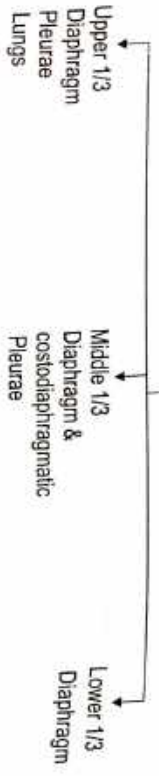
## 3. Posterior Surface



## 4. Inferior surface



## 5. Right surface



Post. Surface of right lobe

Groove for Inf. vena cava  
Triangular - limited  
Coronary ligament

Int. surface (Coronary Ligament) of right Lobe

Fossa for Gall-Bladder

Lesser Omentum

### Blood Supply

(i) Hepatic artery (20%)

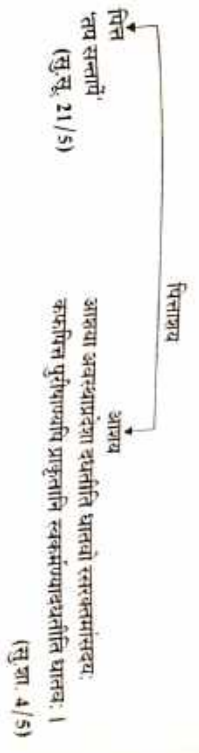
(ii) Portal vein (80%)

यसु यकृतः त्रीभिः पित्तं तस्मिन् रक्तकोशनिर्गति संज्ञा, स रसस्य रामकृतः । (सु.सू. 21/20)

## GALL BLADDER

Name :

- According to Ayurveda - पित्ताशय



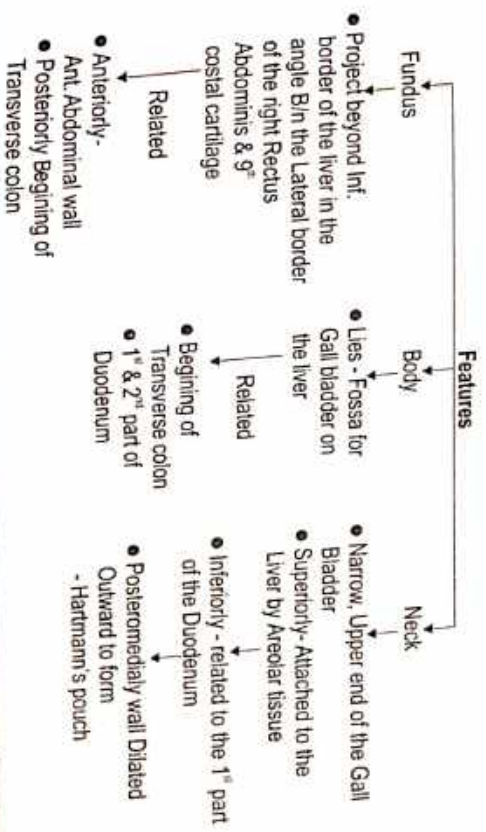
- Origin : Endodermal
- Shape : Pear Shaped
- Size :
  - 7 to 10 cm (3-4 inch) long.
  - 3 cm broad at its widest part.
  - 30-50 ml in capacity.

System of organ : Digestive system

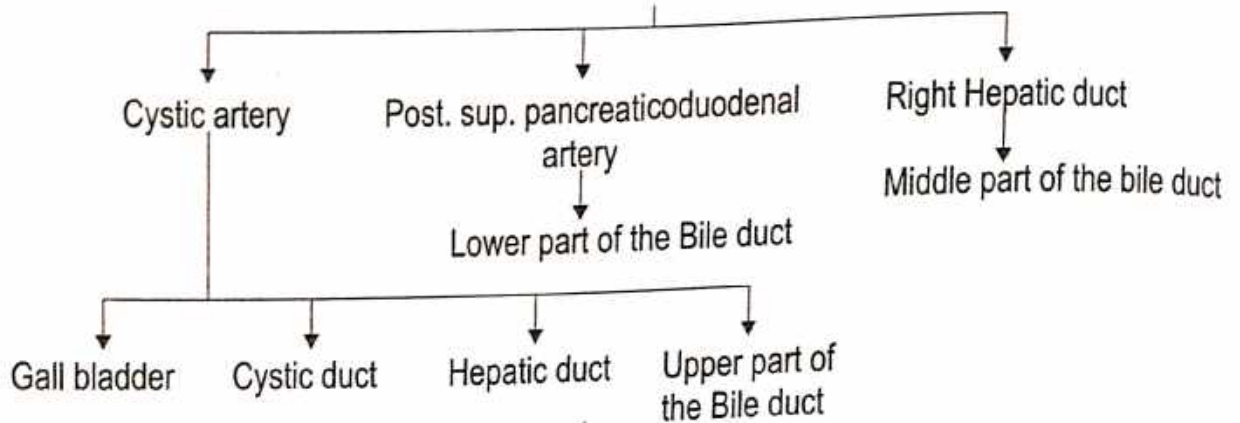
Situation : Fossa for Gall Bladder in Inferior surface of Liver.

कर्मोपकारतस्वयम्भारद्वयस्तद् वक्षिण पार्श्वस्य पित्तकलिते प्रसिद्धम् । (सु.सि. 9/10)

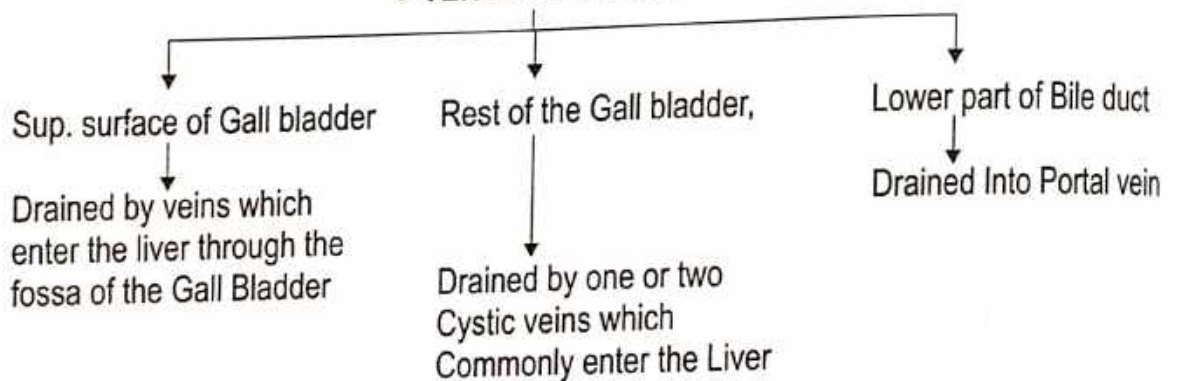
आश्रय : आश्रयासु - यानाश्रयः पित्ताश्रयः श्लेष्माश्रयो, रक्तश्रयः, आमाश्रयः, पक्वाश्रयो, मूत्राश्रयो, स्त्रीणां गर्भाशयोऽप्यम इति । (सु.शा. 5/7)



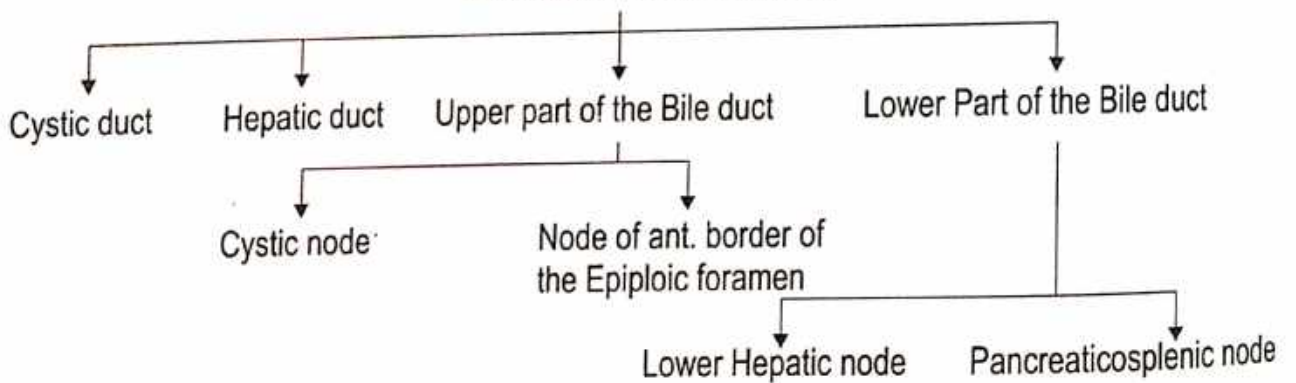
● **ARTERIAL SUPPLY**



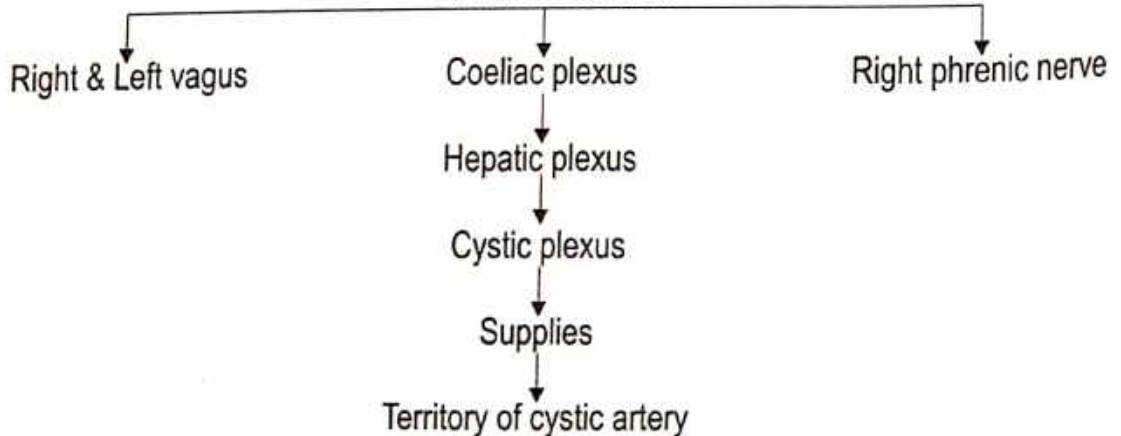
● **VENOUS DRAINAGE**



● **LYMPHATIC DRAINAGE**

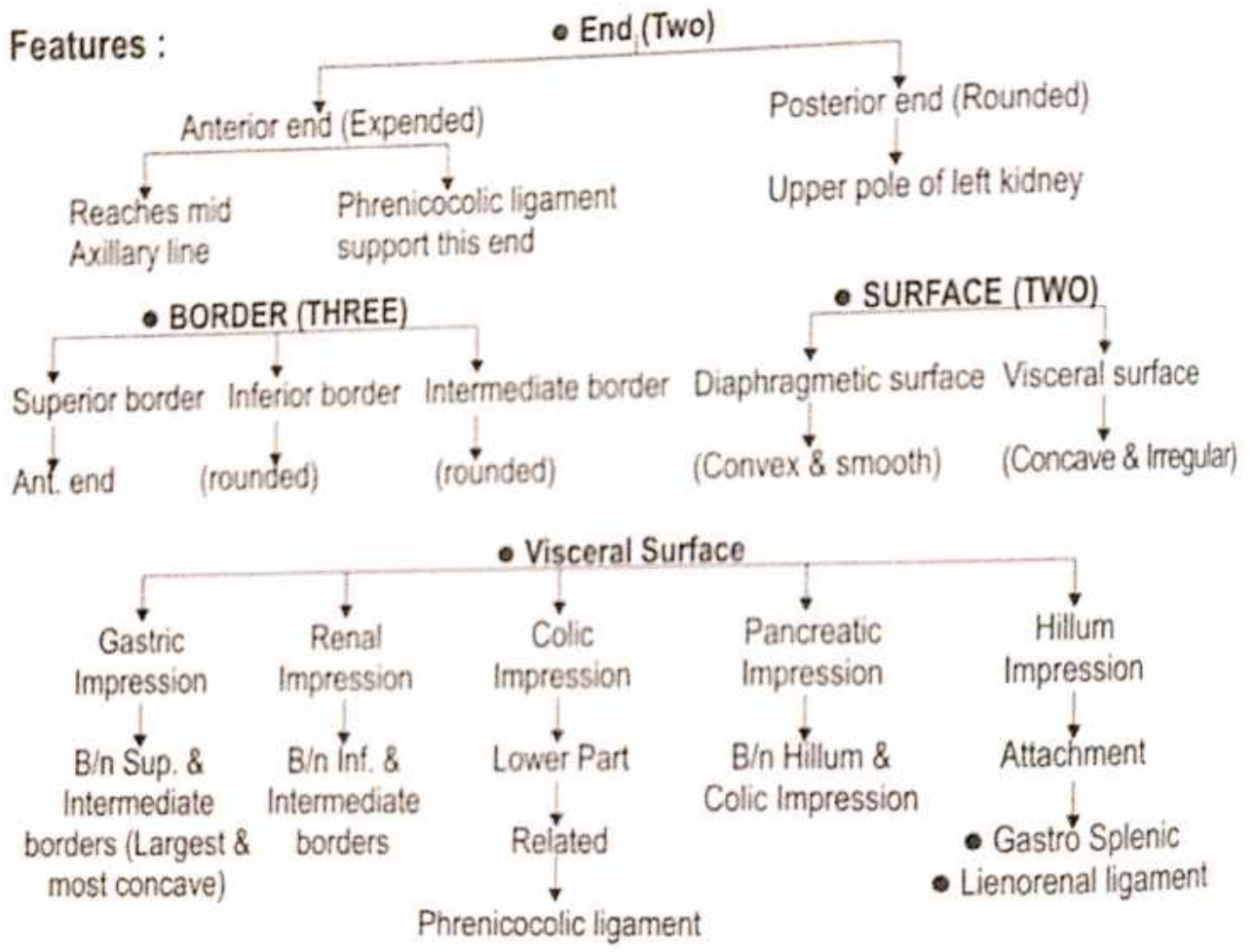


● **NERVE SUPPLY**



# SPLEEN

- Name :** ● According to Ayurveda - प्लीहा ● According to Modern - Spleen
- Origin :** ● According to Ayurveda - रक्त से ● According to Modern - Mesodermal
- Synonyms :** Lein (Latin), Spleen (Greak) रक्ताशय, Graveyard of RBCs
- Situation :** Left Hypochondrium & partly in Epigastrium [ जोगितस्य स्थानं यकृतप्लीहानी । (सु.सू. 21/16) ]  
 [ प्लीहा को आयुर्वेद में रक्त का स्थान माना गया है ]
- Size :** ● Length - 12.5 cm ● Width - 7.5 cm ● Thickness - 2.5 cm
- Shape :** Wedged / Tetrahedral ● Colour : Dark Purple (जामुन के समान श्याम वर्ण)
- Weight :** 180-300 gm ● Consistency : Soft ● System of organ : Circulatory system



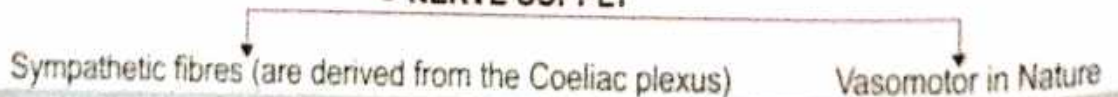
### ● ARTERIAL SUPPLY

Splenic artery (Largest branch of Coeliac Trunk)

### ● VENOUS DRAINAGE

- No Lymphatics
- Few lymphatics arise from the Connective tissue of the capsule and Trabeculae drain into the Pancreaticosplenic Lymph nodes Situated along the Splenic artery.

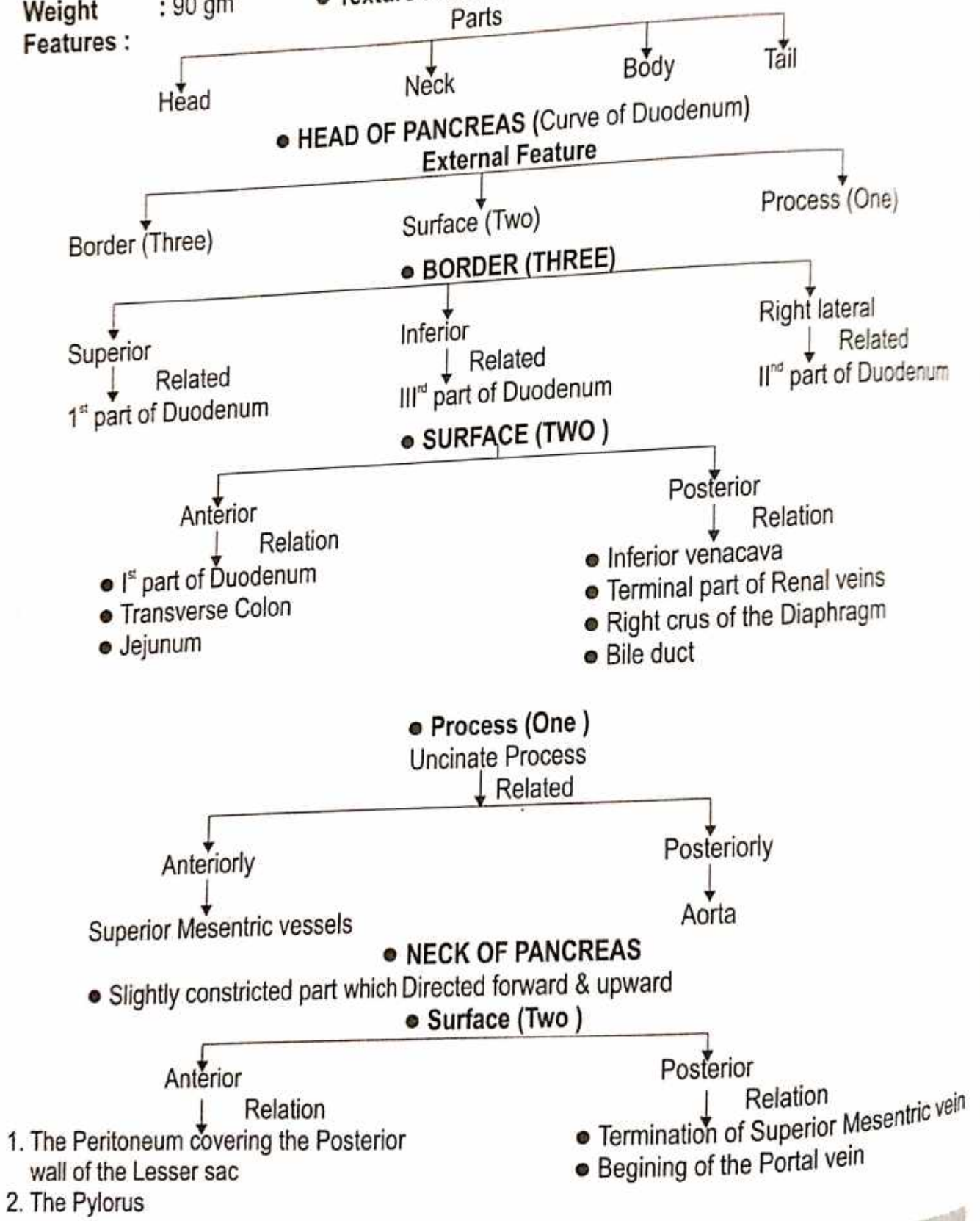
### ● NERVE SUPPLY





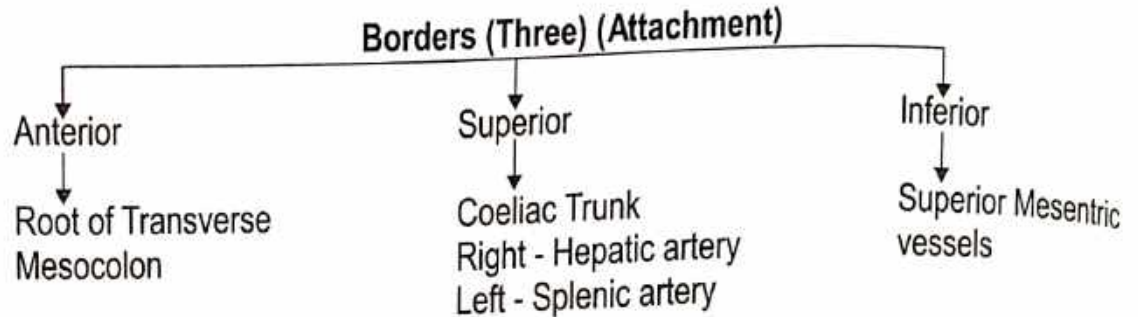
# PANCREAS

- Name** : ● According to Ayurveda - अग्न्याशय
- Origin** : Endodermal
- System of Organ** : ● Partly Exocrine system ● Partly Endocrine system
- Situation** : Lies transversely across the Posterior Abdominal wall at level of first 2 Lumbar vertebrae
- Size** : 15-20 cm long, 2.5 - 3.8 cm broad ● **Shape** : Elongated
- Weight** : 90 gm ● **Texture** : Soft lobulated
- Features** :

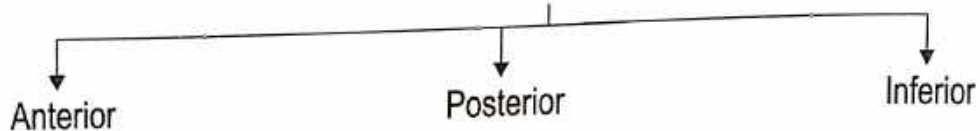


## ● BODY OF PANCREAS

- Elongated
- Extend from Neck to the Tail



## ● Surface (Three)



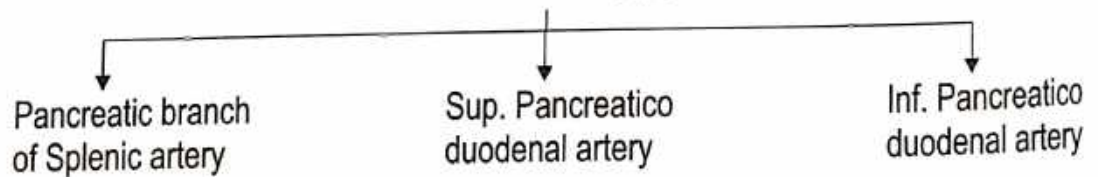
## ● TAIL OF PANCREAS

- Left End of the Pancreas.
- It Lies in the Lienorenal ligament together with the Splenic vessels. It comes into contact with the Lower part of the Gastric surface of Spleen.

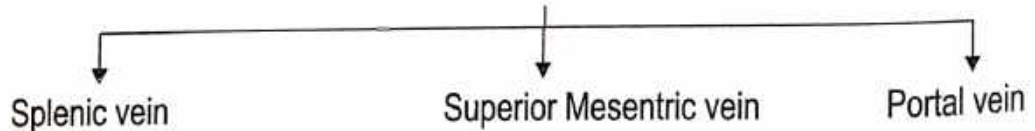
## ● DUCTS OF PANCREAS

- Main Pancreatic duct - Duct of wir - sung
- Accessory duct - Duct of santorini

## ● Arterial Supply




## ● Venous Drainage



## ● Lymphatic Drainage

Lymphatics follow the arteries and drain into Pancreaticosplenic, Coeliac & Sup. Mesenteric Groups of lymph nodes.

## ● Nerve Supply



### SMALL INTESTINE

**Name :** • According to Ayurveda - शृङ्गार  
 • According to Ayurveda - अक्षुन्नः स्त्रीषण्ण्यारि यः प्रसारः एतौ सतः ।  
 न पच्यमानं शितं तदनुचयाप्यनुधायति ।  
 कर्तव्यस्यान्वायाग आनन्तं गुदं वास्तस्य शक्तिः ॥ (सु.श्री. 4/16)

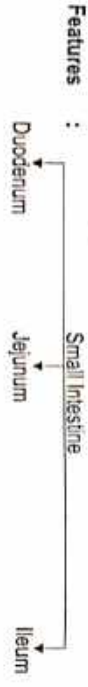
**Origin :** • According to Modern - Endodermal

**Extension :** Pylorus to iliocecal junction

**System of Organ :** Digestive system

**Situation :** • Abdominal Region • Pelvic Region

**Length :** 6 m [सर्वाङ्ग्यान्मन्त्रानि वृत्तां खाणामर्ष्यान्मन्त्रानि । (सु.श्री. 5/8)]



### DUODENUM

**Ayurvedic Name - शृङ्गो**  
 पश्चात्पश्चात्पश्चात्पश्चात् शृङ्गो सा प्रकीर्तिता ।

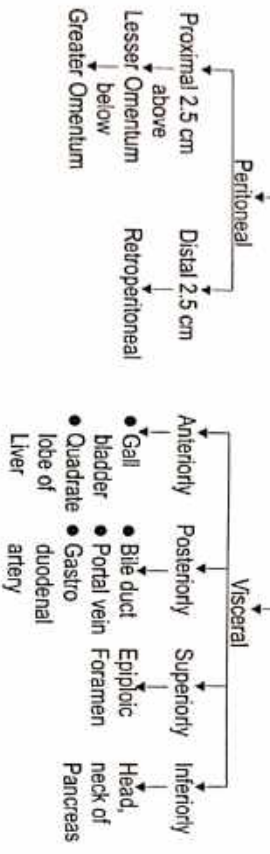
(सु.श्री. 40/169)

**Term - dudkadadactulos = Twelve fingers**  
 एतौ शितयथा वा चतुर्विधमन्त्रानामन्त्रान् प्रच्युतं पश्चात्पश्चात्पश्चात् शृङ्गो । (सु.श्री. 4/17)

**Situation -** • Above Umbilicus • Opposite L<sub>5</sub> and L<sub>1</sub> vertebra  
**Length - 25 cm** • Breadth - 2.5 cm • Peritoneal - Retroperitoneal organ



### (A) Superior Part




**(B) Descending Part**  
 Course - Superior Duodenal flexure - Inferior Duodenal flexure.

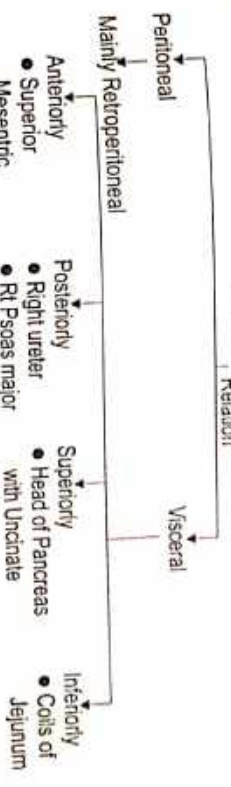
### • Special Feature



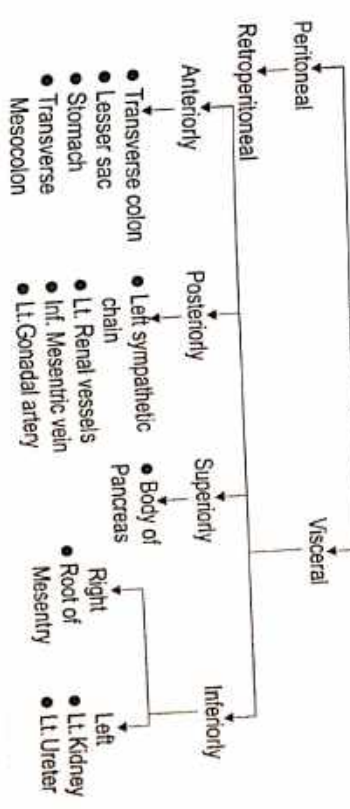
### • Relations



### (C) Horizontal Part

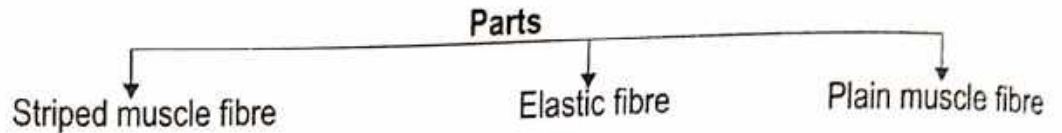


### (D) Ascending Part



● **Suspensory Muscle of Duodenum OR Ligament of Treitz**

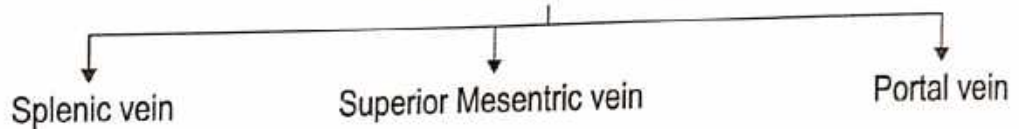
**Function :** Supports & suspend Duodenojejunal flexure.  
**Origin :** Left Crus of Diaphragm  
**Attachment :** Duodenojejunal flexure



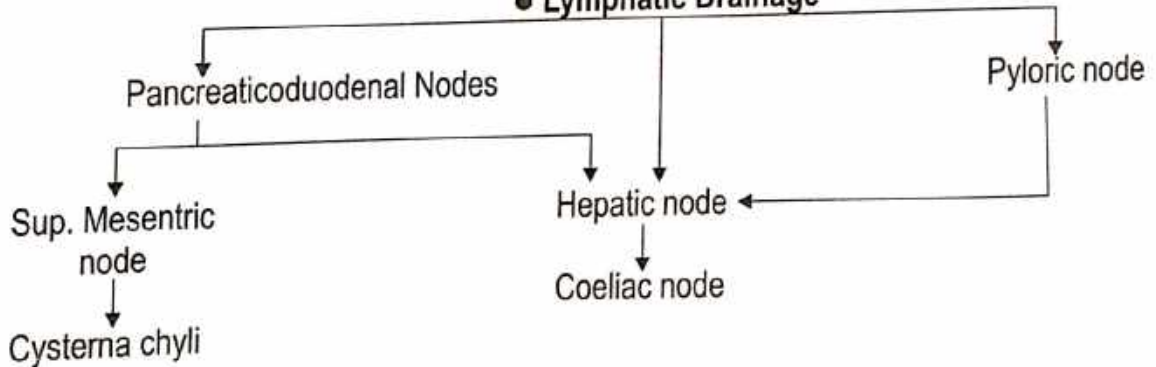
● **Arterial Supply**

- Superior Pancreatico duodenal artery.
- Inf. Pancreatico duodenal artery.
- Right Gastric artery.
- Retroduodenal artery.
- Right Gastroepiploic artery.


● **Venous Drainage**



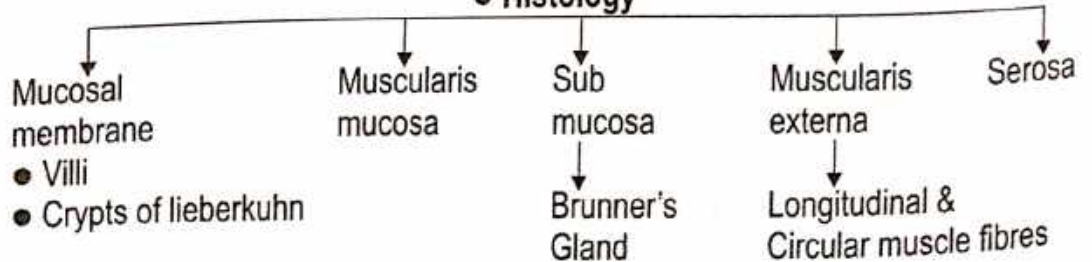
● **Lymphatic Drainage**



● **Nerve Supply**



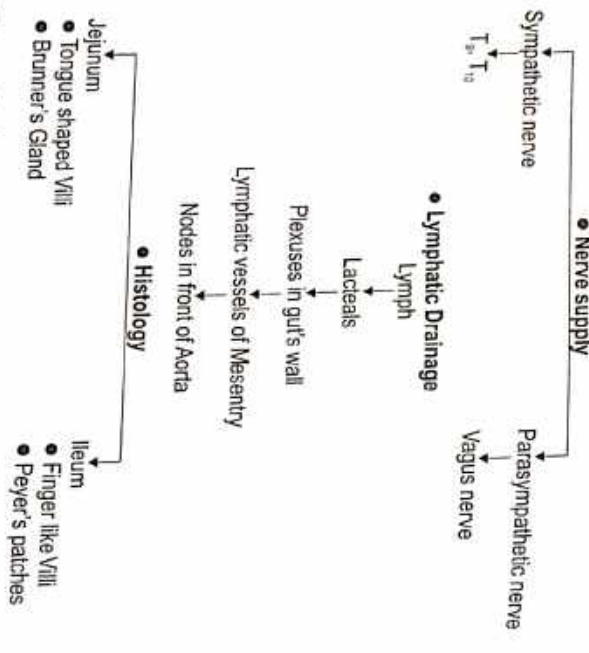
● **Histology**



**• JEJUNUM & ILEUM**

Name : According to Ayurveda - शंखरा दश शृंगरा

- Location**
  - Jejunum
    - Upper & Left part
  - Ileum
    - Lower & Right part
- Extension** : Duodenojejunal flexure to ileocecal junction.
- Arterial supply** : Jejunal ilial branches of Superior Mesenteric artery.
- Venous drainage** : Sup. Mesenteric vein.



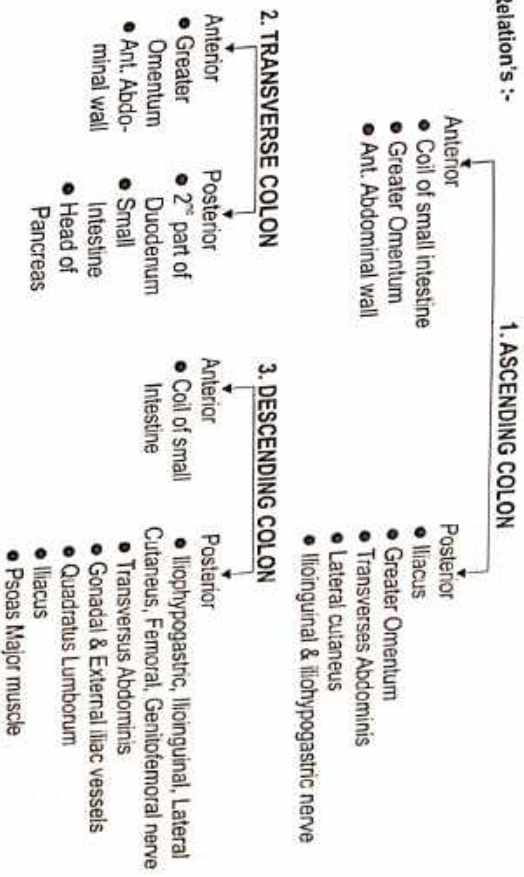
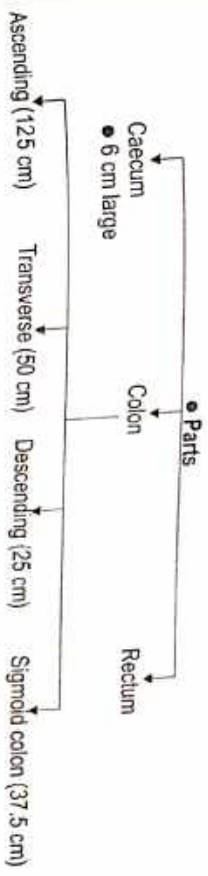
- Root of Mesentery** - Duodenojejunal Flexure - Junction of Right Lateral & Transubercular planes.
- Meckel's Diverticulum (diverticulum Ile)**
  - Persistent Vitellointestinal duct in Embryo.
  - Length - 2 inches / 5 cm.
- Situation** : • 60 cm proximal to ileocecal valve

**LARGE INTESTINE**

Name : According to Ayurveda - शंखरा दश शृंगरा

- Origin** : Endodermal & Ectodermal.
- Extension** : Ileocecal junction to the Anus.
- Length** : 1.5 M
- System of Organ** : Digestive system

• प्रतिपाद्यता स्वतन्त्रा पराश्रयो मत् स्वरु भूदं च ।  
 • प्रतिपादने षे तयोर्भूत पराश्रयो भूदं च ।  
 (च.वि. 5/6)  
 (सु.श. 9/20)



- BLOOD SUPPLY**
  - Sup. Mesenteric artery
    - Appendix
    - Caecum
    - 2/3 of Transverse colon
    - Ascending Colon
  - Inf. Mesenteric artery
    - Left 1/3 of Transverse Colon
    - Descending Colon
    - Rectum
    - Upper part of Anal canal

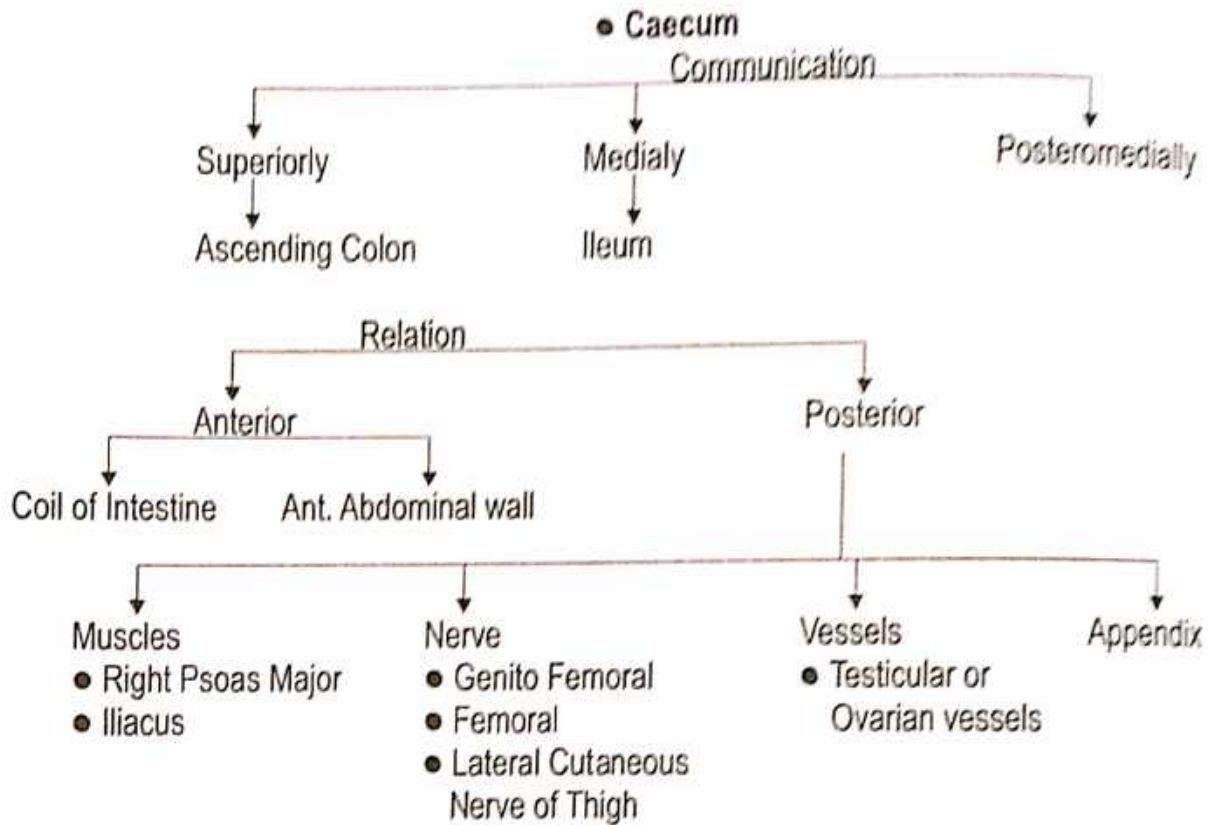
## Caecum

**Origin :** ● शोणितकिट्टप्रभव उपदुक्तः ।

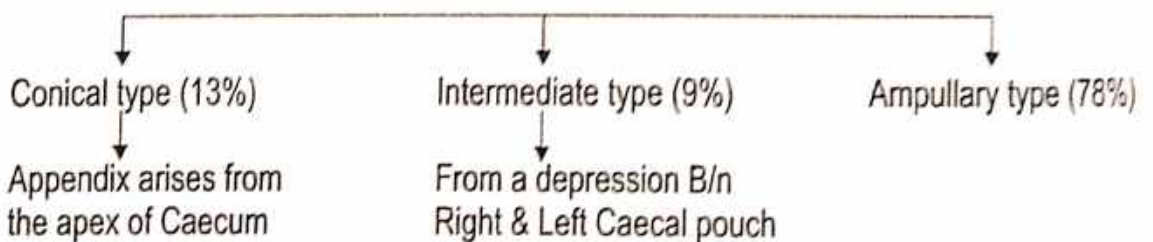
(सु. शा. 4/24)

● यकृतसमन्तात् कोष्ठं च तथा न्याणि समाश्रिता ।  
उपदुक्तस्थं विभजते मलं मलधरा कला ।

(सु. शा. 4/16)



### ● Types



### ● Blood Supply



### ● Nerve Supply

T<sub>11</sub> to L<sub>1</sub> Parasympathetic & Vagus

● Clinical Anatomy of Caecum -

1. Amoebiasis - Causing amoebic dysentery.
2. Intestinal Tuberculosis.
3. Carcinoma - Inflammation of Caecum is known as caecitis or Typhlitis

## APPENDIX

Length : Varies from 2-20 cm.

Average : 9 cm

Diameter : 5 mm

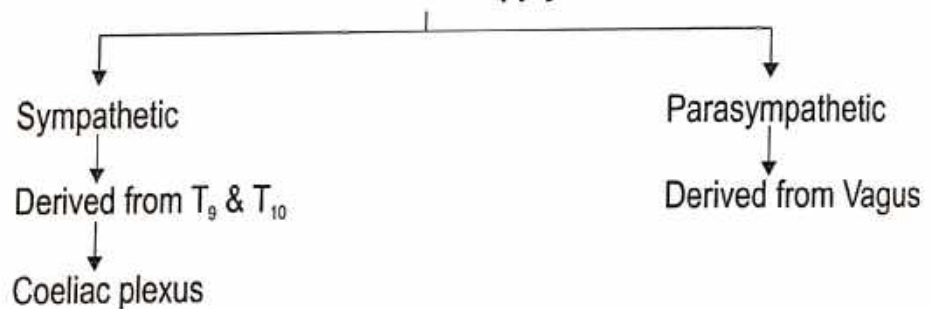
Type / Position :

1. Paracolic - 11 o'clock
2. Retrocaecal - 12 o'clock - \*Commonest 65%
3. Splenic - 2 o'clock
  - Pre-Ileal
  - Post-Ileal
4. Promontory - 3 o'clock
5. Pelvic - 4 o'clock
6. Subcaecal - 6 o'clock

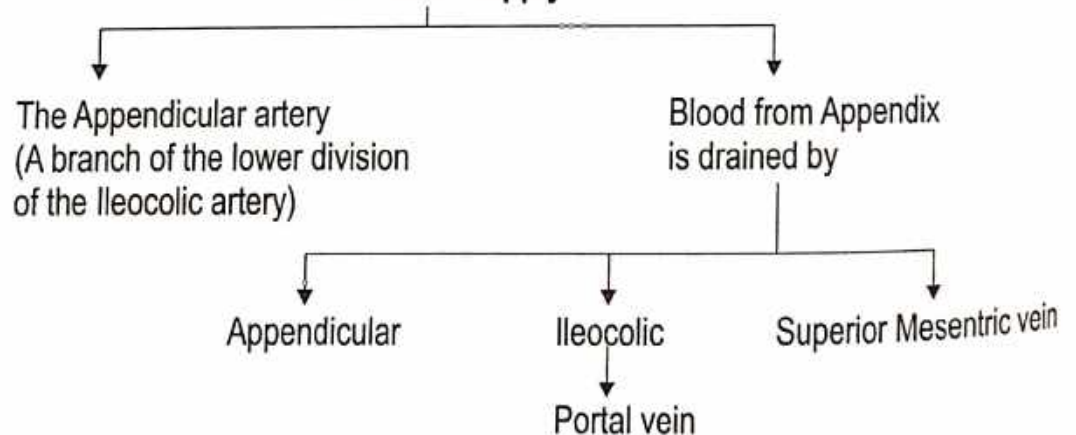
### Peritoneal Relation

The appendix is suspended by a small, triangular fold of Peritoneum called the Mesoappendix or appendicular mesentery.


#### • Nerve Supply



#### • Blood Supply



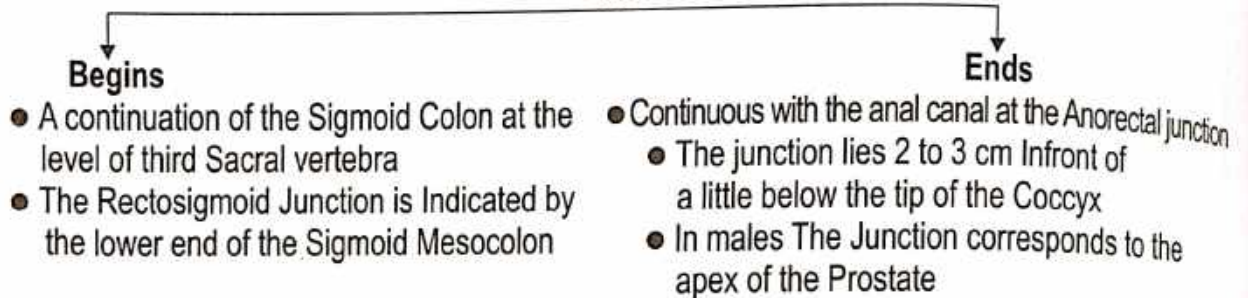
#### • Lymphatic Drainage



# RECTUM

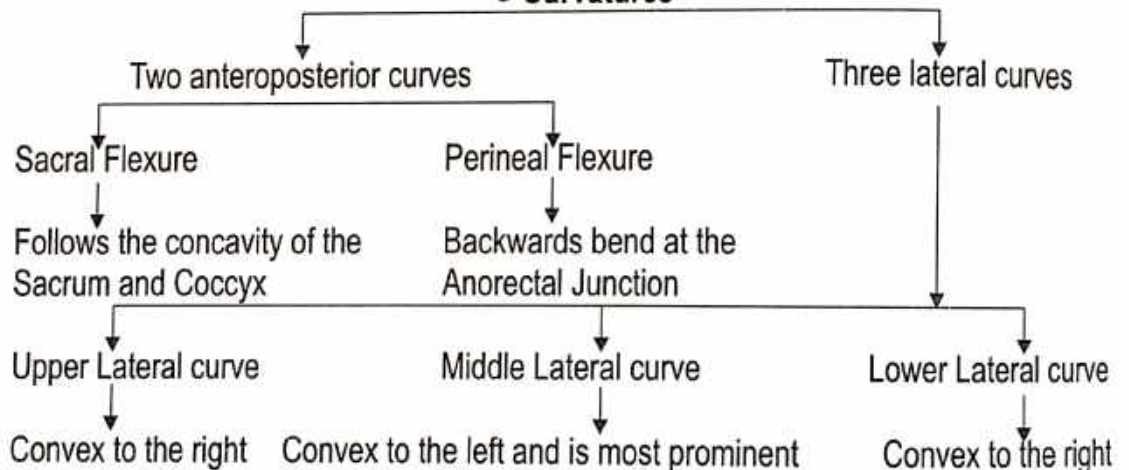
- Name :** ● According to Ayurveda - उत्तर गुद
- Introduction :** ● The Rectum is the distal part of the large gut.  
● It is placed between the Sigmoid colon above and the Anal canal below.
- Situation :** ● The posterior part of the lesser pelvis.  
● In front of the lower three pieces of the Sacrum and the Coccyx.
- Length :** 12 cm

## ● Rectum

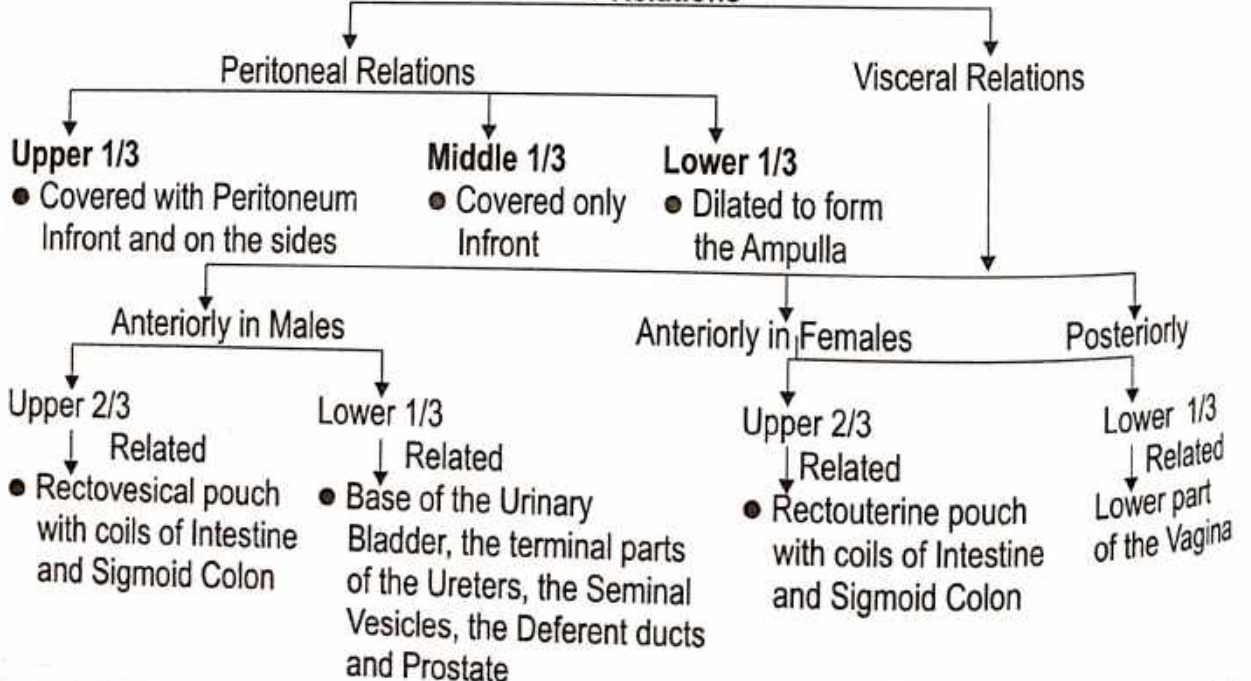


**Direction :** Runs first downwards and backwards, then downwards, and finally downwards and forwards.

## ● Curvatures



## ● Relations





## ANAL CANAL

Name :

- According to Ayurveda - तृणार
  - चण्डरुद्र फर्णिस
  - शतवर्षावर्षानं रूपावर्षानिनरं नृं नाग नृं
- (च.श. 1/26)  
(सू.श. 6/26)

Introduction :

- Terminal part of the Large Intestine
- Anal triangle between the Right and Left Ischio-rectal fossa.
- Length = 3.8 cm
- Extent = Anorectal Junction to the Anus.
- Direction = Downwards, Backwards
- Endodermal

Situation :

- Anal Canal
- Anteriorly
- Posteriorly
- Laterally

Origin :

- Perineal body
- Anococcygeal Ligament
- Tip of the coccyx
- Ischio-rectal fossa

Relation :

- Male Membranous urethra
- Bulb of Penis
- Female End of vagina

### INTERIOR PART

- Upper mucous part
- Middle part
- Lower cutaneous part

### UPPER MUCOUS PART (• 15 mm • By mucous membrane)

- Vertical Columns
- Anal valves
- Short Transverse fold
- Epithelial Projections (Anal papillae)
- Middle part
- Anal Sinus
- Depression in the mucosa
- Lower cutaneous part
- Pectinate line
- Anal valves together form Transverse line all Around the Anal canal.

### MIDDLE PART

- Anal columns absent
- Mucosa is the less mobile than upper part
- Pecten or transitional zone.
- Whitish appearance - white line of Hilton
- Situation : • Subcutaneous part of Ext. Anal Sphincter.
- Lower border of Internal anal Sphincter.

### LOWER CUTANEOUS PART

- 8 mm
- True Skin
- Contents : Sweat & Sebaceous Glands

• Posteriorly  
(The relations are the same in the Male and Female)

- Lower three pieces of the Sacrum, the Coccyx and the Anococcygeal ligament
- Piriformis, Coccygeus and Levator ani.

- The Median Sacral, the Superior Rectal and the lower Lateral Sacral vessels
- The sympathetic chain with the Ganglion Impar of S<sub>1</sub>, S<sub>2</sub>, S<sub>3</sub>, Coccygeal 1 and the Pelvic Splanchnic nerves, Lymph nodes, Lymphatics and Fat

### Muscular Folds

Two types of folds

- Longitudinal folds
- Transitory

- Transverse folds OR Horizontal folds OR Houston's valves OR plicae Transversales
- Permanent

- First small transverse fold
- Second transverse fold
- Third transverse fold
- Four transverse fold

### Parts of Rectum

Two developmental parts

- Upper part
  - Related to the Peritoneum develops from the Hind gut and lies above the third transverse fold of the Rectum
  - Arterial Supply
    - Superior Rectal artery
    - Middle Rectal artery
    - Median Rectal artery
  - Lymphatic Drainage
    - Superior Rectal vein
    - Middle Rectal vein
    - Median Rectal vein
- Lower part
  - Devoid of Peritoneum develops from the cloaca and lies below the third transverse fold
  - Venous Drainage
    - Middle Rectal vein
    - Median Rectal vein
  - Nerve Supply
    - Sympathetic (L<sub>1</sub>, L<sub>2</sub>)
    - Parasympathetic (S<sub>2</sub>, S<sub>3</sub>, S<sub>4</sub>)

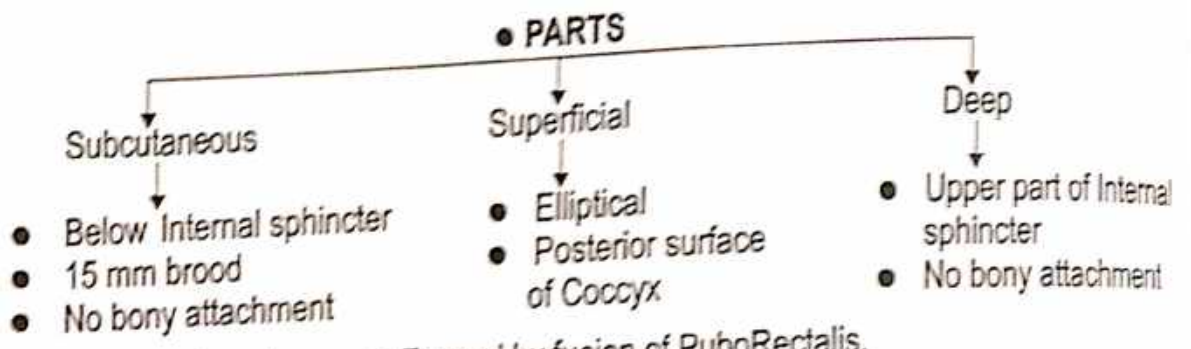
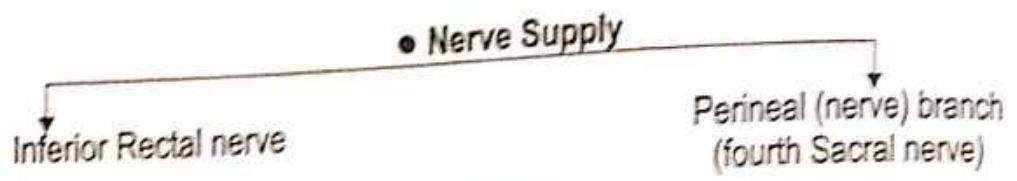
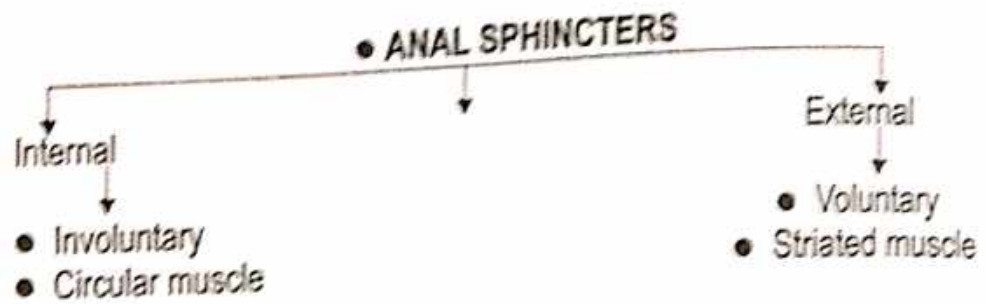
- Upper half
  - Pass along the Superior Rectal vessels to the Inferior Mesenteric nodes after passing through the Pararectal and Sigmoid nodes
- Lower half
  - Along the middle Rectal vessels to the Internal Iliac nodes

### Supports of Rectum

- Pelvic floor formed by levator ani muscle
- Fascia of Waldeyer
- Lateral ligaments of the Rectum
- Rectovesical fascia of denovillers
- Pelvic Peritoneum
- Pineal body with its muscles

Function :

The Sigmoid colon is the faecal Reservoir and whole of the Rectum is empty in normal individuals, being Sensitive to distussion, passage of faeces into rectum, therefore, causes the desire to Defaecate.

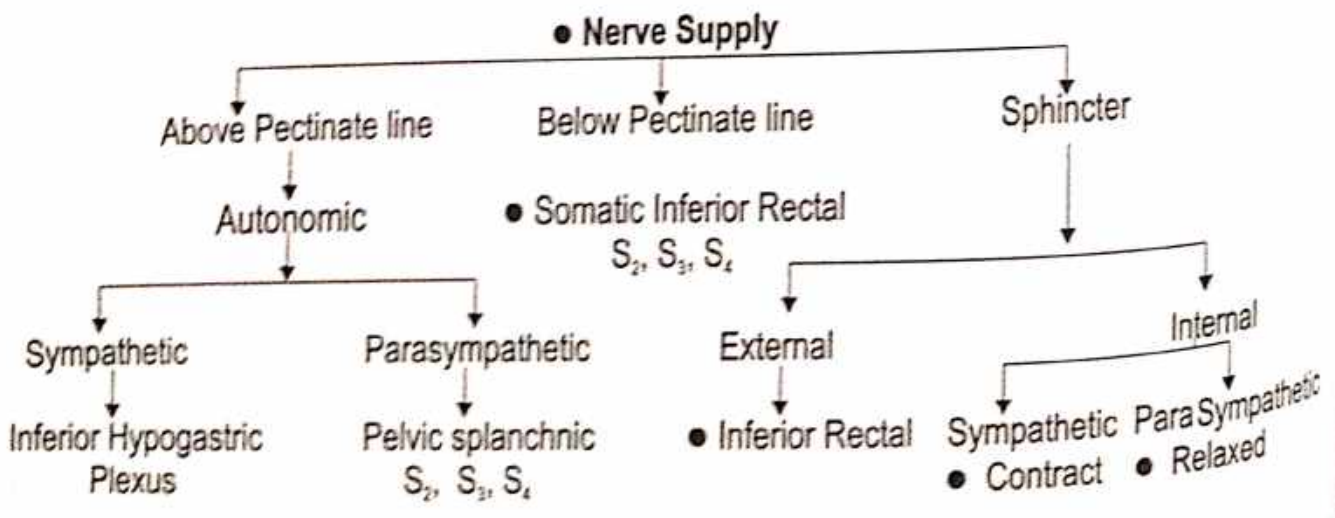
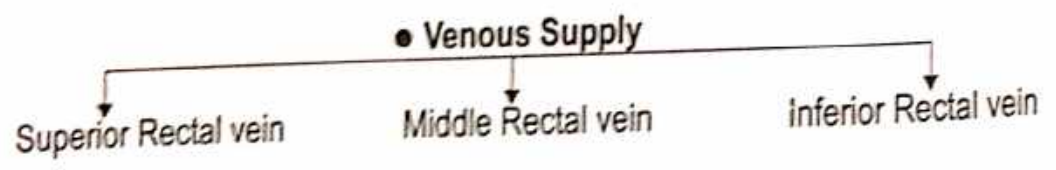
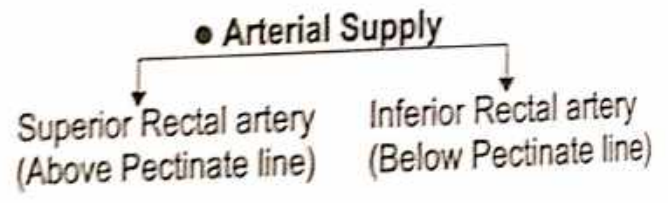
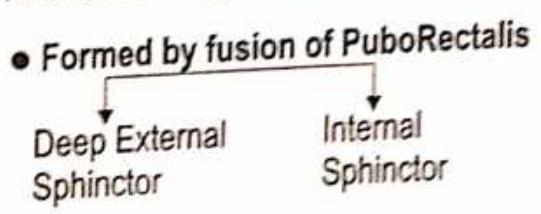


**Conjoint Longitudinal coat -**

- Formed by fusion of PuboRectalis.
- Longitudinal muscle coat of Rectum at Anorectal junction
- Anal Intermuscular septum Attachment - white line

**Anorectal Ring :**

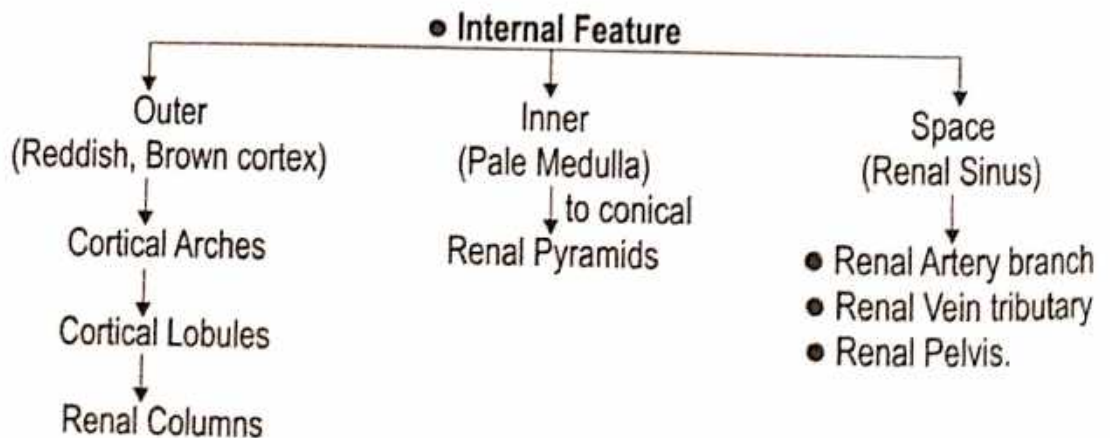
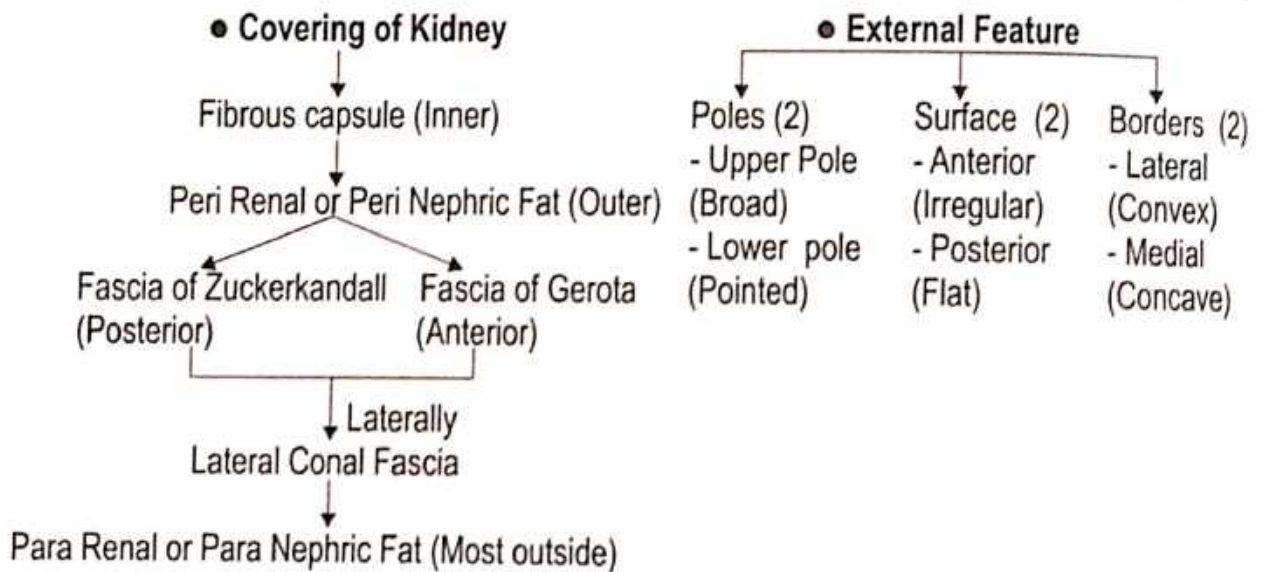
- Muscular ring
- Anorectal junction



# EXCRETORY SYSTEM

## KIDNEY

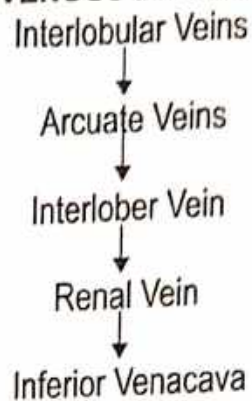
- Name** ● According to Ayurveda - वृक्क  
 उत्पत्ति - रक्तमेदप्रसादाद्वृक्कौ । (सु.शा. 4/30)  
 स्रोतस् - ● मेदोवहानां स्रोतसां वृक्कौ मूलं वपावहनं च । (च.वि. 5/7)  
 ● मेदोवहे द्वे, तयोर्मूलं कटी वृक्कौ च । (सु.शा. 9/22)  
 ● मेदोवाहिनां वृक्कौ मांसं च । (अ.सं.शा. 6/44)
- Origin :** ● According to Ayurveda - रक्त और मेद ● According to Modern - Mesodermal
- Number :** Two ● **Weight :** 150 gm in Males, 135 gm in Females ● **Shape :** Bean Shaped
- Location :** ● Upper border of T<sub>12</sub> vertebrae ● Centre of L<sub>3</sub> vertebrae.
- Situation :** Long axis → Downwards & laterally [ वृक्कौमांस पिण्डद्वयम् एकोवामपार्श्वस्थितः  
 Transverse axis → Laterally & Backwards. [ द्वितीयो दक्षिणपार्श्व स्थितः (डल्हण, सु.नि. 9/18) ]



**Size of Kidney :** ● 11 cm Long ● 6 cm Broad ● 3 cm Thick

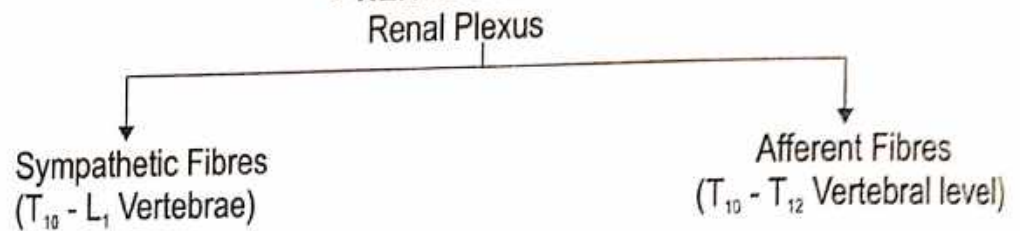
**Orientation :** Long laterally

● **VENOUS DRAINAGE**

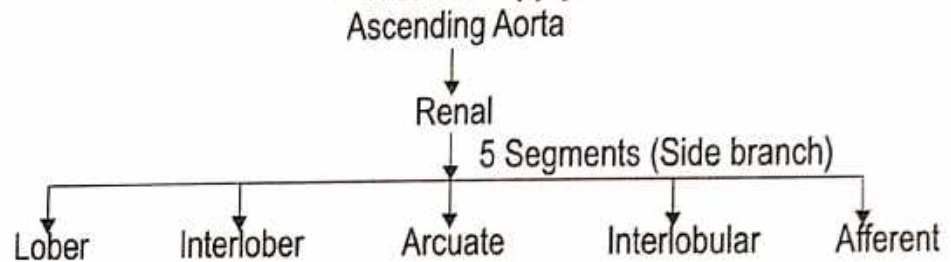


● **LYMPHATIC DRAINAGE**  
Lateral Aortic Nodes at L<sub>2</sub> Level

● **NERVE SUPPLY**



● **Arterial Supply**



**Exposure of kidney from outer to inner :**

1. Skin
2. Superficial Fascia
3. Posterior layer of Thoracolumber Fascia, Lattissimus dorsi & Serratus Anterior
4. Erector spinae
5. Middle layer of Thoracolumber Fascia
6. Quadratus Lumborum
7. Anterior layer of Thoracolumber Fascia in which the related nerves are embedded.

# REPRODUCTIVE SYSTEM

## MALE REPRODUCTIVE ORGAN

Male Reproductive Organ include :

- Testis
- Epididymis
- Deferent Duct
- Seminal Vesicles
- Ejaculatory Duct
- Spermatic Cord
- **TESTIS (वृषण)**
- Scrotum
- Penis
- Prostate

Name of organ - ● According to Ayurveda- वृषण

● According to Modern - Testis

● द्वी वृषणौ।

(च.शा. 7/11)

● शुक्रवहानां स्रोतसां वृषणौमूलं शेफश्च।

(च.वि. 5/4)

● शुक्रवहे द्वे, शुक्रप्रादुर्भावाय ।

(सु.शा. 9/6)

● शुक्रवहे द्वे तयोर्मूलं स्तनौ, वृषणौ च।

(सु.शा. 9/21)

● वीर्यवाहि शिराधारी वृषणौ पौरुषावही ।

(शा.पू. 5/48)

Position : Oblique

Shape : ● According to Ayurveda- दीर्घवृत्ताकार ● According to Modern - Oval

Origin : ● According to Ayurveda- " मांसासृक्कफमेदः प्रसादाद् वृषणौ।" (सु.शा. 4/30)

मांस, रक्त, कफ तथा मेद इनके सार से वृषण की उत्पत्ति होती है।

● According to Modern - Endoderm

Weight : 10-15 gm

Measurement : ● Long - 3.75 cm ● Width - 2.5 cm ● Thick - 1.8 cm

Number : One pair ● System of organ : Male Reproductive organ

External Features -

Pole (Two)

Upper Pole

(Convex & Smooth)

Lower Pole

(Convex & Smooth)

\* The Upper pole provides attachment to the Spermatic cord.

BORDERS (Two)

Anterior Border

- Convex & Smooth)
- It is fully covered by Tunica Vaginalis

Posterior Border

- Straight
- Partially covered by Tunica Vaginalis

SURFACE (Two)

Medial

(Convex & Smooth)

Lateral

(Convex & Smooth)

Covering of Testis -

- Outer most - Tunica Vaginalis
- Middle - Tunica Albuginea
- Inner - Tunica Vasculosa

Internal Features -

- Contain 200-300 lobules, each lobule have 2-3 Seminiferus Tubules.

Nerve supply - Sympathetic nerve arising from segment T<sub>10</sub> of Spinal cord.

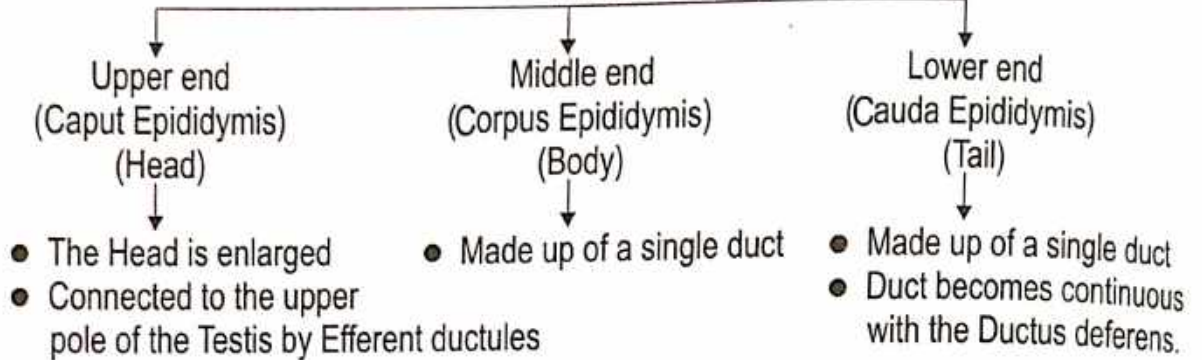
## ● EPIDIDYMIS (अधिवृषण)

- Act as Reservoir of Spermatozoa.

**Dimension -** Length - 20 cm

**Position -** It is a narrow tightly coiled tube connecting the Efferent Duct from the near of each testicles to its vasa Deferens.

### PARTS



**Function -** Peristaltic and segmenting contraction to push Spermatozoa away from Testis.

## ● DUCTUS DEFERENS

शुक्रवहे द्वै शुक्रप्रादुर्भावाय, द्वै विसर्गाय (सु.शा. 9/6)

**Synonyms -** ● Vas Deferens ● Deferent Duct

**Definition -** ● The Ductus deferens is a thick walled, Muscular tube which transmits Spermatozoa from the Epididymis to the Ejaculatory duct.

● It feels cord-like at the upper lateral part of Scrotum.

● Ductus dererens has a narrow lumen except at the terminal dilated part called the Ampulla.

**Length -** About 45 cm long when straightened.

**Location -** ● With in the Scrotum along the posterior border of the Testis.

● In the Inguinal canal as part of the Spermatic cord.

● In the Greater Pelvis.

● In the Lesser Pelvis.

### Course and Relations -

● The Ductus deferens begins as a continuation of the tail of the Epididymis.

● Along the posterior border of the Testis.

● In the Spermatic cord.

● **In the Greater pelvis -** At the deep inguinal ring it leaves the Spermatic cord and hooks round the lateral side of the Inferior Epigastic Artery, It then passes backwards and medially, across the External Iliac Vessels, and enters the Lesser Pelvis.

● **In the Lesser pelvis -** The Ductus deferens runs downwards and backward on the lateral pelvic wall, deep to the Peritoneum.

● At the base of Prostate, the Ductus deferens is joined at an acute angle by the duct of the Seminal vesicle to form the Ejaculatory duct.

● The part of the ductus lying behind the base of the Bladder and tortuous, and is known as the Ampulla.

**Arterial Supply -** The artery to the Ductus deferens arises from one of the terminal branches of the Superior Vesical Artery.

**Venous Drainage -** Vesical venous plexus which opens into the Internal iliac vein.

**Development :** Mesonephric duct

• SEMINAL VESICLES (शुक्राणु)

द्वयद्वारे वक्षिणे पार्श्वे वस्तिद्वारस्य चाप्यधः ।

(सु. भा. 4/21)

- Position : Bin base of Urinary Bladder & Rectum.
- Dimension : 5 cm in length
- Structure : External or Areolar Coat • Middle or Muscular Coat • Internal or Mucous Coat
- Blood vessels : Inferior Vesical • Middle Rectal Arteries
- Nerves Supply : Originate from Pelvic plexus.

• EJACULATORY DUCT (शुक्राणुस्रावक वाहिनी)

Originate from joining of Terminal part of Deferent duct and duct of Seminal vesicle.

- Dimensions : Length = 2 cm.
- Structure : Outer = Fibrous layer • Middle = Muscular layer
- Internal = Mucous layer with columnar epithelium.

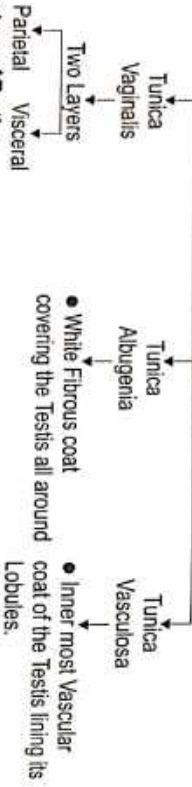
• SPERMATIC CORD (वृणु वस्त्र)

- Deferent duct along with Nerves and vessel passes through deep inguinal ring to form Spermatic cord.
- Position - Bin the Urinary Bladder & Rectum
- Length - 5 cm.

Development of Testis -



COVERING




Structure of Testis :

- Outer - External Spermatic Fascia
- Middle - Cremasteric Fascia
- Internal - Internal Spermatic Fascia
- Each Testis 200 - 300 lobules
- Each lobules 2 or 3 Seminiferous Tubules
- Length of Seminiferous Tubules - 60 cm.
- Thickness - 0.20 mm

Arterial Supply : Testicular artery

- Branch
- Abdominal aorta
- Position
- L<sub>2</sub> Vertebrae

Venous Drainage :



Lymphatic Drainage

- Pre-aortic lymph nodes
- Para aortic lymph nodes
- Position : L<sub>2</sub> Vertebrae
- Nerve Supply : T<sub>10</sub> sympathetic nerves.


• SCROTUM (वृणुकोय)

फलकोयः स्रावकोयनिनि

(हस्त्या सु. सू. 23/5)


- The Scrotum is a Cutaneous bag containing the Right and Left Testis, the Epididymis and lower parts of the Spermatic cords.

• Consists of five layers



- Blood Supply - Superficial External Pudendal Artery, Deep External Pudendal Artery, Scrotal branches of Internal Pudendal Artery, Cremasteric branches of Inferior Epigastric Artery.

• Nerve Supply



The Areas supplied by segments L<sub>1</sub> and S<sub>2</sub> are separated by the ventral axial lines

• PENIS (फिन्)

Name of Organ -

- According to Ayurveda- (फिन्)
- एक शेषः ।
- शुक्रवहानां स्रोतसं वृणुनां मूलां शेषश्च ।
- प्रजापतिस्यस्यस्येति ।
- नर्मायानकं लिङ्गमयनं वीर्यवृणुयोः ।

Number : One • Origin : Mesodermal

Features :

- ROOT OF PENIS - Composed of 3 masses of Erectile tissue
- Two Crura & - One Bulb.
- Covered by - Bulbospongiosus.

● **BODY OF PENIS -**

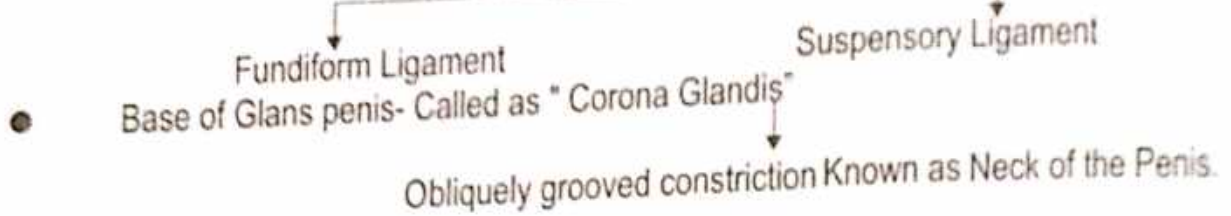
- Made up of 3 elongated masses of erectile tissue-
- Right & left Corpora Cavernosa
- Median Corpus Spongiosum.

● **TWO SURFACE**

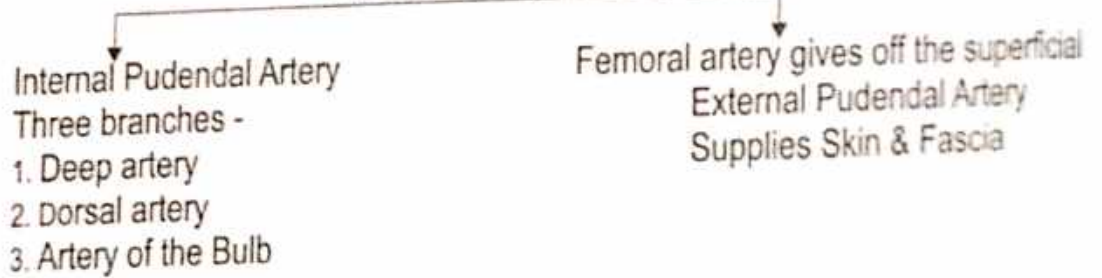


- Two Corpora Cavernosa are the forward continuation of the Crura.
- Corpus Spongiosum is the forward continuation of the Bulb of the Penis.


**Supports of Body of Penis**



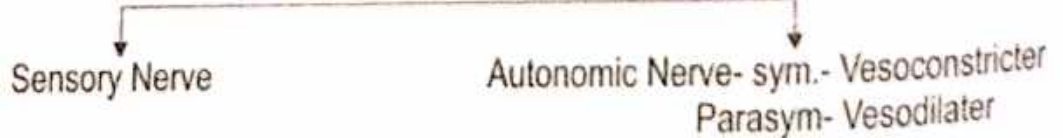
● **ARTERIES OF PENIS**



● **VENOUS DRAINAGE**



● **NERVE SUPPLY**



● **LYMPHATIC DRAINAGE**

Lymphatics from Glans Penis drain to deep Inguinal nodes



## PROSTATE GLAND (पौरुष ग्रंथि)

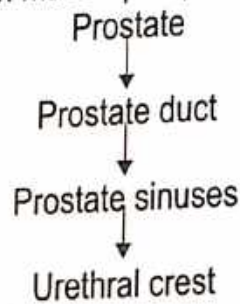
- Introduction** -
- Partly Glandular
  - Partly Muscular
  - Dark Brown Red in colour
  - Lies within the Pelvis
  - Behind the Pubis symphysis
  - Enclosed by a Dense Fascial sheath
- Dimensions :**
- Greater Transverse - Diameter = 1.5 inches
  - Outer posterior - Diameter = 3/4 inches
  - Vertical - Diameter = 1.8 inch.
  - Length = 3 cm
  - Width = 4 cm
  - Thick = 2 cm
  - Weight = 8 gm

### ● SITUATION

- ↓ Lies in the Lesser Pelvis
  - ↓ Below the Neck
  - ↓ Pubic Symphysis
  - ↓ Pubic Arch
- Associations :**
- Upper part by Ejaculatory duct.
  - Base attached to Inferior aspect of the Bladder.
  - Lateral surface rest against Fascia covering the Levator ani muscles.
  - Post. surface near the Rectum.

### Structure :

- Fascial sheath made up of plain Muscle fibres and fibrous tissue



**Precursor :** Endodermic evagination of Urethra.

**Prostate fluid :** ● Slightly acid PH = 6.4, Rich calcium & Citrate.

### ● Surface

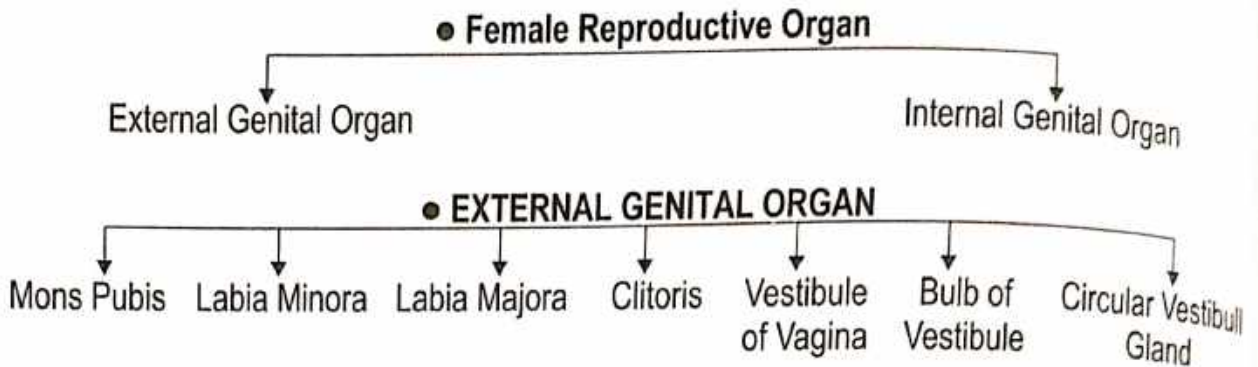
- ↓ Base/ Sup. Surface  
Continuous with Neck
- ↓ Apex/Post. surface  
● Rest on upper Surface of sup. layer of the Urogenital diaphragm  
● Rest on Ant. wall of Rectum & can be felt by a finger in Rectum.
- ↓ Inferior Lateral surface  
To Levator ani
- ↓ Anterior Surface  
By Pubo Prostatic Ligament

### ● PARTS

- ↓ Peripheral portion 70% of Glandular Prostate
- ↓ Central Portion
- ↓ Anterior Zone.

- ARTERIAL SUPPLY -**
- Inferior Vesical Artery
  - Middle Rectal Artery
- VENOUS DRAINAGE -**
- Prostate Venous Plexus
  - Pudendal Plexus
  - Internal Iliac Vein
- NERVE SUPPLY -**
- Inferior Hypogastric Plexus
- LYMPHATIC DRAINAGE -**
- External- Iliac lymph Nodes
  - Internal- Iliac lymph Nodes
  - Sacral- Lymph Nodes

# FEMALE REPRODUCTIVE ORGAN



## 1. MONS PUBIS

- Is rounded eminence present in front of the Pubis Symphysis.
- It is formed by accumulation of Subcutaneous fat.

## 2. LABIA MAJORA

- Thick fold of skin enclosing fat.
- They form the lateral boundaries of the Pudendal cleft.

### Commisure

- ```

    graph TD
      A[Commisure] --> B[Ant. Commissure]
      A --> C[Post. Commissure]
  
```
- The layer ant ends are connected each other below the Mons pubis.
  - The skin connecting the less prominent post. end of the Labia Majora

## 3. LABIA MINORA

Two thin folds of skin which lie within the Pudendal Cleft.

- ```

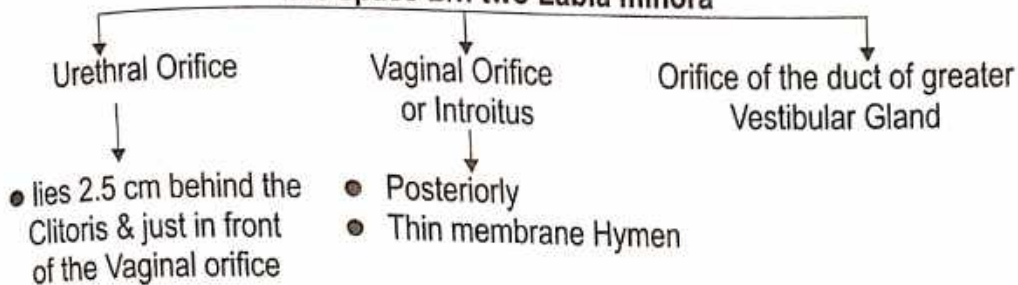
    graph TD
      A[Two thin folds of skin which lie within the Pudendal Cleft.] --> B[Anteriorly]
      A --> C[Posteriorly]
      B --> D[Each Labium Minus splits into two layers]
      D --> E[Upper Layer]
      D --> F[Lower Layer]
      C --> G[Two Labia minora meet to form the Frenulum of the Labia minora.]
  
```
- It joins the corresponding layer of opposite side to form the Prepuce of the Clitoris
  - It's two sides join to form the Frenulum of the Clitoris.

## 4. CLITORIS

- An Erectile organ, Homologus with penis
- It lies in the ant. part of Pudendal cleft
- The body is made up of two Corpora Caverosa enclosed in a fibrous sheath & partly separated by an pectin form septum Corpus Spongiosum is absent.
- Each Corpus Caverosum is attached to the Ischiopubic Rami.
- The down turned free end of Clitoris is formed by a rounded Tubercle glands clitoridis which caps the free end of Corpora.
- The Gland is made up of erectile tissue continuously corpora posteriorly with the commissural venous plexus uniting Right & Left bulbs of vestibule called bulbar commissure.

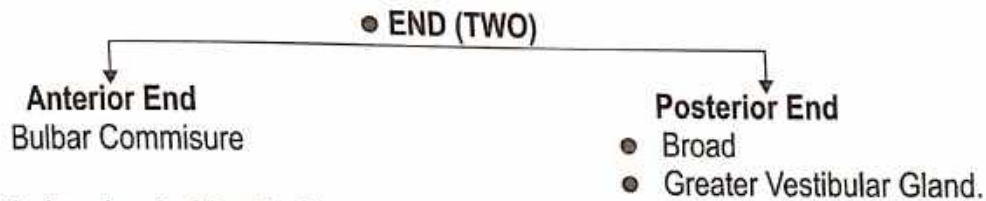
## 5. VESTIBULE OF THE VAGINA

It is space B/n two Labia minora



## 6. BULBS OF VESTIBULE

- Two Oval bodies of erectile tissue that correspond to the two halves of the bulb of the Penis.
- The bulb lie on either side of vaginal & urethral orifices superficially to Perineal membrane.



### Greater vestibular gland of Bartholin -

- Homologous with Bulbourethral gland of Couper in the male
- Lie in the Superficial perineal space each duct (glands) open at the side of Hymen between the Hymen & the Labium minus

### • Vagina

**Name of Organ :**

- According to Ayurveda - योनिद्वार
- According to Modern - Vagina (Kalpos)

The vagina is a fibromuscular canal forming the Female Copulatory organ. The term Vagina means a "Sheath"

**Situation :**

- From Vulva to the Uterus
- Behind the Bladder & the Urethra
- In front of Rectum & Anal canal.

**Direction :** In the erect posture the Vagina is directed Upward & Backward

- Long axis of Uterus forms an angle of  $90^\circ$  with long axis of vagina.

**Size :**

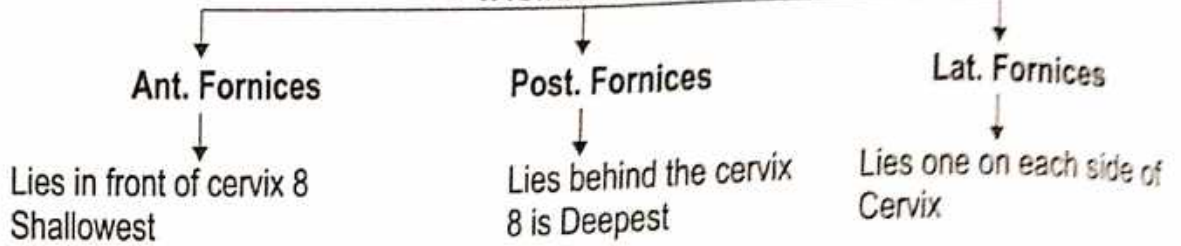
Length : 8 cm (Ant. wall of Vagina)  
10 cm (Post. wall of Vagina)

**Shape :** Lumen is Circular

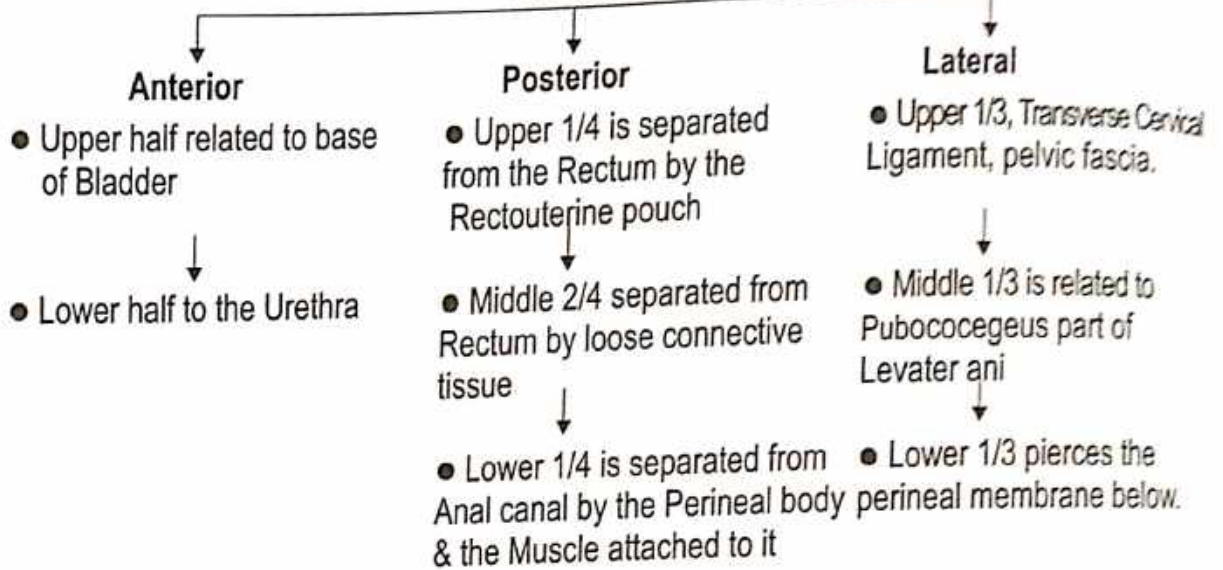
### Fornices of Vagina

- The anterior of the upper part of the Vagina is in the form of a circular groove that surrounds the protruding Cervix.
- The groove becomes progressively deeper from before backward and is arbitrarily divided into four parts called vaginal fornices.

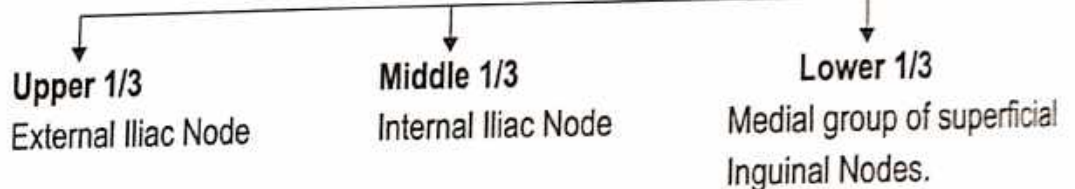
● **VAGINAL FORNICES**



● **RELATION**



● **LYMPHATIC DRAINAGE**



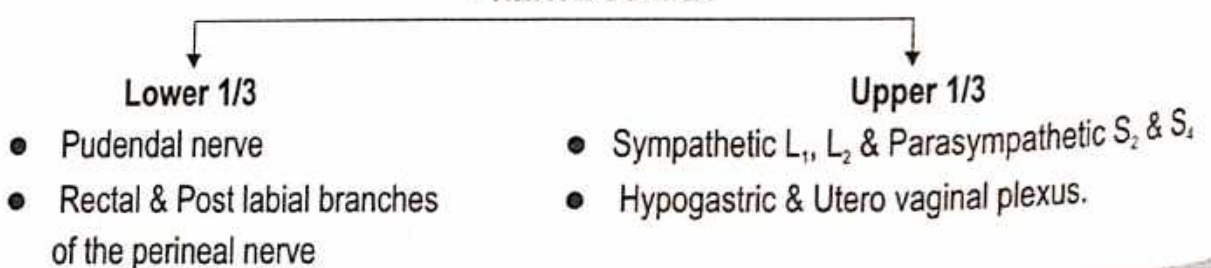
● **ARTERIAL SUPPLY**

- The main artery supplying it the vaginal branch of the Internal Iliac Artery
- Cervicovaginal branch of the Uterine artery
- Middle Rectal & Internal Pudendal arteries.
- Vaginal azygos arteries.

● **VENOUS DRAINAGE**

The rich Vaginal venous plexus drains into the Internal iliac Vein through the vaginal veins which accompany the Vaginal arteries.

● **NERVE SUPPLY**



**UTERUS**

Name of Organ : • According to Ayurveda - मूत्राशय

• अशय मूत्राशयः स्त्री ।

• मूत्राशयः मूत्रं मूत्राशयं यतिष्ठति ।

• यत्र मूत्राशयः स्यात् तत्र मूत्राशयः ।

• मूत्राशयः मूत्रं मूत्राशयं यतिष्ठति ।

• मूत्राशयः मूत्रं मूत्राशयं यतिष्ठति ।

(१३ मं. ५/४)

(१३ मं. ५/५)

(१३ मं. ५/६)

(१३ मं. ९/५)

Shape : Pyramiform  
 Measurement : • Length = 7.5 cm • Width = 5 cm • Thickness = 2.5 cm • Weight = 30-40 gm

Location : Pelvis B/n Bladder and Rectum

External Features - • Communication



- Convex, Upper end of Uterus
- Covered with Peritoneum directed forward when bladder empty.
- SURFACE (TWO)

**Anterior/Vestibul**

- Flat
- Covered with Peritoneum
- Posterior or superior wall of Uterovesical Pouch

**Posterior/Infestinal**

- Convex
- Covered with Peritoneum
- Ant. wall of Rectouterine Pouch

**Lateral Borders (Two)**

- Convex and Rounded
- Attachment to Broad Ligament of uterus connects lateral pelvic wall
- Attachment to Round Ligament

**CERVIX**

- Cylindrical, 2.5 cm
- Lower part project into anterior wall of Vagina.



**Anteriorly**

- Urinary bladder

**Posteriorly**

- Rectouterine pouch
- VAGINAL PART

**Each Side**

- Ureter & Uterine artery

- Project into anterior wall of vagina
- Cervical canal opens into vagina by external orifice

**Nulliparous Woman**


- Not born children
- External orifice small and circular

**Multiparous Woman**

- External orifice bounded anterior & posterior lips both contact with posterior wall of vagina

**Normal Position and Angulation**

- Anteflexion
- Long axis of uterus form angle 50° with long axis of vagina
- Forward bending of uterus relative to vagina
- Anteroflexion
- Uterus slightly flexed on itself angle-125°




**Round ligament of Uterus**

- Chiefly by two Uterine Arteries
- Branch of Ant. division of Internal Iliac Artery
- Transverse cervical ligament
- Uterosacral Ligament
- ARTERIAL SUPPLY
- Partly Ovarian Arteries

**VENOUS DRAINAGE**

- Vein form plexus
- Plexus drains through Uterine/Ovarian & Vaginal vein into Internal Iliac vein.

**LYMPHATIC SUPPLY**



**NERVE SUPPLY**



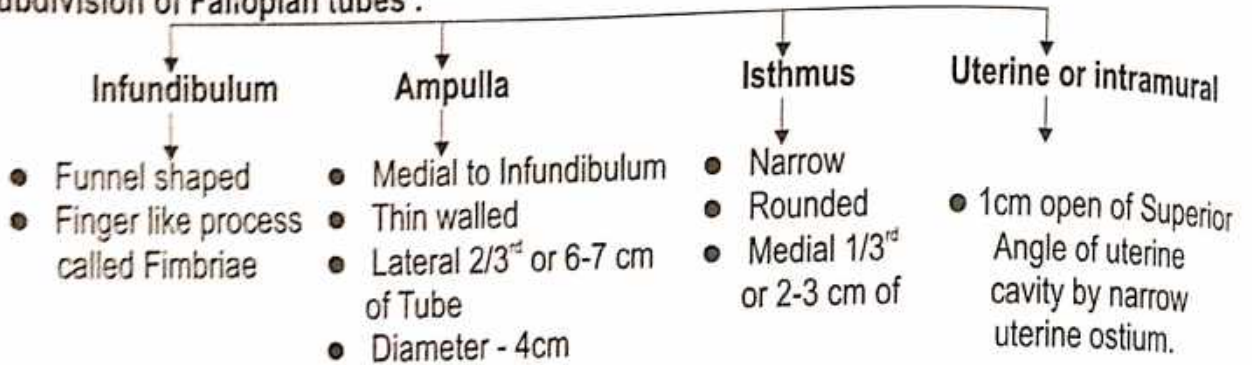
## UTERINE TUBE

**Name :** ● According to Ayurveda - चीजवाहिनी

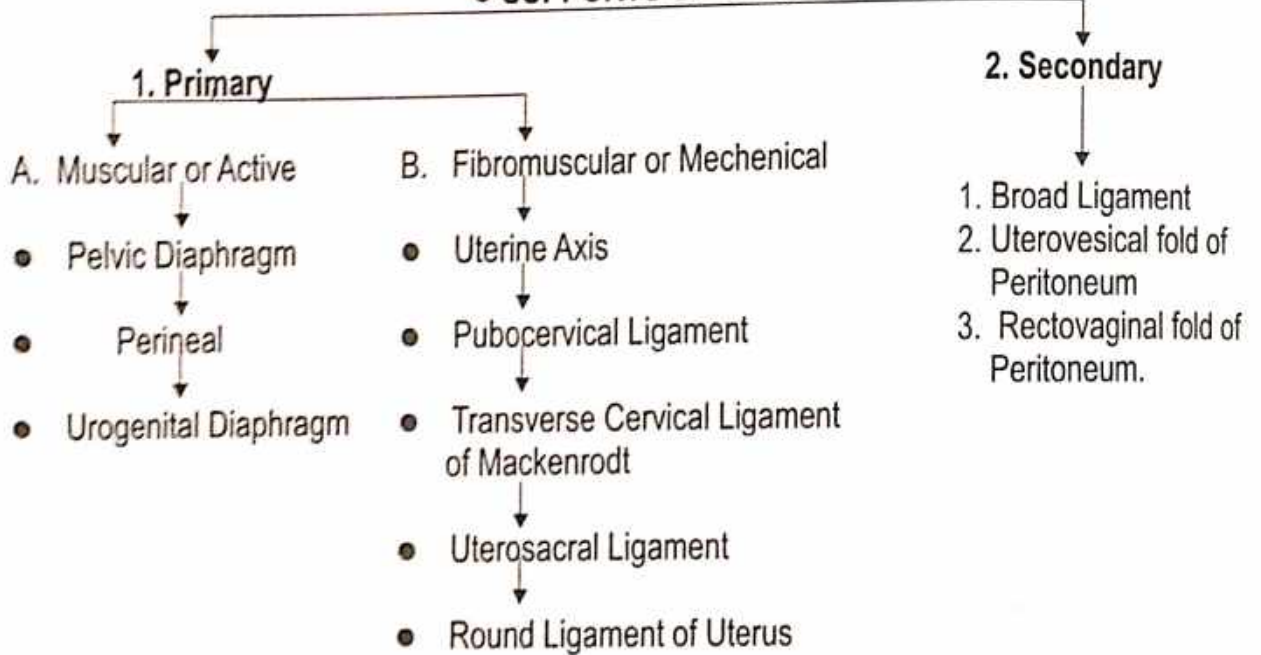
● शुक्रवहे द्वे शुक्रप्रादुर्भावाय, द्वे विसर्गाय, ते एव रक्तमभिवहतो विसृजतश्च नारीणामार्तवसंज्ञम् । (सु.शा. 9/6)

**Situation :** Free upper margin of Broad Ligament of Uterus ● **Length :** 10 cm

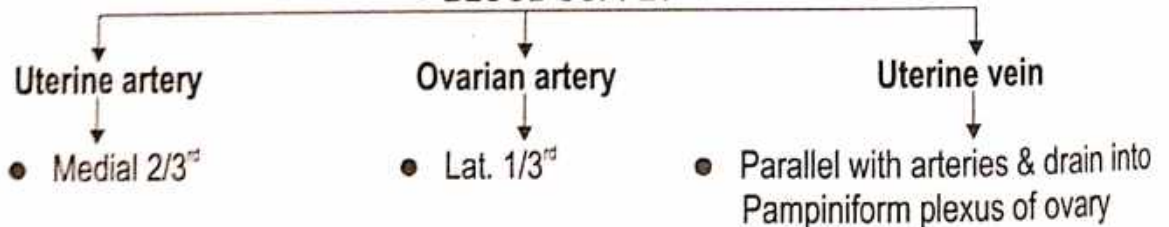
**Subdivision of Fallopian tubes :**



### ● SUPPORTS OF UTERUS

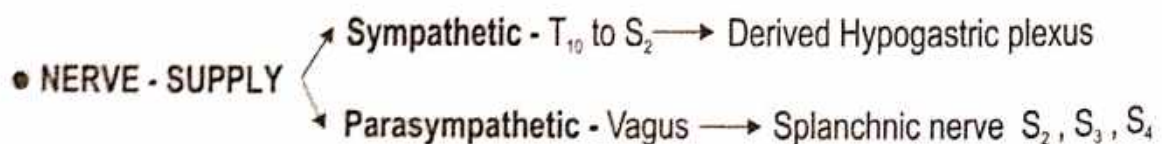


### ● BLOOD SUPPLY



### ● LYMPHATIC DRAINAGE

Tubal lymphatics join the lymphatics from the ovary and drain with them into the Lateral Aortic and Preaortic nodes.



## OVARY

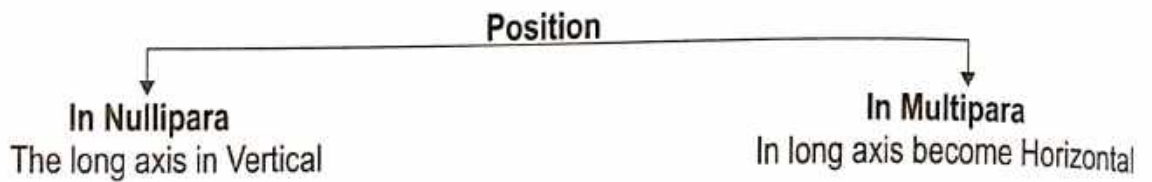
**Name :**

- According to Ayurveda - बीजकोष
- नाभिडिम्भास्तबस्तयः ।

(अ.ह.शा. 3/12)

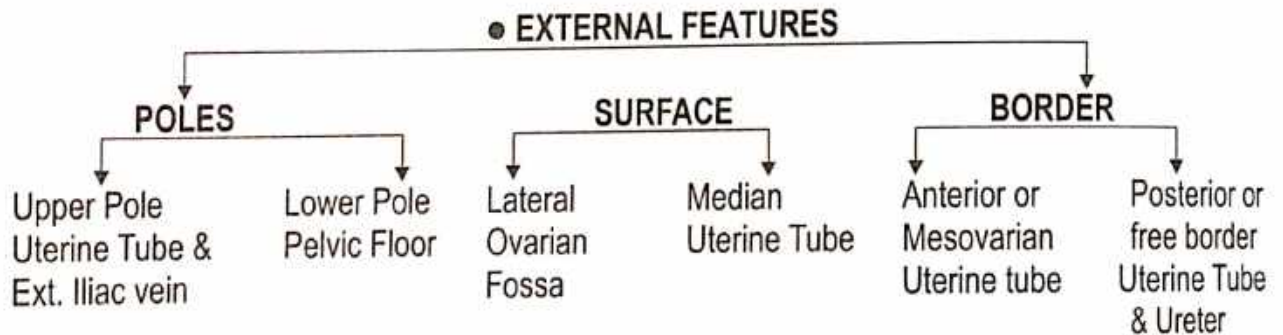
**Shape :** Oval Shape/ Almond Shape.

**Location :** Ovarian Fossa in the lateral pelvic wall.



**Measurement :** ● Length = 3 cm      ● Width = 1.5 cm      ● Thickness = 1 cm

**Colour :** Before Puberty - Greyish pink colour  
After Puberty - Pinkish Grey.



**Relation :** Peritoneal - Intraperitoneal / Anterior Border or Mesovarium Border.

### ● ARTERIAL SUPPLY

The Ovarian - Artery

### ● VENOUS DRAINAGE

The Vein emerge at the Hilus and form a Peritoneum plexus around the artery the plexus condenses into a single ovarian vein near the pelvic inlet.

### ● LYMPHATIC DRAINAGE

Lateral Aortic nodes - Pre Aortic nodes.

### ● NERVE SUPPLY

(a) Ovarian plexus - Derived from the Renal Aortic & Hypogastric Plexus

(b) Sympathetic - T<sub>10</sub> - T<sub>11</sub>

© Parasympathetic Nerve - S<sub>2</sub>, S<sub>3</sub>, S<sub>4</sub>

### ● APPLIED ASPECT

Cyst of Ovary

# NERVOUS SYSTEM

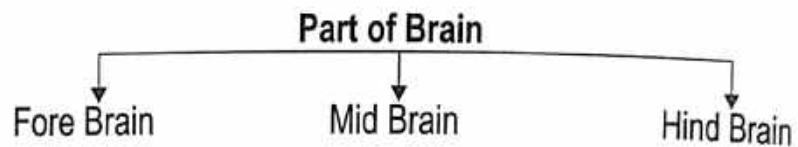
## FORE BRAIN

शिर -

प्राणाः प्राणभृतां यत्र श्रिताः सर्वेन्द्रियाणि च ।  
यदुत्तमागंमगानां शिरस्तदभिधीयते ।

(च.सू. 17/12)

Brain - Weight - 1200 - 1500 gm.



Origin -

Ectoderm

## FORE BRAIN

- 
- ```
graph TD; A[FORE BRAIN] --> B[1. Telencephalon]; A --> C[2. Diencephalon];
```

## 1. TELECEPHALON

**Cerebral Hemisphere**  
(मस्तलुङ्ग प्रवर्ध)

1. Frontal lobe
2. Parietal lobe
3. Occipital lobe
4. Temporal lobe
5. Corpus callosum

**Lateral Ventricle**  
(त्रिपथ गुहा)

1. Anterior horn
2. Posterior horn
3. Inferior horn

## 2. DIENCEPHALON

- 
- ```
graph TD; A[2. DIENCEPHALON] --> B[1. Thalamus]; A --> C[2. Metathalamus]; A --> D[3. Hypothalamus]; A --> E[4. Epithalamus]; A --> F[5. Subthalamus];
```

### 1. Thalamus

Anterior Nucleus

Medial Nucleus

Internal Nucleus

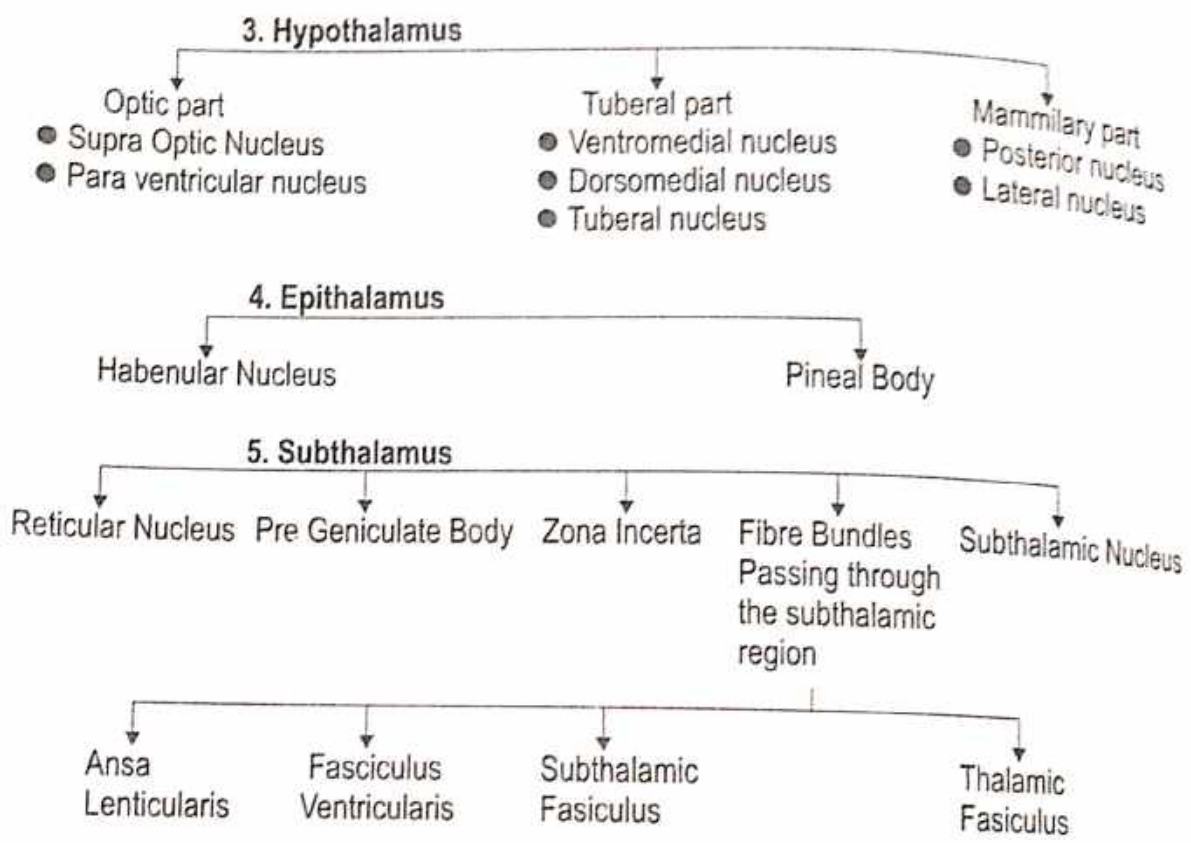
Ventral Ant. Nucleus    Ventral Lat. Nucleus    Ventral post. Nucleus

### 2. Metathalamus

Medial Geniculate Body


Lateral Geniculate Body



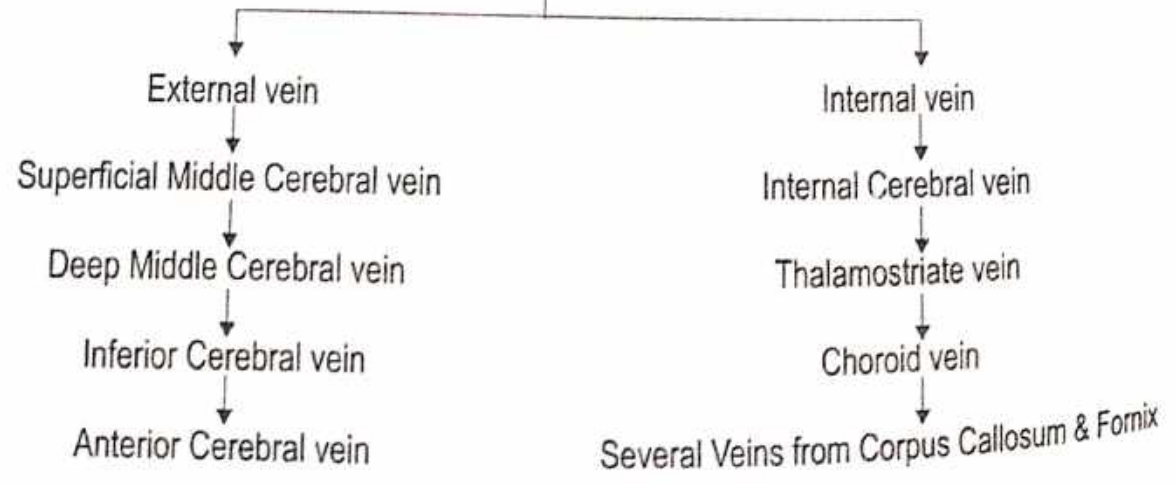


● **BLOOD SUPPLY**

**ARTERIAL SUPPLY**



**VENOUS DRAINAGE**



## MID BRAIN

**Origin** - Ectodermal

**System of Organ** - Nervous system

स्त्रोतस - नाडी संस्था स्त्रोतस (वातनाडी संस्थान)

- Midbrain connects the 3<sup>rd</sup> ventricle (diocoel cavity) with the 4<sup>th</sup> ventricle (Metacoel cavity)
- The Mid brain passes through the Tentorial notch.

### Relation

#### On each side

- Parahippocampal gyrus
- Optic tracts
- Posterior Cerebral artery
- Basal Vein
- Trochlear Nerve
- Geniculate Bodies

#### Anteriorly

- Inter Peduncular structure

#### Posteriorly

- Splenium of the Corpus callosum
- Great Cerebral vein
- Pineal Body
- Post ends of Right & Left Thalami.

### Subdivision

### MESENCEPHALON

Tectum  
(छद)

Made up

Right Left Sup. & Inf. Colliculi

- The Sup. Colliculus connected to the lateral Geniculate body by the **Superior Brachium**

Cerebral Aqueduct  
(ब्रह्मद्वार सुरंगा)

Cerebral Peduncle  
(मस्तिष्क मृणालक)

Subdivided by

Crus Cerebri (Ant.)

Substantia Nigra (Medially)

Tegmentum (Post.)

### ● Internal Structure of Mid Brain

1. Transverse section of Mid Brain at the level Inferior Colliculi

1. Gray matter

2. White matter

#### 1. Grey Matter

1. The central (Periaqueductal)

Grey matter contains -

- The nucleus of the Trochlear nerve in the Ventromedial part.

1. The Inferior Colliculus

receives - afferent from the Lateral Lemniscus & gives afferents to the medial Geniculate body

1. The Substantia Nigra

is a lamina of grey matter made up of deeply pigmented nerve cells

## 2. White Matter

1. Crus Cerebri contains-
  - The Cortico spinal tract in the middle
  - Frontopontine fibres in the middle 1/6
  - Temporopontine, Parietopontine & Occipitopontine fibres in the lateral 1/6
2. Tegmentum contains-
  - The Lemniscus
  - The decussation of the sup. Cerebellar Peduncle is seen in the median plane
  - The medial tract & the supraspinal tract.
  - The Tectospinal tract & Medial Longitudinal bundle
3. The Trochlear Nerve Passes laterally & dorsally round the central Grey matter
  - It decussate in the sup. medullary vellum & emerges lateral to the Frenulum Veli.

## II. Transverse section of Mid brain at the level of Superior Colliculi :

### 1. Grey Matter

1. Central Grey matter contains -
  - a Mesencephalic nucleus of the Trigeminal Nerve in the lateral part
  - b The Nucleus of Oculomotor nerve with Edinger Westphal Nucleus in the ventromedial part.

### 1. Grey Matter

2. Sup. Colliculus receives afferent from the Retina (visual) various other centres gives afferent to the spinal cord (Tentorial Tract)

### 2. White Matter

3. Substantia Nigra is a lamina of Grey matter made up of deeply pigmented nerve cells.

## 2. White Matter

1. Crus Cerebri contains-
  - The Cortico Spinal Tract
  - Frontopontine fibres
  - Temporopontine, Parietopontine & Pontine Fibers.
2. Tegmentum contains-
  - Lemnisci
  - The decussation of the Tectospinal & Tectobular tracts form this dorsal Tegmental decussation.
  - The decussation of the Rubrospinal tract from ventral Tegmental decussation
  - Medial Longitudinal bundle
  - Emerging fibres of Oculomotor Nerve.
3. Tectum Shows -
  - The posterior commissure connecting two superior colliculi.

## Development of Mid Brain -

1. From Middle Vesicle the Mid brain Alar lamina cells multiply & fuse to form 4 colliculi.
2. These cells also migrate ventrally to form Red Nucleus & Substantia Nigra.
3. The Basal Lamina forms the Crus Cerebri.

## HIND - BRAIN

Origin - Ectoderm  
 System of organ - Nervous system • स्रोतस- नाडी संस्था स्रोतस (वातनाडी संस्थान)

### • Division of Hind Brain

- 1. Pons  
(उष्णिषक)
- 2. Cerebellum  
(धम्मीलक/लघुमस्तिष्क)
- 3. Medula Oblangata  
(सुपुम्ना शीर्षक)
- 4. Fourth Ventricle  
(प्राणगुहा)

### 1. Pons - Surface (Two)

#### External Features :

#### Ventral or Anterior Surface (Convex)

- Transversely - Striated
- Median Plane - Basilar Sulcus Present
- Laterally - Middle Cerebellar Peduncle

#### Dorsal/Posterior Surface

#### Borders (Two)

#### Upper Border

- Form lower edge of Interpeduncular Fossa
- Blood supply - Superior cerebellar artery

#### Lower Border

- It is separated by cleft of medulla
- Attachment - 6<sup>th</sup>, 7<sup>th</sup>, 8<sup>th</sup> Cranial nerves
- Blood supply - Inf. Cerebellar artery

#### Internal Feature :

#### Parts (In Transverse Section)

#### Basilar Part(Attachements)

- Upward - Crura Cerebri
- Downward - Pyramid of Medulla
- Middle Side - Cerebellar Peduncle

#### Tegmental Part

- It Separates Ventral Floor of Fourth Ventricle

#### Relation

Upper - Mid brain

Lower - Medulla

#### Ascending Tracts

- (1) Anterior spinocerebellar tracts. (2) Spinothalamic tract.  
 (3) Medial lemniscus. (4) Lateral lemniscus.

#### Decending Tracts

- (1) Cortico bulbospinal tract. (2) Rubrospinal tract.  
 (3) Medial longitudinal fasciculus. (4) Tectobulbospinal tract.

#### Cranial nerve, Nuclei and their related tracts

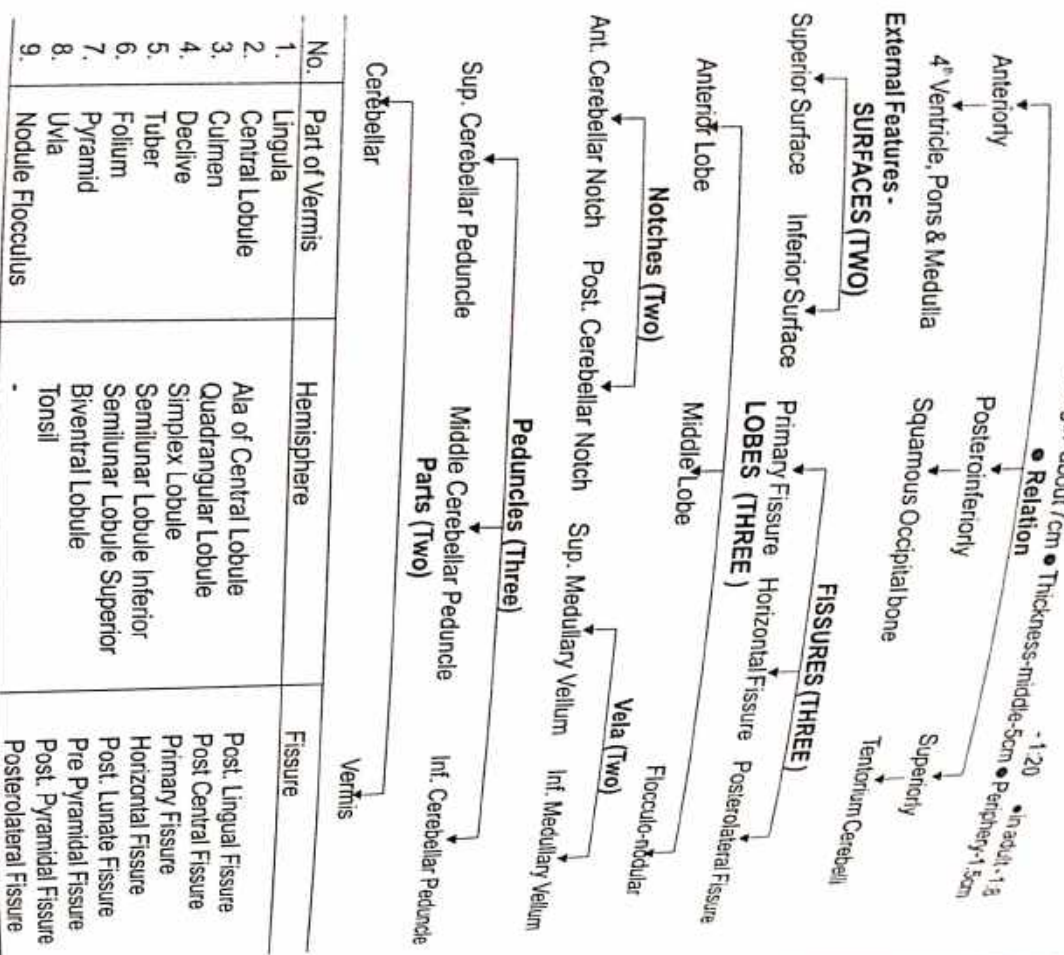
1. Spinal trigeminal nucleus & tract.
2. Trigeminothalamic tract.
3. Nucleus of abducent nerve.
4. Facial nucleus & nerve.
5. Trapezoid body.
6. Superior Olivary nucleus.
7. Lateral & sup. vestibular nuclei.
8. Trigeminal complex - • Main sensory nucleus.  
 • Mesencephalic nucleus. • Motor nucleus.

#### Other Nerve & Nuclei

1. Reticular formation.
  2. Central Tegmental Tract.
  3. Pontine nuclei.
  4. Corticopontine Fibres.
  5. Pontocerebellar Fibres.
  6. Middle Cerebellar Peduncle.
  7. Sup. Cerebellar Peduncle.
- Function** - Control of mood & sleeping, awareing stage.

## CEREBELLUM

**Situation** - • Posterior Cranial Fossa. • Largest part of Hind Brain.  
**Shape** - Cuboid • **Weight** - 150 gm (average) • **Ratio B/n Cerebellum & Cerebrum** - • in children  
**Measurement** - • Breadth - 8-10cm • Length - about 7cm • Thickness - middle-5cm • Periphery - 1.3



**INTERNAL FEATURES**

**Cerebellar Cortex**

- Outer Grey matter is present on outer surface of cerebellum
- Inner white matter (arbor vitae)

**Three Layers**


1. Molecular layer
2. Purkinje neuron
3. Granular layer

Mossy fibres  
Climbing fibres

## MEDULLA OBLANGATA

(Upper Largest part of spinal cord)

**Situation** - • Anterior part of Post. Cranial Fossa.  
**Shape** - • Prismatic • Length - 3 cm • Breadth - 2 cm  
**Measurement** - • It present in lower half  
**Central Canal** - • Thickness - 1.25 cm



- INTERNAL FEATURES**
- (i) **Ascending Tract & their related Nuclei** -
1. Fasciculus Gracilis & Fasciculus Cuneatus.
  2. Nucleus Gracilis & Nucleus Cuneatus.
  3. Internal Arcuate fibres.
  4. Median Lemniscus.
  5. Spinothalamic Tract.
  6. Spine thalamic Tract.
  7. Spino Reticular Tract & Fibres.
  8. Accessory Cuneate nucleus.
- (ii) **Descending Tract & their related Nuclei** -
1. Cortico spinal Tract.
  2. Rubro spinal Tract.
  3. Vestibulo spinal Tract.
  4. Medial Longitudinal Fasciculus.
  5. Tecto Bulbo spinal Tract.
- (iii) **Cranial nerves & their related Nuclei & Tract** -
1. Spinal nucleus of Trigeminal Nerve & Tract.
  2. Trigeminothalamic Tract.
  3. Vestibular Nuclei.
  4. Solitary nucleus & Tract.
  5. Nucleus Ambiguous.
  6. Dorsal Motor nucleus of Vagus nerve.
  7. Nucleus of Hypoglossal nerve.
- (iv) **Other Tracts & Nerve** -
1. Reticular formation & nuclei.
  2. Inferior olive.
  3. Olivocerebellar tract.
  4. Inferior Cerebellar peduncle.

# FOURTH VENTRICLE

**Situation** → Diamond Shape.

**Relation** →

Anterior

- Upper half part of Pons & Medulla

Posterior

- Cerebellum

**Communication** →

Superiorly

- Cerebral aqueduct with III<sup>rd</sup> ventricle

Posteriorly

- Subarachnoid space by median apertures (Foramen magendei)

Laterally

- Subarachnoid space by lateral apertures (Foramen of Lushka)

**Recess (Three)**

Median Dorsal Recess

Lateral Dorsal Recess

Lateral Recess

**EXTERNAL FEATURES -**

**BOUNDARY**

Lateral wall

- Superior Cerebellar Peduncle.
- Middle Cerebellar Peduncle.
- Inferior Cerebellar Peduncle.
- Cuneate and Gracile Tubercles

Floor

- Median Sulcus
- Median Eminences
- Sulcus Limitans
- Vagal Triangle
- Vestibular Area
- Stria Medullaries

Roof

- Sup. Cerebellar Peduncle
- Sup. Medullary Vellum
- Inf. Medullary Vellum
- Taenia
- Tela - choroidea

# SENSORY ORGANS

## EYE BALL

Name of Organ → According to Ayurveda - नेत्र / चक्षुः

Origin → Ectoderm, Retina, Cornea, Lens.

Function → Vision

Shape → Almost Spherical [ "सुवृत्तं गोचरनाकारं" ]

(सू. 3. 1/10)

Size → Dia = 2.5 cm [विद्या, देवद्वयत वाङ्मन्यं त्वाङ्गुष्ठं तस्मिन् ।  
इत्युक्तं सर्वतः सारं हि यद्दन्वयनचक्षुर्वयम् ।

(सू. 3. 1/10)


System of Organ → Sensory organ of light receptor.

नेत्र विभाग -

शुद्धतानि च संकीर्ण्य पटनानि च तौचनं ।  
यथात्मं विज्ञानीयान् पंच पर्दं च पश्य च ।

(सू. 3. 1/14)


Features → Made up of 3 concentric coats



Refractive Apparatus - Cornea - Aquous Humour - Lens - Vitreous Body

### A) OUTER COAT

I. **SCLERA** - Opaque and forms the posterior 5/6<sup>th</sup> of the eye ball.



The Sclera is continuous anteriorly with the Cornea at the Sclerocorneal junction or Limbus. The Sclera is almost avascular, however the Loose connective tissue B/n the conjunctiva and Sclera called as episclera which is vascular.


### CORNEA -

- The cornea is transparent.
- It forms anterior 1/6<sup>th</sup> of the eyeball.
- Cornea is more convex than the Sclera.
- Cornea is avascular & is nourished by Lymph.
- Supplied by Ophthalmic nerve.

### B) MIDDLE COAT

#### I. CHOROID -

- Thin pigmented layer.
- Separates the posterior part of the Sclera from Retina.



#### II. CILIARY BODY -

- Thickened part of the Uveal Tract.
- Triangular in cross section.
- About 70 ciliary processes.
- Suspensory ligament.
- Parasympathetic nerve.
- Oculomotor nerve.

#### III. IRIS -

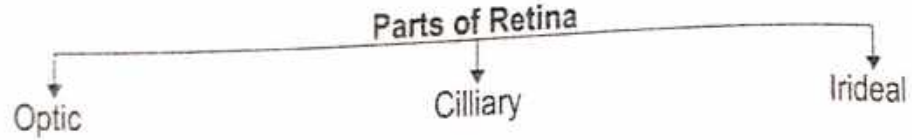
- Iris is the anterior part of the Uveal Tract.
- It forms a circular curtain with opening in the centre, called the Pupil.
- Placed vertically B/n the Cornea and the Lens.
- The colour of the iris is determined by the number of pigment cells in its connective tissue.
- Supplied by sympathetic nerve.

### C) INNER COAT

#### I. RETINA -

- Thin.
- Continuous posteriorly with Optic nerve.
- Inner surface is in contact with the Hyoid membrane of the vitreous body.
- Light Receptors of Eye -

- a) Rods
- b) Cones



## II. AQUEOUS HUMOUR -

- Clear fluid.
- Intra Ocular pressure maintain Optical dimensions.
- Nourish the vascular tissue of cornea & lens.
- The aqueous humour is rich in ascorbic acid, glucose & amino acids.

## III. LENS -

- Transparent.
- Biconvex.
- Diameter = 1 cm.
- Lens is enclosed in a transparent, structureless elastic capsule.
- Suspensory ligament of the lens for retains the lens in position.
- Contribute 15 diopteric power out of Total 58 diopteric power of Eye ball

## IV. VITREOUS BODY -

- Colourless, Jelly like transparent mass.
- Posterior  $4/5^{\text{th}}$  of Eyeball.
- Enclosed in a delicate homogenous hyloid membrane.

Mesoderm → Choroid, Sclera.

नेत्र की पांचभौतिकता - पलं भुवोऽग्नितो रक्तं वातात् कृष्णं सितं जलात् ।  
आकाशादश्रुमार्गाश्च जायन्ते नेत्रबुदबुदे ।

(सु.उ. 1/11)

मण्डल - पक्ष्मवर्त्मश्चेतकृष्णदृष्टीनां मण्डलानि तु ।

(सु.उ. 1/15)

संधियाँ - पक्ष्मवर्त्मगतः संधिर्वर्त्मशुक्लगतोऽपरः ।  
शुक्लकृष्णगतस्त्वन्यः कृष्णदृष्टिगतोऽपरः ।  
ततः कनीनकगतः षष्ठश्चापागगः स्मृतः ।

(सु.उ. 1/16)

पटल - द्वै वर्त्म पटले विद्याच्चत्वार्यन्यानि चाक्षिणि ।

(सु.उ. 1/17)

तेजोजलाश्रितम् बाह्यं तेष्वन्यत् पिशिताश्रितम् ।  
मेदस्तृतीयं पटलमाश्रितन्वस्थिचापरम् ॥

(सु.उ. 1/18)



## EAR

Name of Organ - According to Ayurveda - कर्ण

● “द्वै कर्ण शुक्लिके, द्वी कर्ण पुत्रकी”

(च.शा. 7/11)

● आन्तरिक्षास्तु - शब्दः शब्देन्द्रियं सर्वच्छिद्रसमूहो विविक्तता च ।

(सु.शा. 1/20)

कर्ण एक इन्द्रिय -

● कर्ण-नेत्र-भ्रु-शंख-अंस-गण्ड-कक्ष-स्तन-वृषण-पार्श्व-स्फिग-जानु-बाहु-रूपभृतयो द्वै द्वै । (सु.शा. 5/3)

कर्ण एक स्रोतस् -

● श्रोत्रत्वक्चर्क्षुजिह्वा घ्राण ..... पंचबुद्धिन्द्रियाणि ।

(सु.शा. 1/3)

● श्रवण-नयन-वदन-घ्राण-गुद-मेढ्राणि नवस्रोतांसि नराणां बर्हिमुखानि ।

(सु.शा. 5/9)

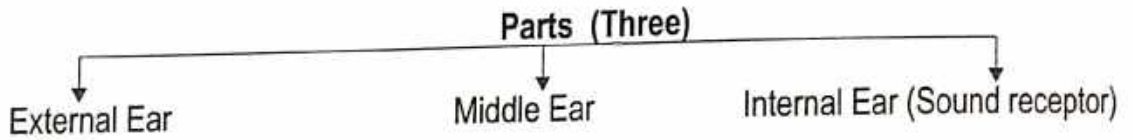
कर्ण एक तरुणास्थि - ● घ्राणकर्णग्रीवाक्षिकोषेषु तरुणानि ।

(सु.शा. 5/22)

कर्ण एक संधि - ● श्रोत्रश्रृंगाटकेषु शंखावर्ताः ।

(सु.शा. 5/32)

System of Organ → Sensory organ (For Hearing & Balance)



Function - Hearing and maintain Equilibrium.


### 1. External Ear

Origin - Ectodermal

● External ear consists of :-

1. The Auricle or Pinna.
2. The External Acoustic Meatus.

#### ● PARTS OF AURICLE / PINNA



● The large depression called the Concha, it leads into the external acoustic meatus.

Blood Supply :-

Posterior Auricular & Superficial Temporal arteries.

Lymphatic Drainage :-

Lymph drains into the preauricular, postauricular & superficial cervical lymph nodes.

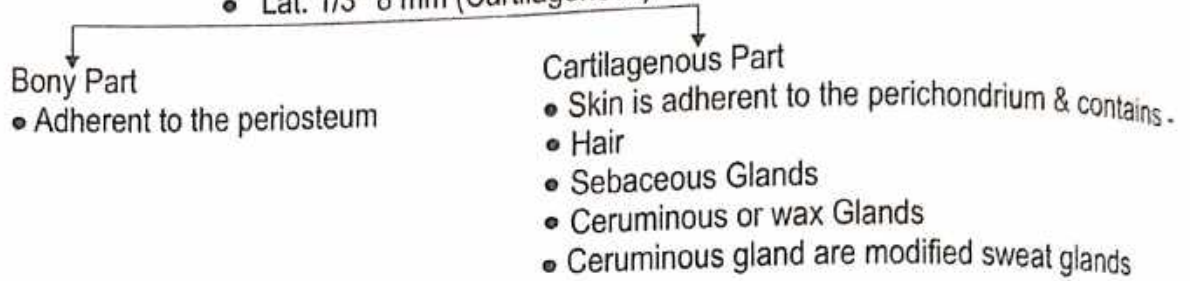
Nerve Supply : 1. Auriculo - Temporal nerve.

2. Great Auricular nerve.

3. Facial nerve.

## • EXTERNAL ACOUSTIC MEATUS

- "S" Shaped Canal
- 24 mm long →
  - Medial 2/3<sup>rd</sup> 16 mm (Bony)
  - Lat. 1/3<sup>rd</sup> 8 mm (Cartilagenous)



**Bloody Supply** - • Superficial Temporal arteries. • Posterior Auricular arteries. • Maxillary artery.

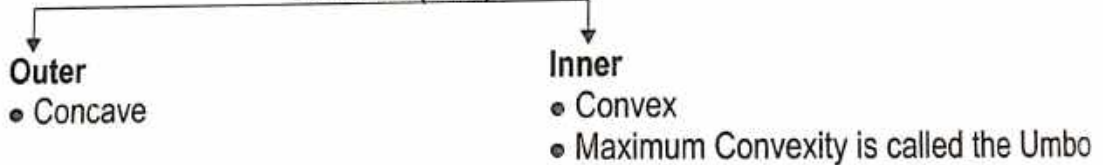
**Lymphatic Drainage** - Lymph pass to Preauricular, Postauricular & Superficial Cervical lymph nodes.

### Nerve Supply

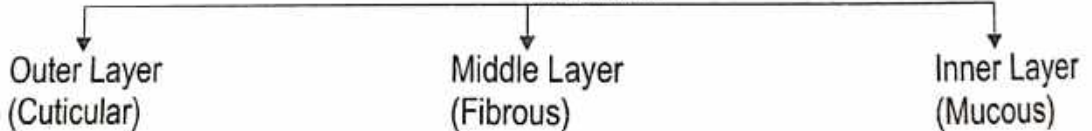


**Tympanic Membrane** - • Thin, Translucent partition B/n the External Acoustic Meatus & Middle Ear.  
• Oval shaped, measuring 9 x 10 mm

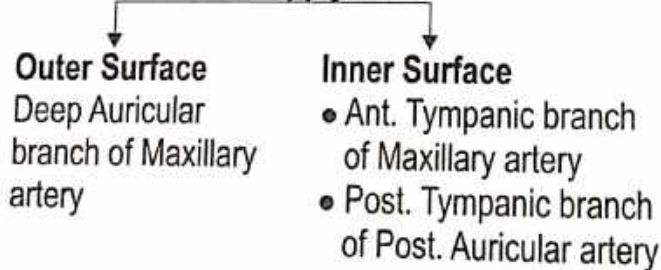
### Surfaces (Two)




### Structure



### Blood Supply

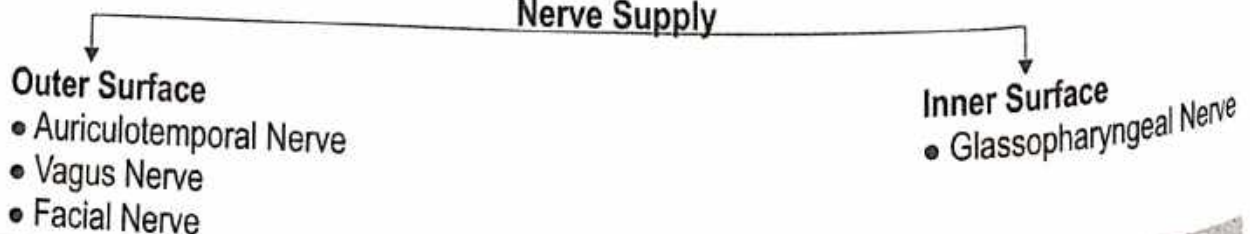


### Venous Drainage



**Lymphatic Drainage** - Lymphatics pass to the Preauricular & Retropharyngeal lymph nodes.

### Nerve Supply



## 2. MIDDLE EAR

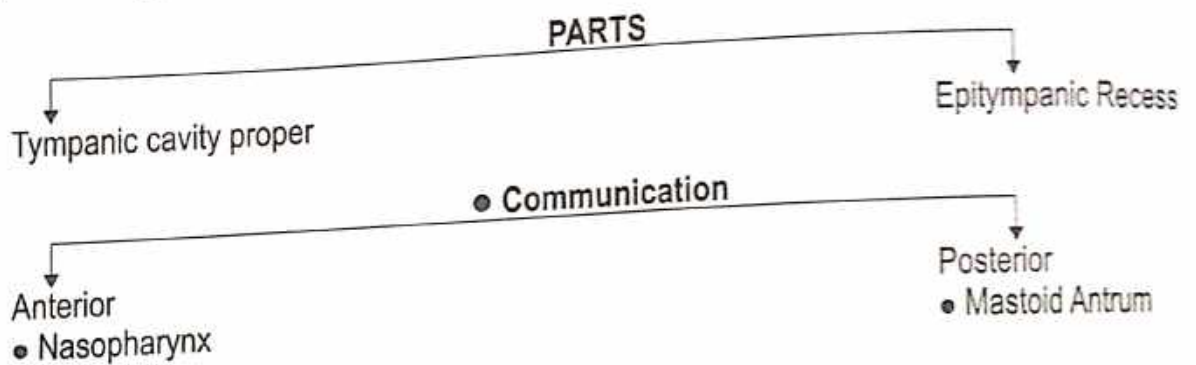
- Also called Tympanic Cavity or Tympanum.
- The Middle ear is a Narrow air filled Space.

**Origin** → Endodermal.

**Situation** → Petrous part of Temporal bone B/n External ear & Internal ear.

**Shape** → Cube like Shaped.

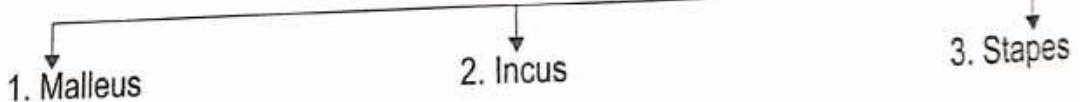
**Size** → Vertical and Anteroposterior Dia 15 mm.



### • BOUNDRIES

1. Roof / Tegmental Wall.
2. Floor / Jugular Wall.
3. Anterior / Carotid Wall.
4. Posterior / Mastoid Wall.
5. Lateral / Membranous Wall.
6. Medial / Labyrinth Wall.

### Middle Ear Contents Three Small Bones



- Ligaments of Ear Ossicles.
- Two muscles - (i) Tensor tympani (ii) Stapedius.
- Vessels Supplying and draining the Middle ear.
- Air.
- Nerves - Chorda Tympani and Tympanic Plexus.

**ARTERIAL SUPPLY -** 1. Maxillary artery. 2. Posterior Auricular artery.

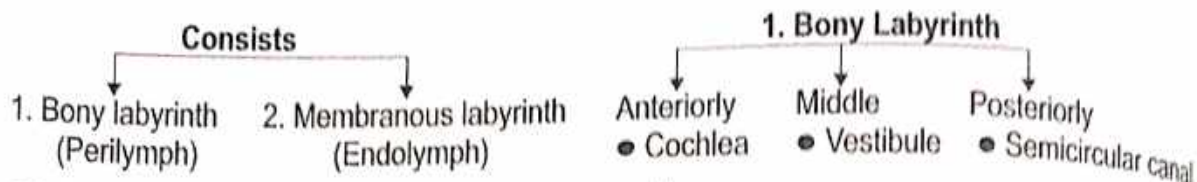
**VENOUS DRAINAGE -** Drain Into Superior Petrosal sinus and Pterygoid plexus of veins.

**LYMPHATIC DRAINAGE -** Preauricular and Retropharyngeal Lymph nodes.

**NERVE SUPPLY -** 1. Glossopharyngeal nerve. 2. Corticotympanic nerve.

### 3. INTERNAL EAR (LABYRINTH)

**Origin** - Ectodermal - • Lies in the Petrous part of the Temporal bone.



**COCHLEA** - • Resembles the shell of common snail.

• Divided by Spiral Lamina →

Scala Vestibuli

Scala Tympani

**VESTIBULE** - • The Central part of bony Labyrinth. • It lies Medial to the Middle ear cavity.

**SEMICIRCULAR CANAL** - Three bony Semicircular canals

Anterior / Superior

Posterior

Lateral

#### 2. MEMBRANOUS LABYRINTH

• Membranous labyrinth are Specialized to form Receptors for Sound "**Organ of Corti**".

• For the Static balance the **Maculae**. • For kinetic balance The **Cristae** (ampulla).

Duct of cochlea

Sacculle

Anteroinferior part  
of vestibule

Semicircular  
duct

Utricle

Posterosuperior part of Vestibule  
• Larger

**Ossicles** - Malleus, Incus, Stapes. • **Muscles** - Tensor Tympani, Stapedius.

**ARTERIAL SUPPLY** - • Basilar artery. • Posterior Auricular artery.

**VENOUS DRAINAGE** - • Superior petrosal sinus / Transverse Sinus

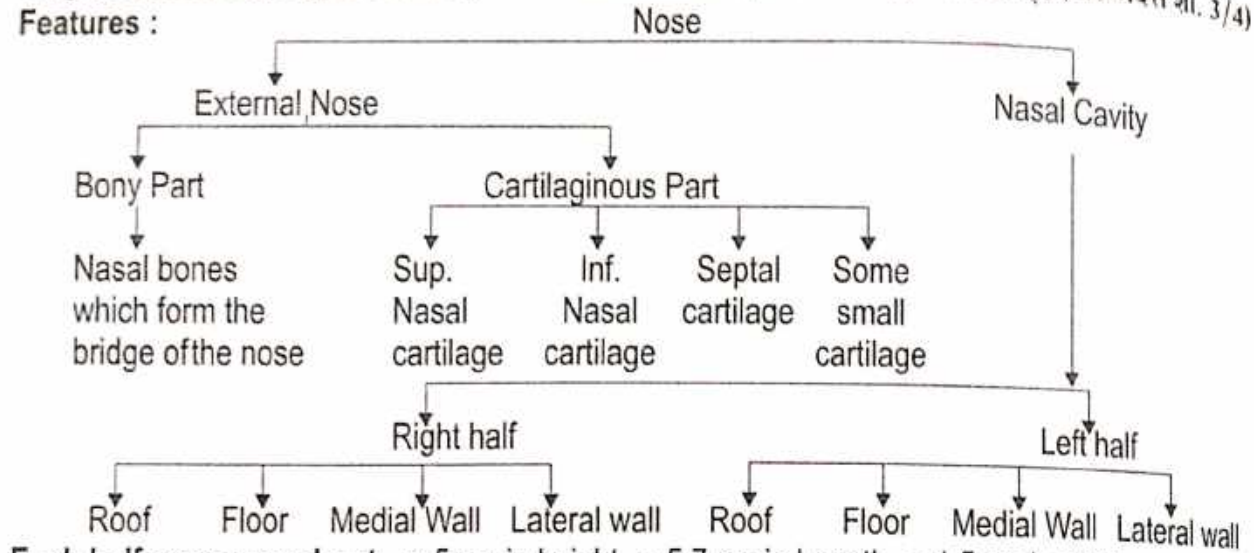
# NOSE

**Name of Organ -** ● According to Ayurveda - नासा  
● नासाहि शिख्रो द्वारम् (च.सि. 9/88)

**Origin :** Ectoderm (Organ of smell)

● नासायां त्रीणि (सु.शा. 5/21)  
● नासायां विशिष्ट एकदेशे घ्राणेन्द्रियाधिष्ठानम् । (अरुणदत्त शा. 3/4)

**Features :**

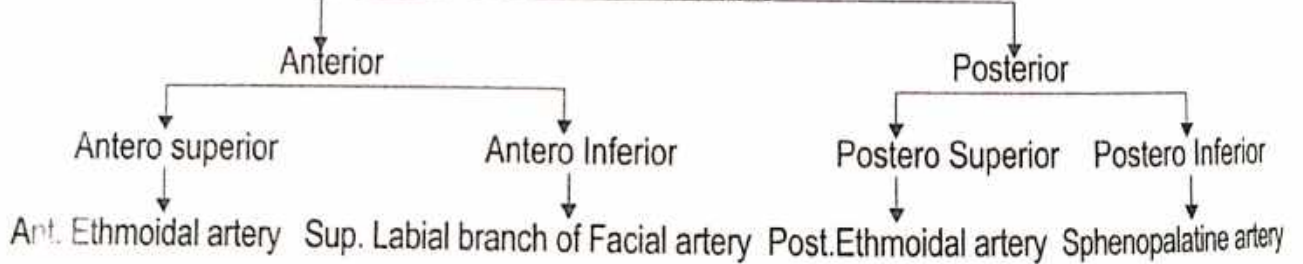


**Each half measures about -** ● 5 cm in height ● 5.7 cm in Length ● 1.5 cm in width

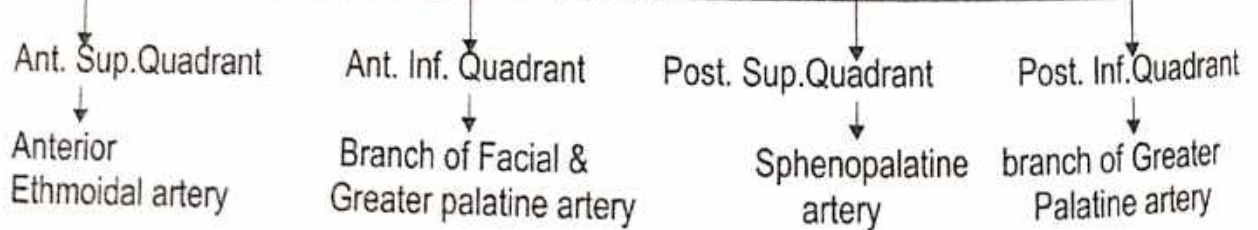
**Nasal Septum :** Median osteocartilaginous partition B/n Two halves



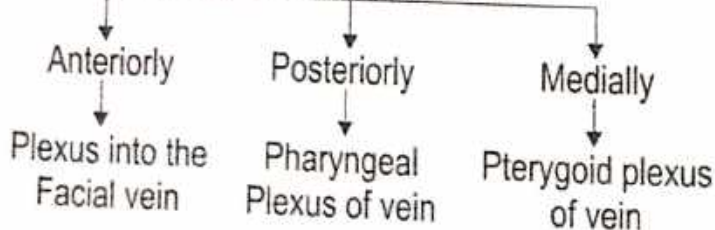
## Arterial Supply



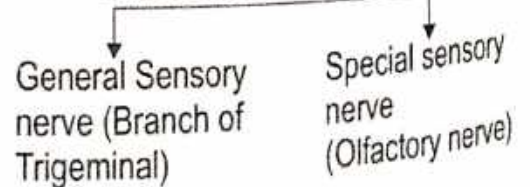
## ● ARTERIAL SUPPLY

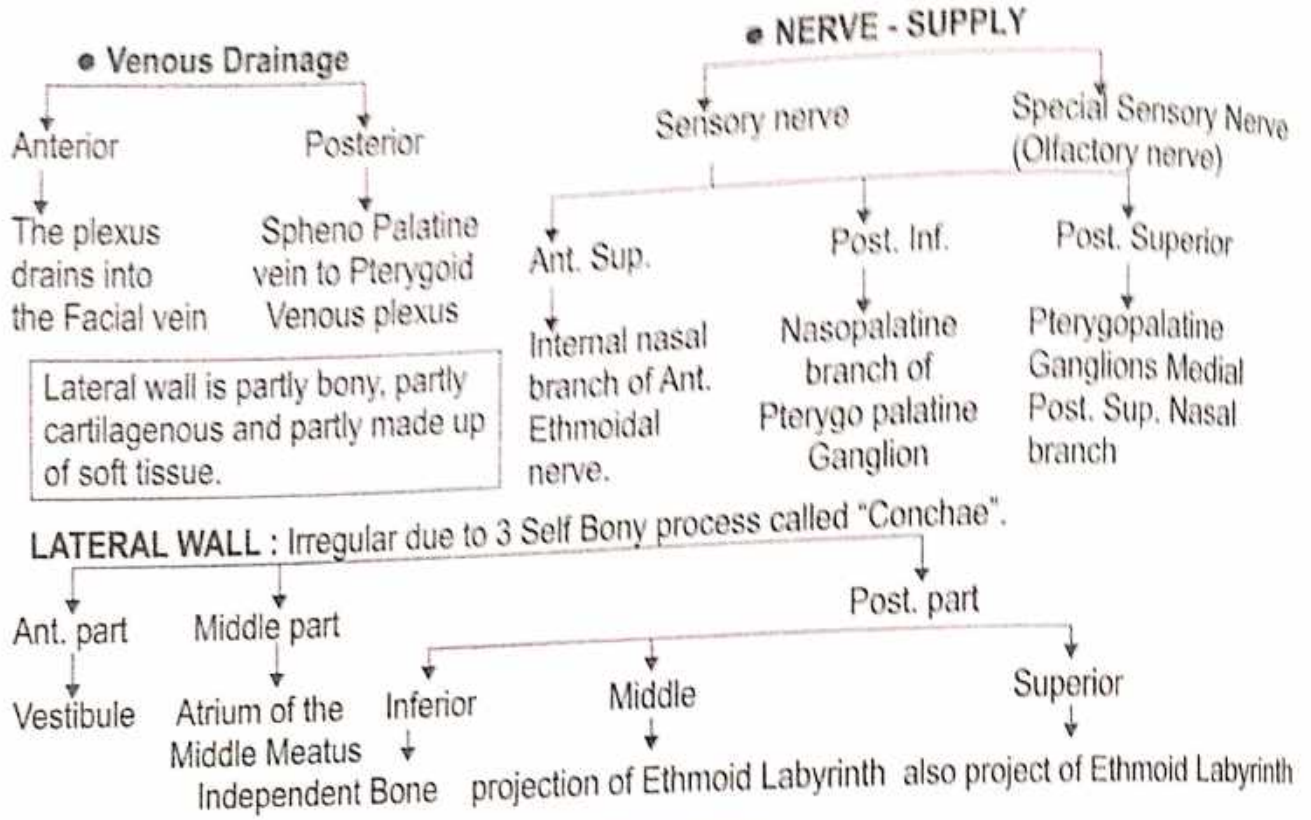


## ● VENOUS DRAINAGAE



## ● NERVE SUPPLY





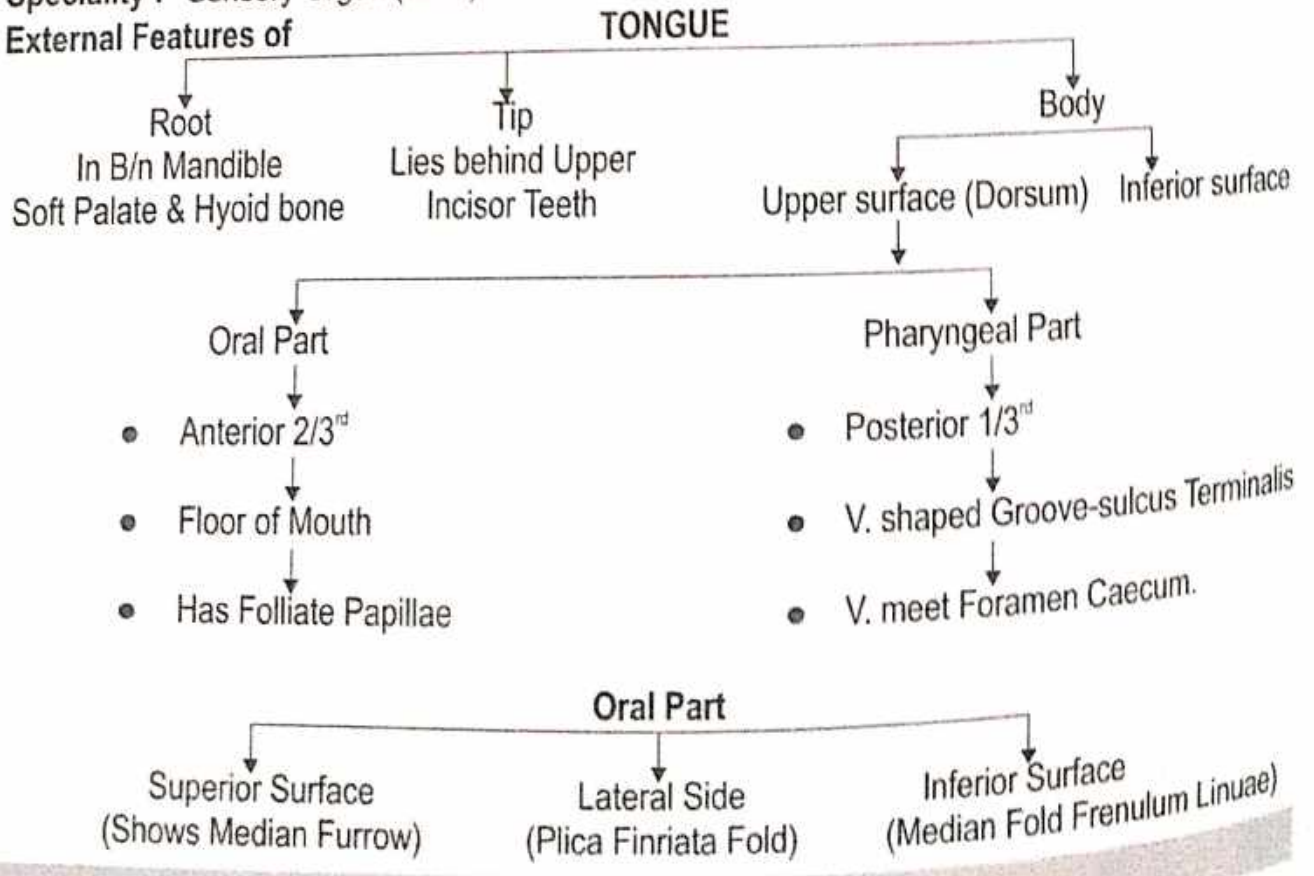
**TONGUE**

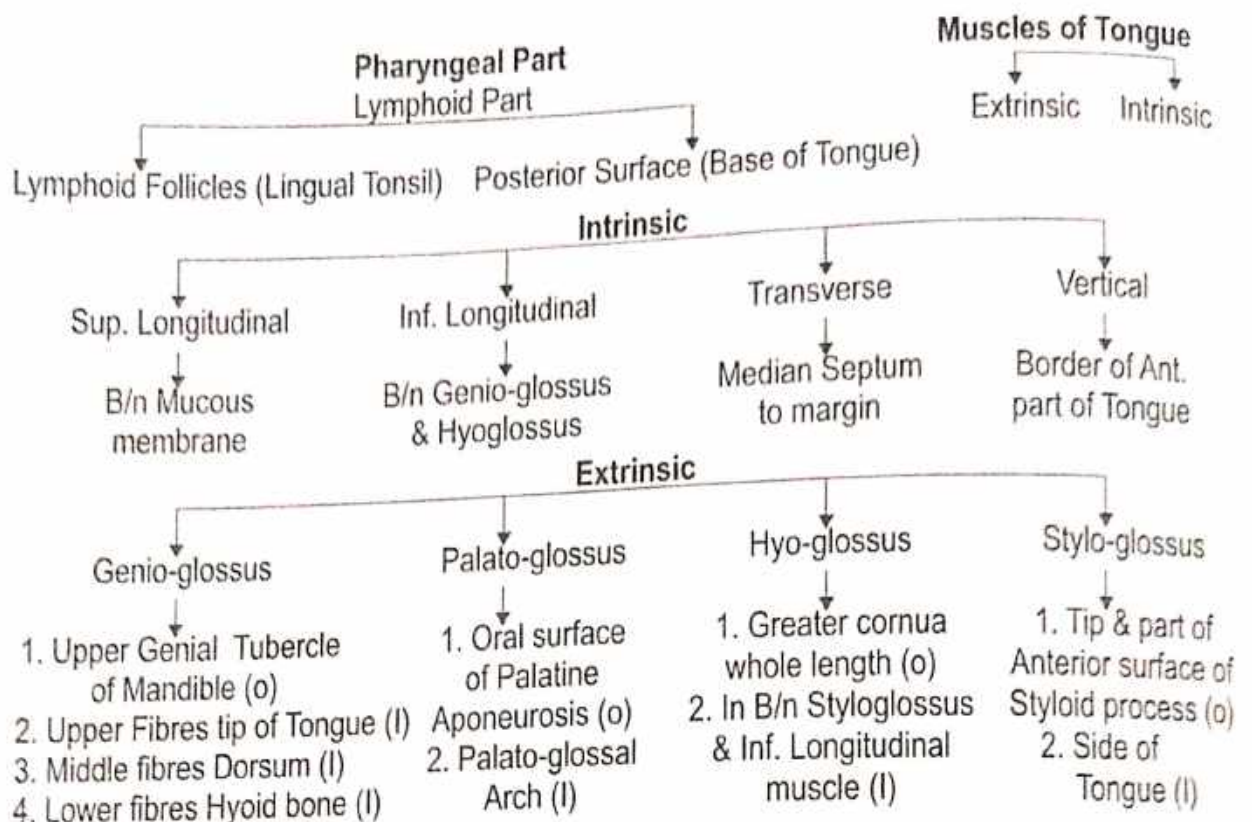
Name of Organ - ● According to Ayurveda - जिह्वा  
 ● रसनस्यापः (सु.शा. 1/6) ● जिह्वा वागिन्द्रियम् (च.शा. 1/26)

Situation : In the floor of Mouth with Mandibular Curve in between

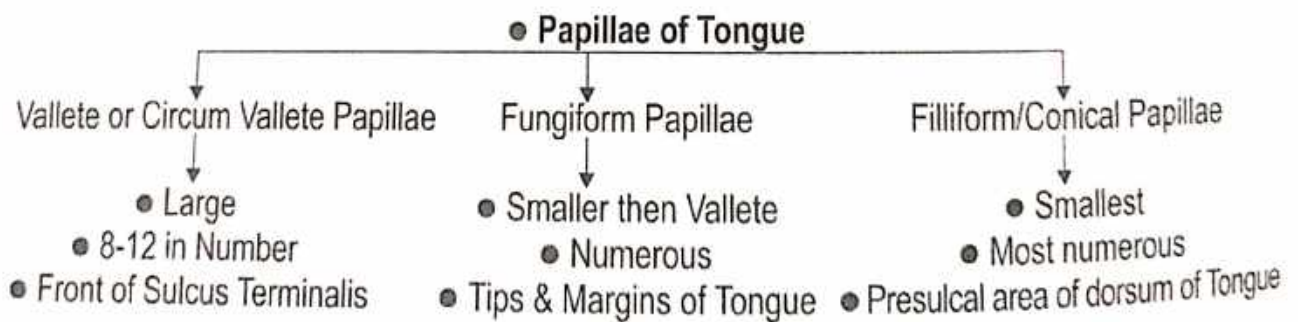
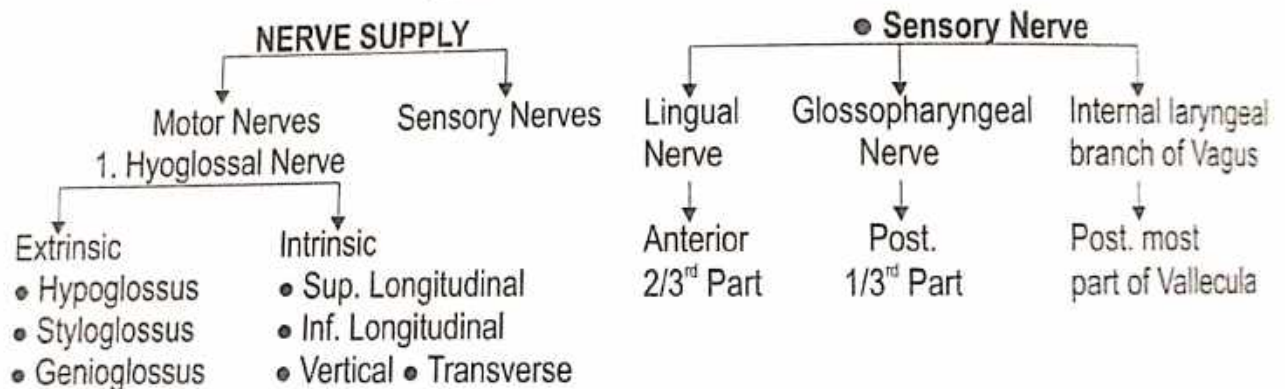
Origin : ● "कफ शोणित मांसानां सारो जिह्वा प्रजायते ।" (सु.शा. 4/27) (Endoderm)

Speciality : Sensory Organ (taste) रसनेन्द्रिय (स्वाद)

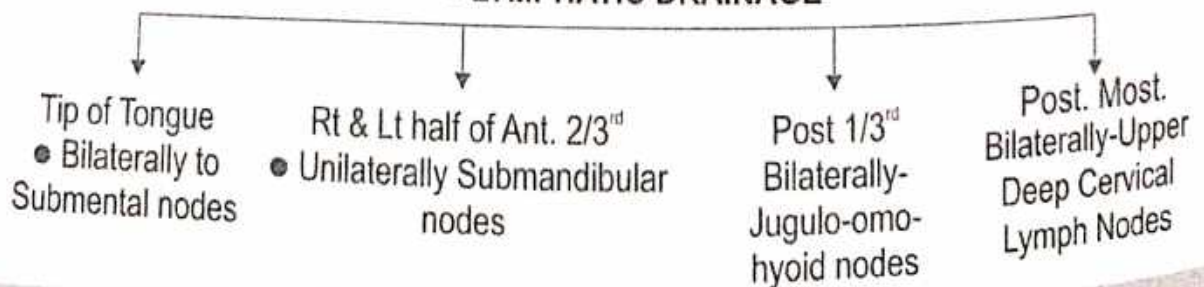




● **ARTERIAL SUPPLY** - Lingual Artery



● **LYMPHATIC DRAINAGE**



## SKIN

**Name :** ● According to Ayurveda - त्वक् "स्थिरा बहला त्वक्"

(च.शा. 8/51)

**Origin :** ● According to Ayurveda

● "तस्य खल्वेवं प्रवृत्तस्य शुक्रशोणितस्या भिपच्यमानस्य क्षीरस्येव सन्तानिकाः सप्त त्वचो भवन्ति ।" (सु.शा. 4/3)

**उत्पत्ति -** मांसाद्रसा त्वचः षट् च ।

(च.चि. 145/17)

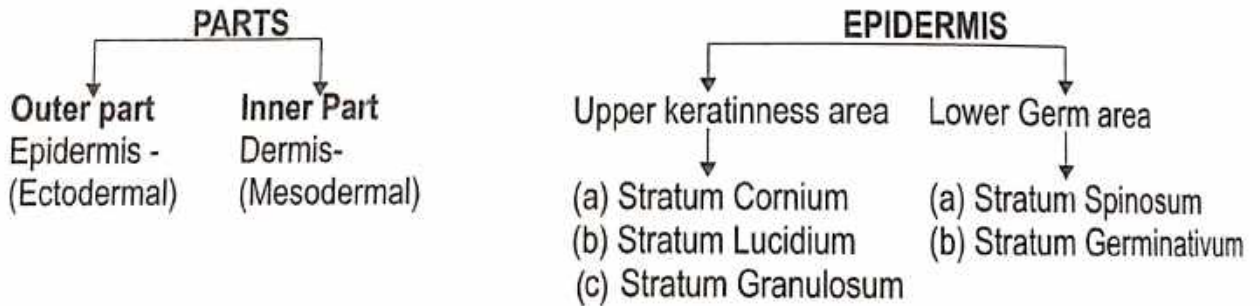
**त्वचा के प्रकार -**

| आचार्य चरक (6 प्रकार) (च.शा. 7/4)   | आचार्य सुश्रुत (7 प्रकार) (सु.शा. 4/3)   |
|---|--|
| <ol style="list-style-type: none"> <li>1. उदकधरा त्वग्वाह्या ।</li> <li>2. द्वितीया त्वगसुग्धरा ।</li> <li>3. तृतीय सिध्मकिलाससंभवाधिष्ठाना ।</li> <li>4. चतुर्थी दद्रुकुष्ठसंभवाधिष्ठाना ।</li> <li>5. पंचमी त्वलजीविद्रधिसंभवाधिष्ठाना ।</li> <li>6. षष्ठी तु यस्यांछिन्नायां ताम्यत्यन्ध इव च तमः प्रविशति यां चात्यधिष्ठायारूपि जायन्ते, पर्वसु कृष्णरक्तानि स्थूल मूलानि दुश्चिकित्स्यतमानि च ।</li> </ol> | <ol style="list-style-type: none"> <li>1. तासां प्रथमाऽवभासिनी नाम, या सर्ववर्णानवभासयति पंचविधां च छायां प्रकाशयति, सा ब्रीहेरष्टादशभागप्रमाणा सिध्मपद्मकण्टकधिष्ठानाः ।</li> <li>2. द्वितीया लोहिता नाम ब्रीहिषोडशभागप्रमाणा, तिलकालकन्यच्छव्यङ्गाधिष्ठाना ।</li> <li>3. तृतीया श्वेता नाम, ब्रीहिद्वादशभागप्रमाणा, चर्मदलाजगल्लीमशकाधिष्ठाना ।</li> <li>4. चतुर्थी ताम्रा नाम ब्रीहेरष्टादशभागप्रमाणा, विविधकि लासकुष्ठाधिष्ठाना ।</li> <li>5. पंचमी वेदिनी नाम ब्रीहिपंचभागप्रमाणा, कुष्ठविसर्पाधिष्ठाना ।</li> <li>6. षष्ठी रोहिणी नाम ब्रीहिप्रमाणा ग्रन्थ्यपच्यार्बुदश्लीपदगलगण्डाधिष्ठाना ।</li> <li>7. सप्तमी मांसधरा नाम ब्रीहिद्वयप्रमाणा, भगन्दरविद्रध्यशोऽधिष्ठाना ।</li> </ol> |

**According to Modern -** Ectomesodermal origin.

**System of Organ :** Integumentary system. "Jack of Trades". ● **Function of skin :** Outer Covering of Body.

**Features :**



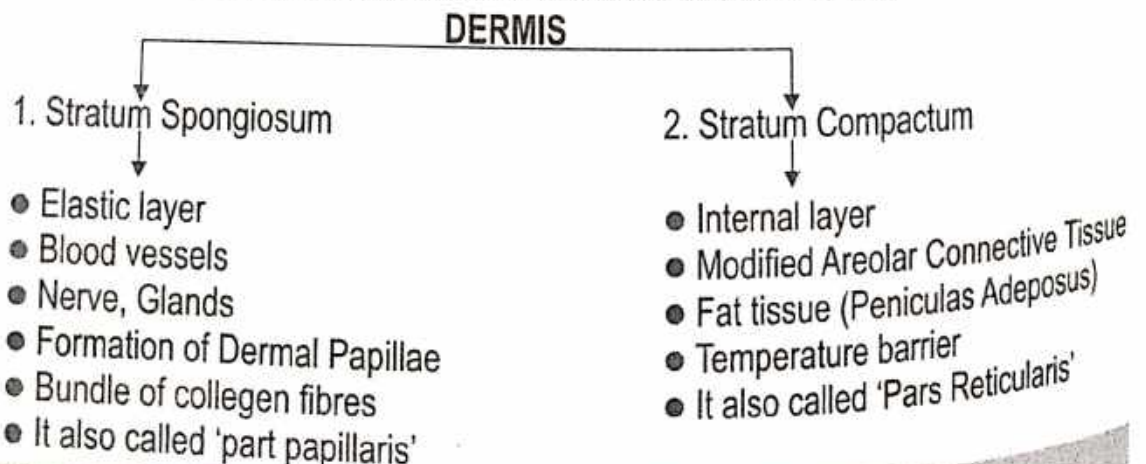
**Stratum Cornium -** ● Nucleus absent. ● Cytoplasm - Keratinness. ● Melanin Cells present.  
● Layer - 8 to 10 layer thicked.

**Stratum Lucidium -** ● Eleidin protein present. ● Transparent. ● 2-3 layer thickened.

**Stratum Granulosum -** ● Flat cells. ● Granuleness Cytoplasm. ● Keratohyaline Protein present.  
● 6-7 layer thickened.

**Stratum Spinosum -** ● Polygonal cells ● Called as prickle cell layer ● Transitional Layer ● 6-7 Layer thick

**Stratum Germinativum -** ● Coloumner cells ● Lived & divitionated part  
● Called as stratum Silendricum or Stratum Basale.





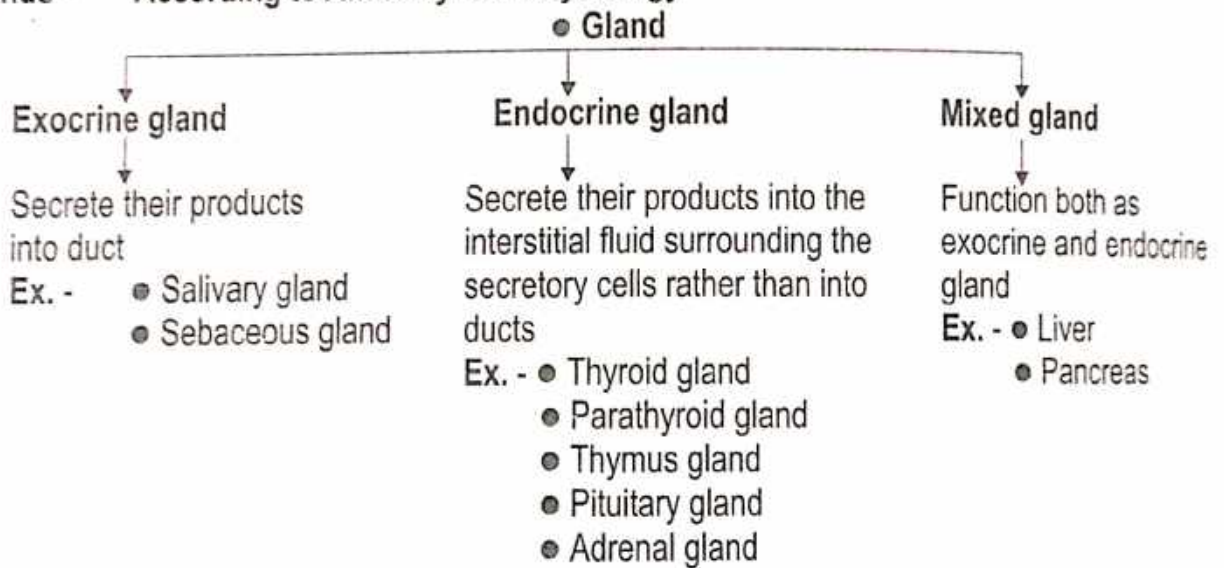
# ENDOCRINE SYSTEM

- The nervous and endocrine systems act together to coordinate function of all body system.

**Gland -** Anatomically a cell or group of cells or organ producing a secretion.

- Hormone -**
- A chemical substance produced in the body that controls and regulates the activity of certain or organ.
  - The endocrine system also controls body activities by releasing mediators, called hormones.
  - A hormone is a mediator molecule that is released in one part of the body but regulates the activity of cell in other parts of the body.

**Glands - According to Anatomy and Physiology -**



## • **Endocrine Glands**

### 1. Pituitary Gland or Hypophysis Cerebri

(पीयूषिका ग्रंथि)

**Introduction :** Pituitary gland called the “**Master of the endocrine orchestra**” because it produces a number of hormones which control the secretions of many other endocrine glands of the body.

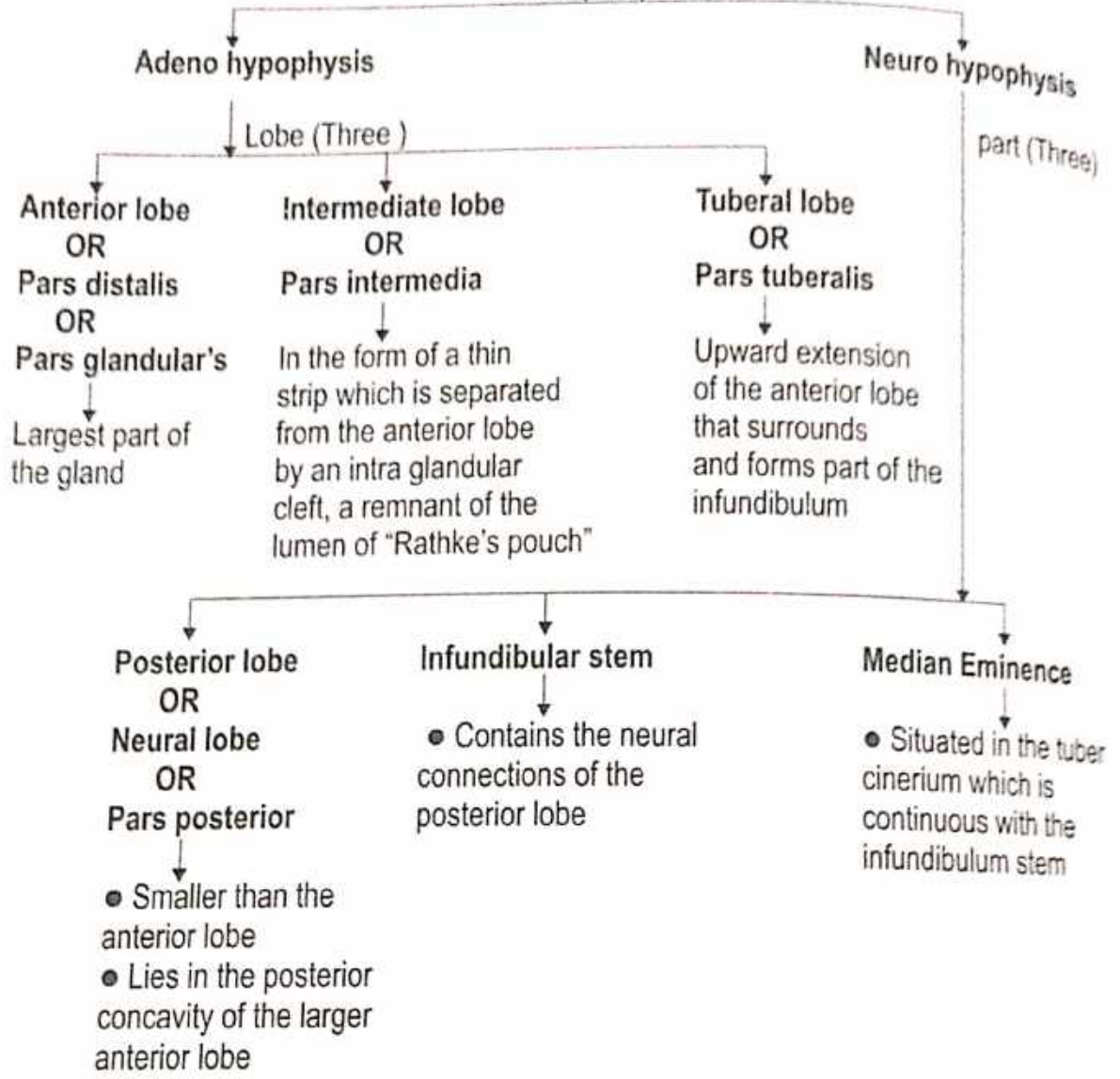
**Situation :** Situated in the hypophyseal fossa or sella turcica or pituitary fossa.

**Shape :** Oval

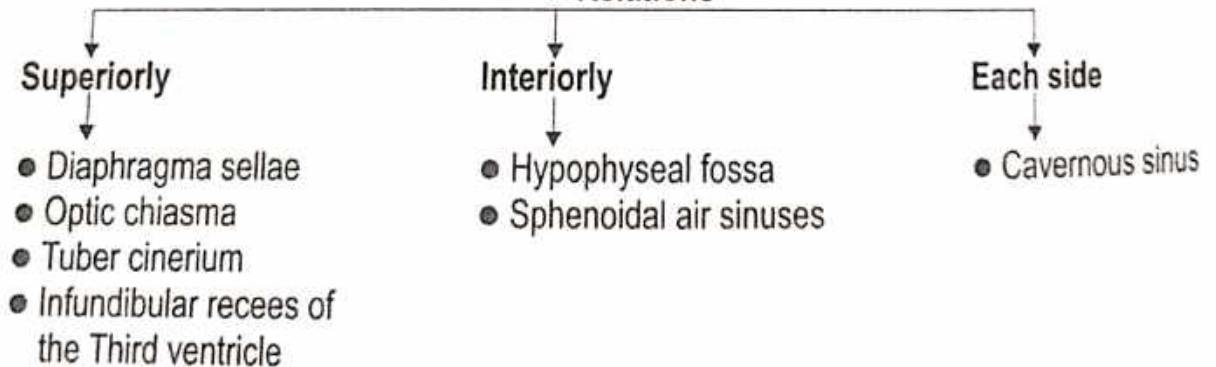
**Measurement :** • Antero posteriorly - 8 mm    • Transversely - 12 mm

**Weight :** 500 mg


● **Parts (Two)**



● **Relations**



● **Arterial Supply**

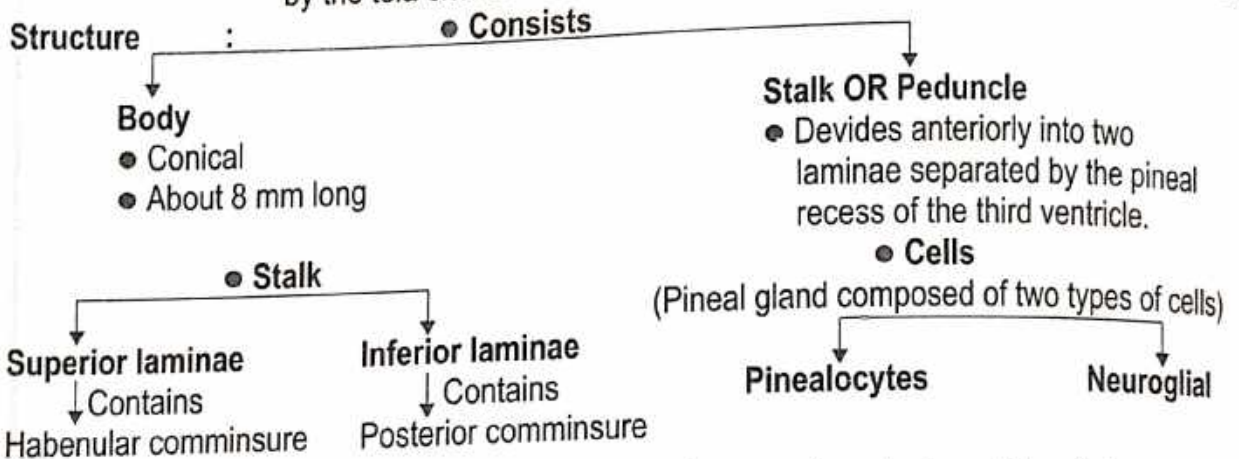


● **Venous Drainage**  
By short veins

## 2. Pineal Gland

**Introduction** : ● The Pineal gland is also known as the Pineal body, Conarium or epiphysis Cerebri.  
● It is a small endocrine gland.

**Situation** : ● The Pineal body is a small, conical organ, projecting backwards and downwards between the two Superior colliculi.  
● It is placed below the splenium of the corpus callosum, but separated from it by the tela choroidea of the third ventricle and the contained cerebral veins.



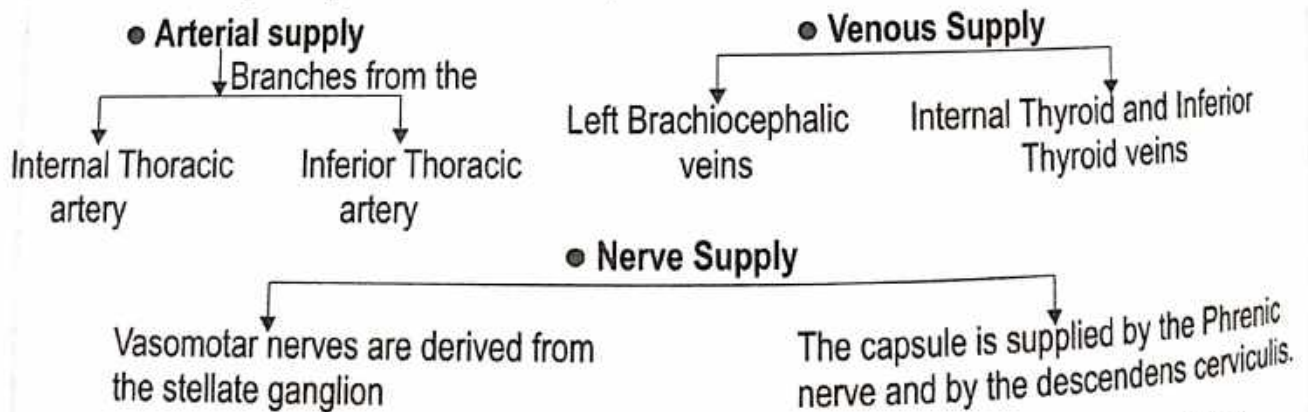
**Function** : ● It produces hormones that may have an important regulatory influence on many other endocrine organs.  
● The best known hormone is melatonin which causes changes in skin colour in same species.  
● The synthesis and discharge of melatonin is remarkably influenced by exposure of the animal to light.

## 3. Thymus Gland (बाल ग्रैवेयक ग्रंथि)

**Introduction** : The Thymus is an important lymphoid organ.

**Situation** : ● Anterior and superior mediastina of the thorax extending above into the lower part of the neck.  
● It is well developed at birth, continues to grow up to puberty and there after undergoes gradual atrophy and replacement by fat.

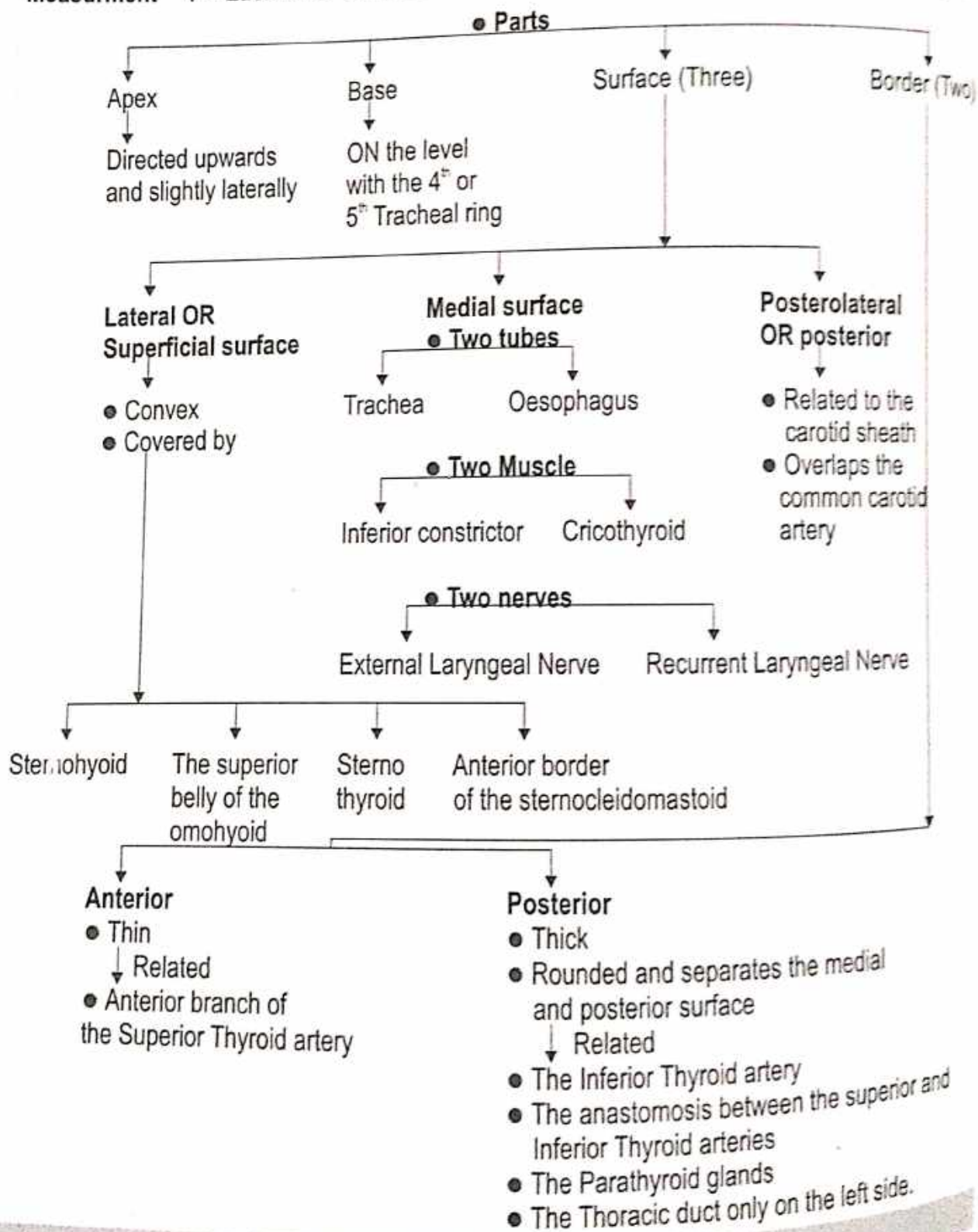
**Weight** : ● At birth - 10-15 gm ● At puberty - 30-40 gm ● After mid-adult life - 10 gm  
● After puberty, it becomes inconspicuous due to replacement by fat.

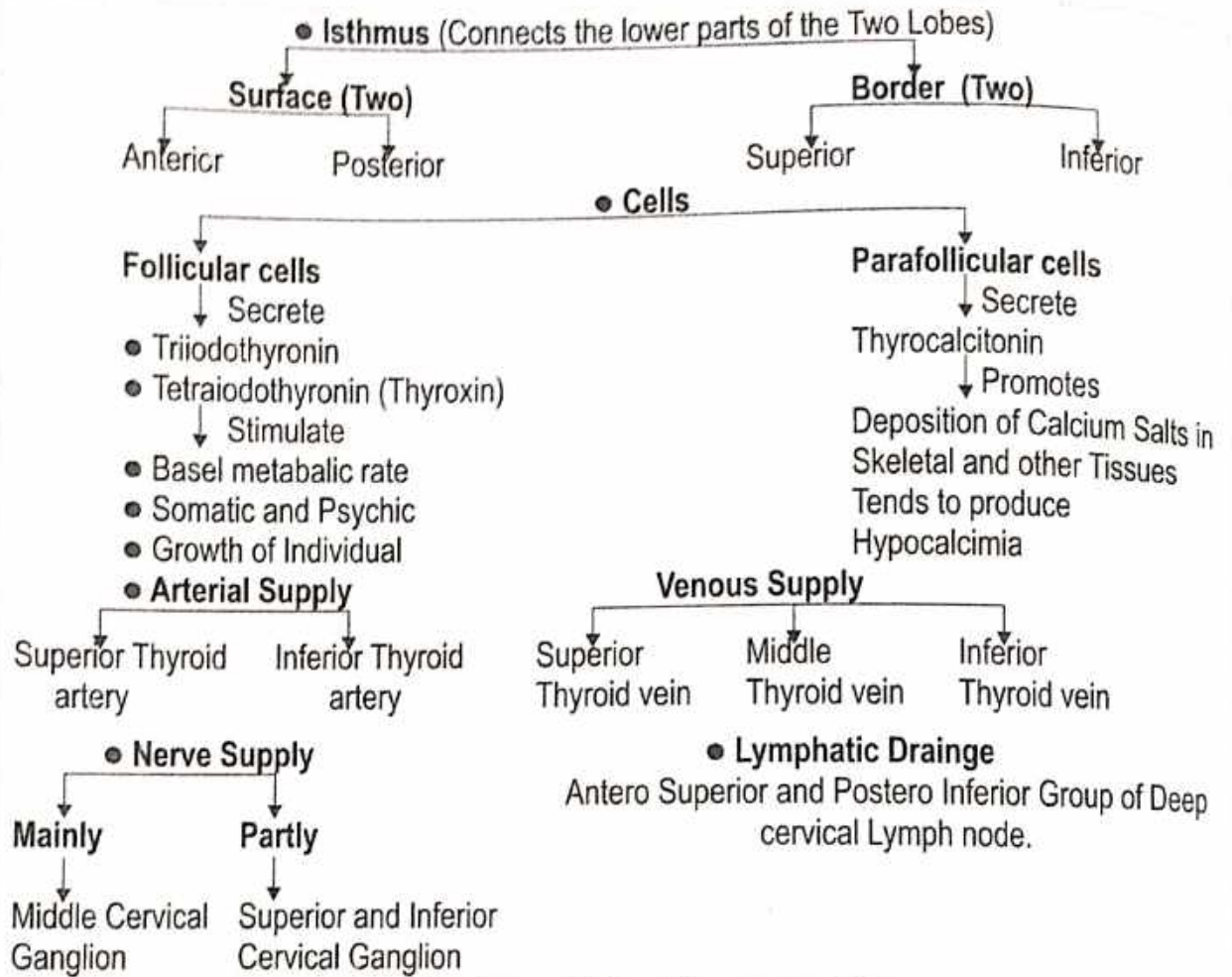


**Function** : ● Controls lymphopoiesis and maintains an effective pool of circulating lymphocytes competent to react to innumerable antigenic stimuli.  
● Control development of the peripheral lymphoid tissues of the body during the neonatal period. By puberty the main lymphoid are fully developed.

#### 4. Thyroid Gland (अवटुका ग्रंथि)

- Introduction :** • Thyroid is an endocrine gland, which regulates, the basal metabolic rate, stimulates somatic and psychic growth and plays an important role in calcium metabolism.
- Situation :** • The gland lies against vertebrae C<sub>5</sub>, C<sub>6</sub>, C<sub>7</sub> and T<sub>1</sub>, embracing the upper part of the Trachea.
- Shape :** "H" shape
- Measurement :** • Each lobe - 5 x 2.5 x 2.5 cm • Isthmus - 1.2 cm x 1.2 cm • Weight - 25 gm



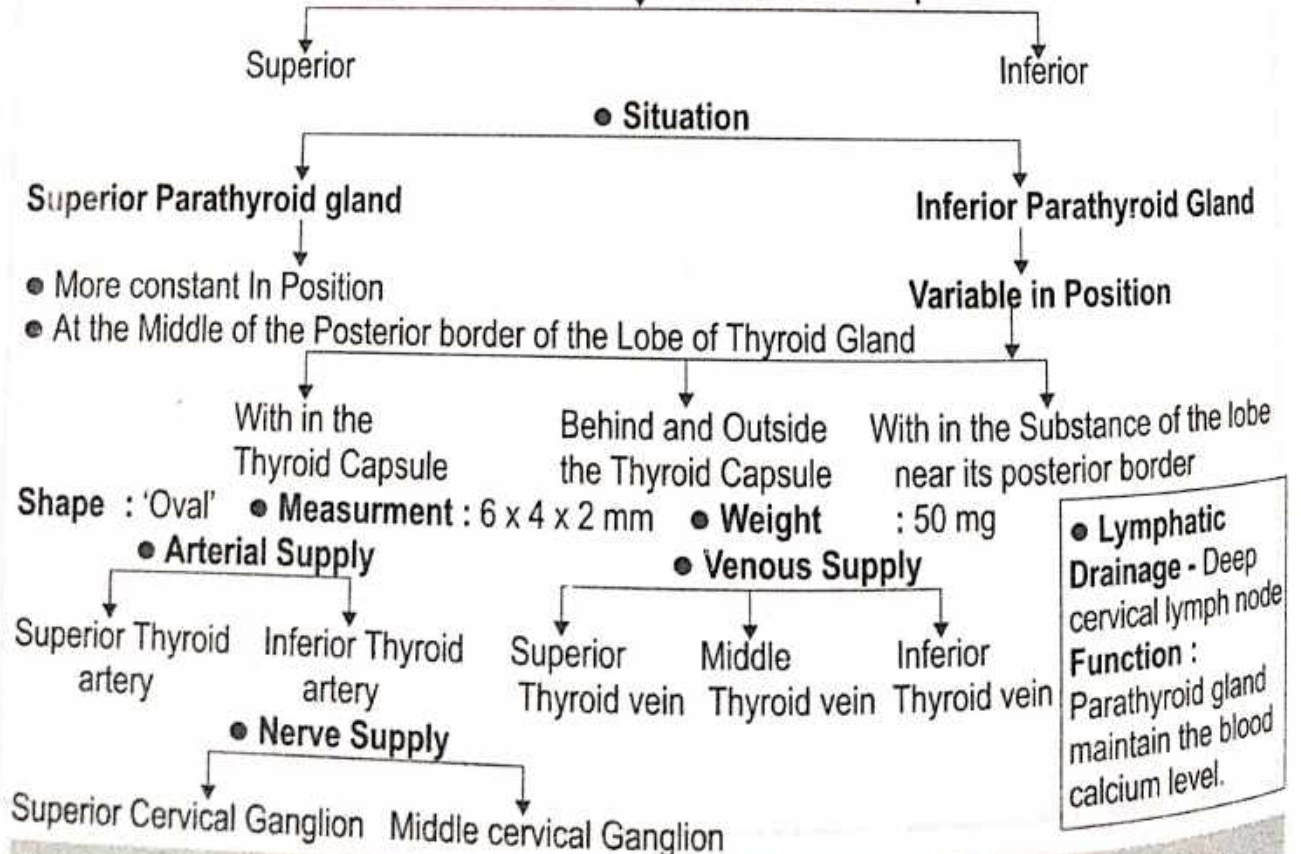


### 5. Parathyroid Gland (उप अवटुका ग्रंथि)

**Introduction :**


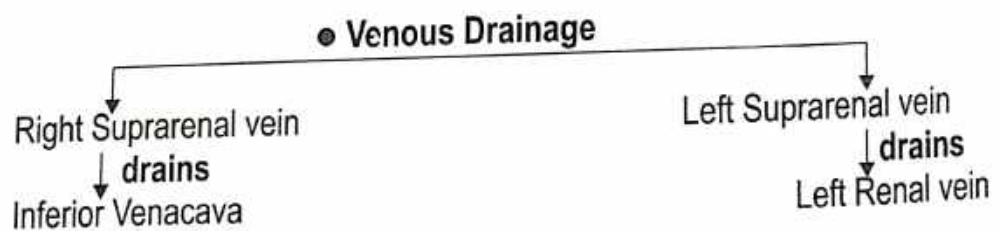
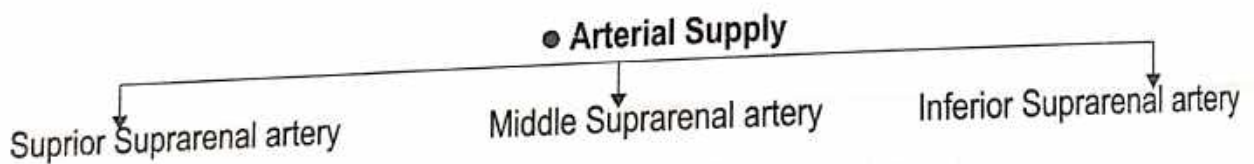
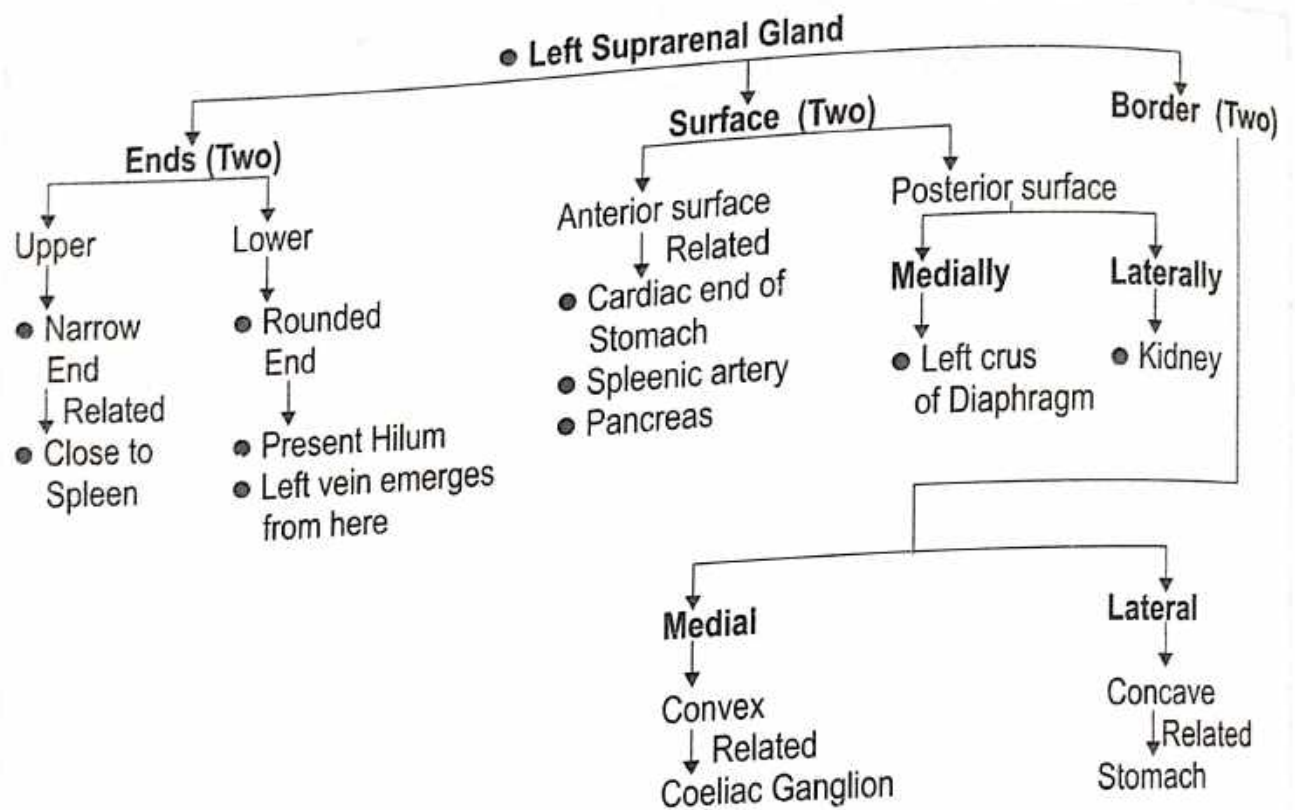
• It is a small Endocrine Glands

which have two parts



• **Lymphatic Drainage - Deep cervical lymph node**  
**Function :**  
 Parathyroid gland maintain the blood calcium level.





**• Lymphatic Drainage**

Lateral Aortic Nodes

MARMA ...  
(VITAL PARTS)  
(अहं शरीर)



# MARMA

## MARMA

मर्म की निरूपित -

“मारयन्तीति मर्माणि ।”

“अपि च मरणकारित्वान्मर्म।”

(डल्हण शा. 6/3)

मर्म की परिभाषा - मर्माणि नाम मांससिरास्नाय्वस्थिसन्धिसन्निपाताः,  
तेषु स्वभावत एव विशेषेण प्राणस्तिष्ठन्ति ।

(अ.स. 7/27)

मर्म के प्रकार -

(सु.शा. 6/21)

सप्तोत्तरं मर्मशतम् ।

तानि मर्माणि पञ्चात्मकानि भवन्ति, तद्यथा-  
मांसमर्माणि, सिरामर्माणि, स्नायुमर्माणि,  
अस्थिमर्माणि, संधिमर्माणि चेति न खलु  
मांससिरास्नाय्वस्थिसन्धिव्यतिरेकेणान्यानि  
मर्माणि भवन्ति, यस्मान्नोपलभ्यन्ते ॥

(सु.शा. 6/2)

षडंगो मर्मों की संख्या -

तेषामेकादशैकस्मिन् सक्थिन भवन्ति, ऐतेनेतरसक्थि बाहू च व्याख्यातौ,  
उदरोरसोद्वादश, चतुर्दश पृष्ठे, ग्रीवां प्रत्यूर्ध्वं सप्तत्रिंशत् ॥

(सु.शा. 6/4)

षडंगो के आधार पर मर्मों की संख्या -

- इन मर्मों में 11 मर्म पैर में होते हैं, इसी प्रकार दूसरा पैर व दो बाहुओं को भी समझना चाहिये अतः सब शाखाओं में 44 मर्म होते हैं ।
  - पेट और छाती में 12, पीठ में 14, अतः कोष्ठ में 26 मर्म होते हैं ।
  - ग्रीवाके ऊपर 37 मर्म होते हैं ।
- कुल मिलाकर -  $44+26+37=107$  मर्म ।

| क्र. | मर्म ( षडंग ) | मर्म का नाम  | मर्माघात परिणाम  |
|------|---------------|--|--|
| 1.   | पाद मर्म      | क्षिप्र<br>तलहृदय<br>कूर्च<br>कूर्चशिर<br>गुल्फ<br>इंद्रवस्ति<br>जानु<br>आणि<br>ऊर्वा<br>लोहिताक्ष<br>विटप | - आक्षेप से मृत्यु<br>- वेदनाओ से मृत्यु<br>- पांव में टेढ़ापन एवं कंपन<br>- पीड़ा और सूजन<br>- पीड़ा, पांव में जकड़न अथवा लंगड़ापन<br>- रक्तक्षय से मृत्यु<br>- लंगड़ापन<br>- जकड़न और सुन्नता, सूजन<br>- रक्तक्षय से सक्थि शोष<br>- रक्तक्षय से पक्षाघात अथवा सक्थि कृशता<br>- षण्ढता या अल्पशुक्रता |

| क्र. | मर्म           | -  | मर्माघात परिणाम   |
|------|----------------|--|---|
| 2.   | बाहु मर्म      | मणिबंध<br>कूर्पर<br>कक्षधर   | - वैकल्य (कलाई की शक्ति नष्ट होना)<br>- अग्रबाहु का लूलापन<br>- पक्षाघात  |
| 3.   | उदर मर्म       | गुद<br>वस्ति<br>नाभि   | - तत्काल मृत्यु<br>- तत्काल मृत्यु<br>- तत्काल मृत्यु   |
| 4.   | छाती के मर्म   | हृदय<br>स्तनमूल<br>स्तनरोहित<br>अपलाप<br>अपस्तंभ   | - तत्काल मृत्यु<br>- कोष्ठ कफ से भरकर कास श्वास से मृत्यु<br>- कोष्ठ रक्त से भरकर कास श्वास से मृत्यु<br>- रक्त के पूयभाव प्राप्त होने से मृत्यु<br>- कोष्ठ वायु से भरकर कास श्वास से मृत्यु  |
| 5.   | पीठ के मर्म    | कटीकतरूण<br>कुकुन्दर<br>नितम्ब<br>पार्श्वसंधि<br>बृहती<br>अंसफलक<br>अंस                    | - रक्तक्षय से पाण्डु, विवर्ण, क्षीण देह से मृत्यु<br>- शरीर के अधोभाग में सुन्नता और चेष्टानाश<br>- शरीर के अधोभाग का सूखना व कमजोरी से मृत्यु<br>- कोष्ठ रक्त से भर जाने से मृत्यु<br>- रक्तक्षय से उत्पन्न उपद्रवो से मृत्यु<br>- बाहुओ का शोष (कृशता) व सुन्नता<br>- बाहुओ की स्तब्धता |
| 6.   | ग्रीवा के मर्म | नीला व मन्या<br>मातृका<br>कृकाटिका   | - गूगांपन, स्वर में विकृति, रस ज्ञान का अभाव (जिह्वा में)<br>- तत्काल मृत्यु<br>- सिर हिलता है  |
| 7.   | शिर के मर्म    | विधुर<br>फण<br>अपांग<br>आवर्त<br>शंख<br>उत्क्षेप<br>स्थपनी<br>श्रृंगाटक<br>अधिपति<br>सीमंत | - बधिरता<br>- गंध ज्ञान नष्ट<br>- अंधापन अथवा दृष्टि क्षीणता<br>- अंधापन अथवा दृष्टि क्षीणता<br>- तत्काल मृत्यु<br>- शल्य चुभते ही शल्य निकालने से नहीं बचता (सशल्य जीवित)<br>- उत्क्षेपवत्<br>- तत्काल मृत्यु<br>- तत्काल मृत्यु<br>- उन्माद, भय, चित्तनाश, मरण                          |

सक्थिगत मर्मों के नाम (अधोशाखा) - [तत्र सक्थिमर्माणि क्षिप्र तलहृदय कूर्च कूर्चसिरो गुल्फेन्द्रवस्तिजान्वाण्यूर्वी-  
लोहिताक्षाणि विटपं चेति, एतेनेतरत्सक्थि व्याख्यातम् । (सु.शा. 6/5)]

| क्र. | मर्म नाम एवं संख्या | स्थिति                | रचना प्रकार | परिणाम अनुसार        | परिमाण    | पंच भौतिक संगठन | मर्माघात परिणाम                 | आधुनिक मतानुसार संभावित रचना |
|------|---------------------|-----------------------|-------------|----------------------|-----------|-----------------|---------------------------------|------------------------------|
| 1    | क्षिप्र 2           | सक्थि                 | स्नायु मर्म | कालांतर प्राणहर मर्म | अर्धांगुल | सौम्य आग्नेय    | आक्षेप से मृत्यु                | First metatarsal ligament    |
| 2    | तलहृदय 2            | सक्थि                 | मांस मर्म   | कालांतर प्राणहर      | अर्धांगुल | सौम्य आग्नेय    | वेदनाओं से मृत्यु               | Long planter ligament        |
| 3    | कूर्च 2             | सक्थि                 | स्नायु मर्म | वैकल्यकर             | अर्धांगुल | सौम्य           | टेढ़ापन                         | Tarsometatarsal ligament     |
| 4    | कूर्चशिर 2          | सक्थि                 | स्नायु मर्म | रूजाकर               | 1 अंगुल   | अग्नि व वायु    | पीड़ा और सूजन                   | Lat. ligament of ankle joint |
| 5    | गुल्फ 2             | सक्थि                 | संधि मर्म   | रूजाकर               | 2 अंगुल   | अग्नि व वायु    | पीड़ा, पांव में जकड़न, लंगड़ापन | Ankle joint                  |
| 6    | इंद्रवस्ति 2        | सक्थि                 | मांस मर्म   | कालान्तर             | अर्धांगुल | सौम्य आग्नेय    | रक्त क्षय से मृत्यु             | Calf muscles                 |
| 7    | जानु 2              | जानुसंधि              | संधि मर्म   | वैकल्यकर             | त्रिअंगुल | सौम्य           | लंगड़ापन                        | Knee joint                   |
| 8    | आणि 2               | जानुसंधि              | स्नायु मर्म | वैकल्यकर             | अर्धांगुल | सौम्य           | शोथ                             | Tendon of quadriceps femoris |
| 9    | ऊर्वी 2             | उरू के मध्य           | सिरा मर्म   | वैकल्यकर             | 1 अंगुल   | सौम्य           | रक्तक्षय से सक्थि शोष           | Femoral vessels              |
| 10   | लोहिताक्ष 2         | ऊर्वी से 2 अंगुल ऊपर  | सिरा        | वैकल्यकर             | अर्धांगुल | सौम्य           | रक्तक्षय से पक्षाघात            | Femoral vessels              |
| 11   | विटप 2              | वंक्षण व वृषण के मध्य | स्नायु      | वैकल्यकर             | 1 अंगुल   | सौम्य           | षण्ढता या अल्पशुकता             | Inguinal canal               |

अंतराधिगत मर्मों के नाम (उदर व वक्ष में स्थित) — उदरोरसोस्तु गुदवस्तिनाभिहृदयस्तनमूलस्तनरोहितापलापान्यपस्तम्भौ चेति । (सु.शा. 6/6)

| क्र. | मर्म नाम संख्या | स्थिति      | रचना प्रकार | परिणाम अनुसार   | परिमाण    | पंच भौतिक संगठन | मर्माघात परिणाम                      | आधुनिक मतानुसार संभावित रचना          |
|------|-----------------|-------------|-------------|-----------------|-----------|-----------------|--------------------------------------|---------------------------------------|
| 1    | गुद 1           | उदर (कोष्ठ) | मांस        | सद्यः प्राणहर   | मुष्टि    | अग्नि           | तत्काल मृत्यु                        | Anal canal & anus                     |
| 2    | वस्ति 1         | उदर         | स्नायु      | सद्यः प्राणहर   | मुष्टि    | अग्नि           | तत्काल मृत्यु                        | Urinary bladder                       |
| 3    | नाभि 1          | उदर         | सिरा        | सद्यः प्राणहर   | मुष्टि    | अग्नि           | तत्काल मृत्यु                        | Umbilicus                             |
| 4    | हृदय 1          | वक्ष        | सिरा        | सद्यः प्राणहर   | मुष्टि    | अग्नि           | तत्काल मृत्यु                        | Heart                                 |
| 5    | स्तनमूल 2       | वक्ष        | सिरा        | कालांतर प्राणहर | दो अंगुली | सौम्य + अग्नि   | कफपूर्ण कोष्ठता-कासस्वास से मृत्यु   | Internal mammary vessel               |
| 6    | स्तनरोहित 2     | वक्ष        | मांस        | कालांतर प्राणहर | अर्धांगुल | सौम्य + अग्नि   | रक्तपूर्ण कोष्ठता-कासस्वास से मृत्यु | Lower portion of pectoralis major     |
| 7    | अपलाप 2         | वक्ष        | सिरा        | कालांतर प्राणहर | अर्धांगुल | सौम्य + अग्नि   | रक्त का पूयभाव होकर मृत्यु           | Lateral thoracic & subscapular vessel |
| 8    | अपस्तंभ 2       | वक्ष        | सिरा        | कालांतर प्राणहर | अर्धांगुल | सौम्य + अग्नि   | वात पूर्ण कोष्ठता-कासस्वास से मृत्यु | Two bronchii                          |

पीठ के मर्म - "पृष्ठमर्माणि तु कटीकतरुणकुकुन्दरनितम्बपार्श्वसंधिवृहत्सफलकान्यंसी चेति ।" (सु.शा. 6/6)

| क्र. | मर्म नाम एवं संख्या | स्थिति | रचना प्रकार | परिणाम अनुसार   | परिमाण    | पंच भौतिक संगठन | मर्माघात परिणाम                         | आधुनिक मतानुसार संभावित रचना        |
|------|---------------------|--------|-------------|-----------------|-----------|-----------------|---|-------------------------------------|
| 1    | कटीक-तरुण 2         | पृष्ठ  | अस्थि       | कालांतर प्राणहर | अर्धांगुल | सौम्य+आग्नेय    | रक्तक्षय से पाण्डु, क्षीण देह से मृत्यु | Sciatic notch                       |
| 2    | कुकुन्दर 2          | पृष्ठ  | संधि        | वैकल्यकर        | अर्धांगुल | सौम्य           | सुन्नता, चेष्टानाश                      | Ishchial Tuberosity                 |
| 3    | नितम्ब              | पृष्ठ  | अस्थि       | कालांतर         | अर्धांगुल | सौम्य+अग्नि     | शोष, कमजोरी से मृत्यु                   | Ileum                               |
| 4    | पार्श्व-संधि 2      | पृष्ठ  | सिरा        | कालांतर         | अर्धांगुल | सौम्य+अग्नि     | कोष्ठ रक्त से भर जाने से मृत्यु         | Common Iliac vessels                |
| 5    | बृहती 2             | पृष्ठ  | सिरा        | कालांतर         | अर्धांगुल | सौम्य+अग्नि     | रक्तक्षय से उत्पन्न उपद्रवो से मृत्यु   | Subscapular artery                  |
| 6    | अंस फलक 2           | पृष्ठ  | अस्थि       | वैकल्यकर        | अर्धांगुल | सौम्य           | बाहुशोष कृशता, सुन्नता                  | Spine of the scapula                |
| 7    | अंस मर्म 2          | पृष्ठ  | स्नायु      | वैकल्यकर        | अर्धांगुल | सौम्य           | बाहु की स्तब्धता                        | Coracohumeral Glenohumeral Ligament |

ऊर्ध्वशाखागत मर्मों के नाम - "बाहुमर्माणि तु क्षिप्रतलहृदयकूर्चकूर्चशिरोमणिबंधेन्द्रबस्तिकूर्परण्यूर्वी-लोहिताक्षाणिकक्षधरं चेति । ऐतेनेतरो बाहुव्याख्यातः ।" (सु.शा. 6/7)

| क्र. | मर्म नाम एवं संख्या | स्थिति | रचना प्रकार | परिणाम अनुसार | परिमाण    | पंच भौतिक संगठन | मर्माघात परिणाम                    | आधुनिक मतानुसार संभावित रचना    |
|------|---------------------|--------|-------------|---------------|-----------|-----------------|------------------------------------|---------------------------------|
| 1    | क्षिप्र 2           | बाहु   | स्नायु      | कालांतर       | अर्धांगुल | सौम्य+अग्नि     | आक्षेप से मृत्यु                   | First intermeta-Carpal ligament |
| 2    | तलहृदय 2            | बाहु   | मांस        | कालांतर       | अर्धांगुल | सौम्य+अग्नि     | वेदनाओ से मृत्यु                   | Palmer aponeurosis              |
| 3    | कूर्च 2             | बाहु   | स्नायु      | वैकल्यकर      | मुष्टि    | सौम्य           | हाथ में टेढ़ापन कंपन               | Carpometacarpal ligament        |
| 4    | कूर्चशिर 2          | बाहु   | स्नायु      | रूजाकर        | 1 अंगुल   | अग्नि + वायु    | पीड़ा और सूजन                      | Lat. ligament of wrist joint    |
| 5    | मणिबंध 2            | बाहु   | संधि        | रूजाकर        | 2 अंगुल   | अग्नि + वायु    | कलाई की शक्ति नष्ट होना            | Wrist joint                     |
| 6    | इंद्रबस्ति 2        | बाहु   | मांस        | कालांतर       | अर्धांगुल | अग्नि + वायु    | रक्तक्षय से मृत्यु                 | Cubital fossa                   |
| 7    | कूर्पर 2            | बाहु   | संधि        | वैकल्यकर      | 3 अंगुल   | सौम्य           | अग्रबाहु का लूलापन                 | Elbow joint                     |
| 8    | आणि 2               | बाहु   | स्नायु      | वैकल्यकर      | अर्धांगुल | सौम्य           | जकड़न और सुन्नता                   | Tendon of biceps                |
| 9    | उर्वी 2             | बाहु   | सिरा        | वैकल्यकर      | अर्धांगुल | सौम्य           | रक्तक्षय से सक्थि शोष              | Brachial artery                 |
| 10   | लोहिताक्ष 2         | बाहु   | सिरा        | वैकल्यकर      | अर्धांगुल | सौम्य           | रक्तक्षय से पक्षाघात (सक्थि कृशता) | Axillary Vessels                |
| 11   | कक्षधर 2            | बाहु   | स्नायु      | वैकल्यकर      | 1 अंगुल   | सौम्य           | पक्षाघात                           | Brachial plexus                 |

ऊर्ध्व जत्रुगत मर्म - "जत्रुण उर्ध्व मर्माणि चतस्रो धमन्योऽष्टौ मातृकाः द्वे कृकाटिके द्वे विधुरे द्वे फणे द्वावपाङ्गौ द्वावावर्तौ, द्वावुत्क्षेपौ द्वौ शंखावेका स्थपनी पंच सीमन्ताश्चत्वारि श्रृङ्गाटकान्येकोऽधिपतिरिति ।" (सु.शा. 6/8)

## ऊर्ध्व जत्रुगत मर्मों के नाम (शिर के मर्म)

| क्र. | मर्म नाम एवं संख्या | स्थिति | रचना प्रकार | परिणाम अनुसार | परिमाण    | पंच भौतिक संगठन | मर्माघात परिणाम           | आधुनिक मतानुसार संभावित रचना   |
|------|---------------------|--------|-------------|---------------|-----------|-----------------|---------------------------|--------------------------------|
| 1    | विधुर 2             | शिर    | स्नायु      | वैकल्यकर      | अर्धांगुल | सौम्य           | बधिरता                    | Post. auricular vessels        |
| 2    | फण 2                | शिर    | सिरा        | वैकल्यकर      | अर्धांगुल | सौम्य           | गंध का ज्ञान नष्ट         | Olfactory region of nose       |
| 3    | अपांग 2             | शिर    | सिरा        | वैकल्यकर      | अर्धांगुल | सौम्य           | अंधापन या दृष्टि क्षीणता  | Zygomaticotemporal vessels     |
| 4    | आवर्त 2             | शिर    | सिरा        | वैकल्यकर      | अर्धांगुल | सौम्य           | अंधापन या दृष्टि क्षीणता  | Junction of frontal & sphenoid |
| 5    | शंख 2               | शिर    | अस्थि       | सद्यः प्राणहर | अर्धांगुल | आग्नेय          | तत्काल मृत्यु             | Temple region                  |
| 6    | उत्क्षेप 2          | शिर    | स्नायु      | विशल्यघ्न     | अर्धांगुल | वायव्य          | सशल्य जीवित               | Temporal muscles & fascia      |
| 7    | स्थपनी 1            | शिर    | सिरा        | विशल्यघ्न     | अर्धांगुल | वायव्य          | सशल्य जीवित               | Nasal arch & frontal veins     |
| 8    | सीमंत 5             | शिर    | संधि        | कालान्तर      | हथेली     | सौम्य + अग्नि   | उन्माद, भय, चित्तनाश, मरण | Cranial sutures                |
| 9    | श्रृङ्गाटक 4        | शिर    | सिरा        | सद्यः प्राणहर | हथेली     | आग्नेय          | तत्काल मृत्यु             | Cavernous sinus                |
| 10   | अधिपति 1            | शिर    | संधि        | सद्यः प्राणहर | अर्धांगुल | आग्नेय          | तत्काल मृत्यु             | Obelion point                  |

## ऊर्ध्व जत्रुगत मर्मों के नाम (ग्रीवा के मर्म)

| क्र. | मर्म नाम एवं संख्या | स्थिति | रचना प्रकार | परिणाम अनुसार | परिमाण    | पंच भौतिक संगठन | मर्माघात परिणाम                                       | आधुनिक मतानुसार संभावित रचना |
|------|---------------------|--------|-------------|---------------|-----------|-----------------|---|------------------------------|
| 1    | नीला 2              | ग्रीवा | सिरा        | वैकल्यकर      | हथेली     | सौम्य           | गूंगापपन, स्वर में विकृति, जिह्वा में रसज्ञान का अभाव | Blood vessels of neck        |
| 2    | मन्या 2             | ग्रीवा | सिरा        | वैकल्यकर      | हथेली     | सौम्य           | — " —   | Blood vessels of neck        |
| 3    | मातृका 8            | ग्रीवा | सिरा        | सद्यः प्राणहर | हथेली     | आग्नेय          | तत्काल मृत्यु   | Blood vessels of neck        |
| 4    | कृकाटिका 2          | ग्रीवा | संधि        | वैकल्यकर      | अर्धांगुल | सौम्य           | सिर हिलना   | Atlanto - Occipital joint    |



रचना शारीर प्रायोगिक पुस्तक का विमोचन करते हुये उत्तरप्रदेश के महामहिम राज्यपाल श्री राम नाईक जी



Dr. Sushil Dwivedi is associated with Sri Narayan Prasad Awasthi Government Ayurvedic College, Raipur, Chhattisgarh as Associate Professor. Prior to that he rendered his services to Chaitanya Ayurved College, Sakegaon, Bhusawal.

A Post Graduate in MD (Ayurved) Rachna Sharir from Lucknow University and Ph.D (Ay) Sharir from Sampoomand Sanskrit University Varanasi. Dr. Dwivedi has contributed to research through his papers which has been published in journals of national repute. He has also guided more than 30 postgraduate scholars.



ASHWARY PUBLICATION

BHILAI

OUR OTHER PUBLICATION

ISBN 9788192449944



9 788192 449944